

VIII. *On the Structure and Development of the Skull of the Common Frog (Rana temporaria, L.).* By WILLIAM KITCHEN PARKER, F.R.S.

Received October 10, 1870,—Read January 19, 1871.

Introductory Remarks.

SINCE the sending in of my last communication, that on the Skull of the Fowl, our knowledge of the morphology of the facial arches has been very greatly extended by Professor HUXLEY'S invaluable paper "On the Representatives of the Malleus and the Incus of the Mammalia in the other Vertebrata" (see Proc. Zool. Soc. May 1869, pp. 391–407).

After comparing the components of the mandibular and hyoid arches in an extended series of vertebrate types, the author concludes his paper by saying (p. 406), "in the higher Amphibia changes of a most remarkable kind take place, of which I do not now propose to speak, as my friend Mr. PARKER is engaged in working out that part of the subject."

The most important result of Professor HUXLEY'S more recent researches into the subject is the rectification of a very obstructive error—namely, the supposition that the incus of the Mammal was the pier of the mandibular arch, thus making it the counterpart of the os quadratum of the Sauropsida.

The type which has been most instructive in this matter is that remarkable New-Zealand Lizard (*Hatteria*) the structure of which has been so well worked out and described by Dr. GÜNTHER (Phil. Trans. 1867, pp. 595–629), in which the stapes is continuous with the hyoid arch.

Taking this form as a practical stand-point, Professor HUXLEY has, after comparing its facial structures with those of the Crocodile and the Bird, proposed a nomenclature for the parts of the middle ear (largely formed by metamorphosis of the top of the hyoid arch), which should have the term "stapes" as a foundation.

We thus get the terms "suprastapedial," "infrastapedial," and the like, all very useful terms in the description of these modified parts of the facial arches in the Sauropsida.

Whilst my friend was working out this subject, it occurred to me to reexamine the condition of these parts in the tailless Amphibia; I soon saw enough to allure me on to an extended observation of these structures in the Frog; and the longer I worked the more I saw the necessity for doing what Professor HUXLEY strongly advised me, namely, extending my observations *backwards* and *downwards* into the condition of these parts in very minute embryos.

One thing soon appeared certain; and that was the absolute morphological distinction between the "stapes" or *ear-plug*, and the other bones or cartilages related to it physiologically as part of the middle ear. Nevertheless I see no reason for the non-adoption

of Professor HUXLEY'S nomenclature of these parts, if it be held in mind that the *prefixes* signify physiological relation and not morphological representation.

I make these remarks now because, when once fairly started, it will be necessary to keep clear of all other Vertebrate types: a comparison of the Frog with itself, in its marvellously varying morphology as its structure is traced from the egg to the adult form, will give us sufficient employment for the time.

My object in this paper being *special*, I shall describe what has been seen without reference either to the works of other anatomists, or to what I am familiar with in the structure of the skull in other types.

But as the Frog has received large attention from the best writers, it may be truly supposed that I am greatly indebted to their writings, the most important of which are the following, namely:—

I. ANT. DUGÈS. “Recherches sur l'Ostéologie et la Myologie des Batraciens à leurs différens âges.” Paris, 1834.

II. K. B. REICHERT. “Vergleichende Entwicklungsgeschichte des Kopfes der nackten Amphibien, nebst den Bildungsgesetzen des Wirbelthierkopfes im Allgemeinen und seinen hauptsächlichsten Variationen durch die einzelnen Wirbelthierklassen.” Königsb. 1838.

But in endeavouring to form a clear conception of the morphology of the skull in its simple condition, I am most of all indebted to JOH. MÜLLER'S magnificent work on the lower types of Fish, entitled “Vergleichende Anatomie der Myxinoiden, der Cyclostomen mit durchbohrtem Gaumen.” Berlin, 1835.

This work, Professor HUXLEY'S Croonian Lecture (Proc. Roy. Soc. Nov. 1858), and his ‘Elements of Comparative Anatomy,’ 1864, have been always open before me whilst engaged in this piece of research.

My observations on the structure of the skull in the Common Frog have, in several stages, been corroborated by what I have seen in *Rana boans* vel *pipiens*, *Pseudis paradoxa*, and *Bufo vulgaris*; these, however, will be described at some future time*.

Before commencing a description of the stages of the Frog, it is necessary to speak of the terms which will be made use of, both histological and morphological.

In my memoir on the Shoulder-girdle (Ray Soc. 1868, p. 4), the *varieties* of ossification are spoken of as “parostoses,” “ectostoses,” and “endostoses;” to these another variety might have been added, namely, “dermostoses.”

But the endosteal mode of ossification is further divisible into three kinds, namely, superficial, subcentral, and central endostosis.

These distinctions hold good in many cases, whilst in others they completely break down, and therefore they have only a limited and *varietal* value. For instance, the three divisions of the parasphenoid in the Bird, as I showed in my last paper, are true

* I have been greatly helped as to *materials* by Dr. MURIE, Professor W. H. FLOWER, F.R.S., Dr. GÜNTHER, F.R.S., and Dr. MICHAEL FOSTER; but the best help of all has been frequent discussion of the matter, in its gradual unveiling, with Professor HUXLEY.

“parostoses” for some days, being formed in a thick web of fibrous blastema; they soon, however, apply themselves to the overlying cartilage of the basis cranii, and become ectosteal in relation to it.

Again, there can be no better instance of an ectosteal sheath than the shaft-bone of a young Sea-turtle’s rib (“Shoulder-girdle and Sternum,” pl. 12. fig. 5); but in a short time the bony matter spreads into the surrounding fibrous tissue and into the overlying derm, affecting that tissue *outside* much faster than the cartilage within (ibid. fig. 6). RATHKE had shown this long before, in his work ‘Ueber die Entwicklung der Schildkröten,’ 1848.

In this case that which is primarily a true ectostosis becomes parosteal during development, and then spreads into the substance of the skin, forming a dermosteal layer.

That which is remarkable in the “Anura” is the paucity of bony plates as compared with Osseous Fishes and Reptiles, and also the long time that the ossification of the fibrous bony layer keeps independent of the *calcification* which takes place somewhat later in the superficial cells of the hyaline cartilage within; this latter is “superficial endostosis,” as in the Sharks and Rays*.

Here, in the Amphibia, both tailed and tailless, there is no original distinction to be seen between a parostosis and an ectostosis, and therefore the question as to whether the fibrous bones are ectoskeletal or endoskeletal has to be determined arbitrarily, by comparison with their counterparts in Osseous Fishes and in the abbranchiate Vertebrata.

That this distinction is merely arbitrary, as far as fibrous bones are concerned, is evident from what I shall have to describe in this paper; for in the Frog the *dentary*, which is nearly always a reliable parostosis in the other great groups, forms here an ectosteal sheath to MECKEL’s cartilage; whilst the *articulare*, which everywhere else bears an ectosteal relation to the upper part of that rod, is in the Frog a mere splint applied to its surface. In the early condition of the *larvæ* of the “Amphibia Urodela,” the bony plates which appear in the palatal region are all similar films of bony deposit in delicate tracts of fibrous blastema; and so far there is no distinction as to exoskeleton and endoskeleton between the parasphenoid and vomers on the one hand, and the palatopterygoid plates on the other.

In my mode of illustration, however, I shall continue to colour those bony plates *yellow* which, as a rule, are the immediate setters-up of ossification in the cartilaginous endoskeleton; and the plates which normally keep free from the cartilage will be left uncoloured, as though they were truly exoskeletal; they are, indeed, the connecting bond between the two systems.

Structure of the Frog’s Skull, First Stage.—Embryos from 2 to 3 lines long; extending in time from 2 days before to 2 days after hatching.

It will be necessary to describe both external and internal characters in their early stage;

* See ROLLETT’s paper (p. 114) in STRICKER’s ‘Human and Comparative Histology,’ translated for the New Sydenham Society, by H. POWER, 1870.

for the cutaneous system, now complete over both embryo and yelk-sac, is just ready to undergo very remarkable changes, becoming highly modified over the sense-organs, and undergoing dehiscence in the facial walls.

At present, in embryos two lines long, still in the jelly-ball, the cutaneous system has only one opening, namely, the oral (Plate III. fig. 1, *m.*).

Elevations and hollows there are, however, in abundance, which will show their own meaning afterwards, when dehiscence takes place, or even now, when they indicate the form of already developed organs or parts within. A front view of the skull and face of the unhatched frog-embryo (two lines long) is very instructive (see Plate III. fig. 1, $\times 20$).

In the centre is the small lozenge-shaped oral opening (*m.*), above this the "fronto-nasal process" (*f.n.*), ending below in a right and left horn; this median, bilobate region forms the inner half of the boundary of each of the rudimentary olfactory sacs (*ol.*).

Below the oral opening we have the right and left cheeks or facial walls, *swollen* in this early stage; for the fore part of the "yelk-chasm" is permanent, and enlarges to form the pharyngo-stomal cavity, which is already lined by a layer of cells, derived, according to REICHERT, from the lower part of the "cumulus germinativus;" this layer becomes the mucous membrane of this region, and passes, some way within the oral opening, into the cutaneous system. The two sides of the face are separated anteriorly by a deep fossa; below they terminate in those thick reduplications of the cutaneous system which are called the "claspers" (*cp.*).

On each side of the fronto-nasal region (*f.n.*) there is a reniform depression covered by a thinner tract of the cutaneous system, and having as its inner rim the thickened edge of the fronto-nasal process; above and on the outside the rim is still more strongly marked; this is the rudiment of the olfactory sac (*ol.*).

At present this is merely a mass of cells formed by modification (differentiation) of this part of the cutaneous system; it is at present *blind* within and without; but the *depression* will become a *tube*, and the *rim* will afterwards enclose the alinasal cartilage.

Above, behind, and external to these rudiments there is another pair, having a like relation to the cutaneous system; these become the eyeballs.

The thick rim of these somewhat triangular depressions is a fold of the skin which is open in front, the structure of the eyeball being mostly horseshoe-shaped at first and circular afterwards.

Surmounting the whole we have the frontal part of the cranial region, which contains at this part the "2nd cerebral vesicle" above, and the "1st cerebral vesicle" below, the "mesocephalic flexure" having turned the latter downwards and given the 2nd vesicle (fig. 4) a *frontal* position.

This front view (fig. 1) shows a very sharp distinction between the *frontal* and *nasal* regions; for the depression on the eye-rudiment is continued across the top of the face, the two *seams* meeting in an arched manner at the mid line.

Towards this seam or "raphe" the cutaneous system is thickened both above and

below, so that where the skin of the forehead meets that of the top of the face there is a very evident selvedge; whilst the furrow between the "raphe" is of a paler colour, and is but little differentiated from the gelatinous blastema which separates the membranous cranium from the oral mucous membrane*.

The *lips*, which are so highly developed afterwards, are at present merely represented by the somewhat inturned edges of the oral opening (*m.*), the upper being formed by the emarginate lower edge of the fronto-nasal process, and the lower on each side by the bevelled supero-internal angle of the descending facial plate. These facial plates are greatly inturned at the mid line, where they form an obliquely descending raphe which is but imperfectly finished above; the oral opening being continuous with a slit which descends for some distance, the right and left facial walls being imperfectly soldered together above.

If a vertical section of the head of an embryo at this stage be made, we have the appearance seen in fig. 4.

The thick dermal layer (*d.*) is seen to follow the inflections of the membranous cranium (*m.c.*), which has already a considerable consistence, and the inflections of which relate to the form of the enclosed cerebral vesicles (fig. 4, C 1, C 2, C 3) and the rudimentary pituitary body (*py.*). The flexure of the brain upon itself (mesocephalic flexure) is shown in this figure, although its straightness is in some degree recovered. Underlying the medulla oblongata (*m.ob.*) and medulla spinalis (*m.s.*) there is a thick rod of gelatinous tissue enclosed in its own sheath; it is blunt-pointed and decurved, and it terminates a little distance behind the pituitary vesicle (*py.*); this is the notochord (*n.c.*).

The tissue forming this rod is very similar to that which everywhere fills up the spaces between the rudimentary organs in the embryo at this stage; it is a very watery kind of blastema, interspersed in all directions with delicate membranous bands, a structure well displayed in MÜLLER'S figure of a transverse section of the notochord of the Hag-fish (*Myxine glutinosa*) (see 'Myxinoids,' pl. 9, fig. 1).

Already, patches of cartilage have appeared in the outer part of the notochordal tube (sheath); the foremost of these become the postpituitary part of the basis cranii, and the following patches form vertebral arches. In this section the yelk-mass (*y.*) is seen to persist up to nearly the fore end of the notochord above, but lower down it is deficient further back; this is caused by the bulging behind of the mouth-chasm or stomo-pharyngeal cavity.

Still further down the substance of the yelk itself has undergone transformation, being applied to the formation of the rudimentary heart and its sac (better seen in next stage, fig. 12, *p.c.d.*). Beneath the sac the cutaneous system has joined from the right and left side and has produced the thick claspers (*cp.*).

In this section the oral mucous membrane is shown lining the cheek, except ante-

* Professor HUXLEY, at first sight of this figure, pointed out to me that the middle part of this "raphe" occupies the place of the azygous nasal opening of the young Lamprey (see MÜLLER'S 'Myxinoids,' pl. 4, figs. 9, 10, *f.*).

riorly, where the naso-frontal process has been cut through a little to the right of the mid line, so as to expose its cavity, which contains gelatinous tissue surrounding an upper and a lower cartilage; these cartilages underprop the 1st cerebral vesicle (C1). The form of the cheek, as seen from the outside at this stage, is simply swollen; but it becomes *ribbed* soon afterwards (fig. 2, side view); this ribbing, however, is largely developed already on the inner side (fig. 4); the subvertical thickenings contain the solidifying "visceral arches," and the *furrows* are the commencing visceral clefts: at present this dehiscence of the facial wall has not affected the cutaneous investment; but the mucous membrane has been thrown into sharp folds, as is well shown in transverse sections (figs. 5-7). The side view of a recently hatched embryo shows in its further advancement much that is instructive (fig. 2): in this figure the skin has been removed from over the auditory sac (*au.*).

Here it is seen that the three sense-capsules occupy what may be called the "lateral cranio-facial line;" they follow the curve of the cranial cavity, and lie immediately above the visceral arches, the first of which is beneath the nose but *above* and in *front* of the mouth; the postoral arches reach to the yelk-mass (*y.*) which fills the thoraco-abdominal cavity; and here the skin is already cleft on the outside; this early dehiscence is the first appearance of the opening between the last branchial arch and the anterior margin of the thoracic wall. The outer wall of the face is now rather flatter; and in lines corresponding with the internal ribbings (fig. 4) shallow sulci are seen, over which the skin is becoming attenuated. On about the middle of the 3rd and 4th postoral arches there is a small *bud*; this is the first appearance of the branchial papillæ on the 1st and 2nd branchial arches, which are thus seen to be developments of the cutaneous system. If the skin be now peeled away from the rest of the cheek (fig. 3), we shall see what caused the ribbings in the mouth-cavity (fig. 4); here are displayed a series of parallel subvertical rods of rapidly hardening cartilage, which occupy the whole space from the middle of the fronto-nasal process to the thoracic yelk-mass. Here we see that the swollen condition of the cheeks seen in the front view (fig. 1) is not so much due to the size of the oral "chasm," as to the very solid walls of the face; nearly all the tissue intervening between the oral lining and the outer skin has been expended in the formation of these bars, which are very closely packed together externally. It will be seen, both from the inner and outer view (figs. 4 & 3), that the shape of these bars is gently sigmoid, that they bulge outwards in their middle part, that they turn inwards both above and below, and that the foremost and the last two or three do not reach so far downwards as those in the middle. This arises from the fact that the foremost pair lie above and in front of the mouth, and the hinder arches lie above the pericardium. They thus follow the shape of the "stomo-pharyngeal cavity," of which they are the skeleton; and they are by no means to be confounded with the arches that grow from the segmented vertebral axis, which, when finished afterwards, enclose the *heart* and all the other viscera. The point, *first of all in importance*, which is to be noted here is that these rods are all *absolutely distinct* (fig. 3); their upper termination

is by blunt points, which are curved inwards and then a little backwards; the arches then gently curve forwards to the middle, from which part they turn backwards and inwards again. Thus, notwithstanding all the melting together of facial bars, sense-capsules, and cranial walls, in more advanced stages, nothing of the kind now exists; the after-blending is due to *secondary connectives* that fuse together the elementary organs. The first pair of these arches correspond to the "palatal bands" (MÜLLER) of the larval Lamprey (*Ammocetes*), but they indicate a much earlier stage; for MÜLLER'S figures ('Myxinoids,' pl. 4, figs. 7-10, D) show a continuity of these bands both with each other in front, and with the "investing mass" of the notochord behind; this will be illustrated in my "third stage." These bars, the "trabeculæ cranii" of RATHKE, are the shortest and the thickest of the series; they retain their parallelism with the next pair as far downwards as the middle, and then turn forward and inward, lying like *little beams* beneath the *totally distinct* membranous cranium (see fig. 8, a transversely vertical view). The second of the series (first poststomal) is the rudiment of the mandibular arch; but at present there is no segment freed from its lower end, answering to "MECKEL'S cartilage." The third, or second poststomal, is the hyomandibular and hyoid cornu in one undivided piece; the fourth is the first branchial, and has a branchial "bud" upon it; so also has the fifth, but not the sixth; the seventh arch (sixth poststomal, fourth branchial) is not yet clearly differentiated. The horizontal views are very instructive: figs. 5-7 are of an embryo younger than that dissected from the outside (fig. 3); and fig. 9 is a corresponding section to the lowermost of the earlier stage (fig. 7), in one somewhat older than that displayed in fig. 3.

In fig. 5 the rods are cut through, by a somewhat oblique section, immediately below the cranial capsule; the "investing mass," the rudimentary first vertebra (*v. 1*), and the enclosed notochord are displayed in this section, and also the shape of the mouth-chasm. Fig. 6 is a little lower down, and shows what fig. 5 does not, namely, the top of the sixth arch, or third branchial; here the inner walls of the cheeks are seen to some extent. Lower down still (fig. 7) we see the floor of the mouth, with the rudimentary tongue (*tg.*); and behind the arches, only five of which could be clearly seen, we have the large yelk-mass (*y.*) with its emarginate front outline. Expecting to find the earliest condition of the "trabeculæ" (first pair of rods) in the *ammocetine* condition (that is, continuous with the "investing mass"), these sections cost me much thought, and these observations were repeated again and again. The fact is that the *last* of the arches comes nearest to the investing mass, and not the *first*, and it is wholly distinct from the *axial* structures.

Thus we see that "the branchial arches have the same morphological value as the hyoid, and the latter as the mandibular arc" (HUXLEY, "Croonian Lecture," p. 53); and not only so, but the "trabeculæ cranii" are merely the foremost of these arches, as both of us have for some time felt satisfied.

In the earliest condition of my "first stage" (fig. 7), although these thick rods gradually decrease in size from before backwards, yet the first are twice as thick as the

second, and their section is most perfectly ovoidal. In the rest the shape in section is round within and flattish on the outside; this arises from the fact that dehiscence commences on the inner side several days before the clefts appear in the cutaneous system; yet thus early the cheeks are becoming forrowed (figs. 6 & 7) between the arches.

The incurved lower end of the arches stops short some distance from the mid line, leaving a space for the azygous pieces, which, however, do not appear for several days to come. The oblong tract of tissue between the arches below (fig. 7), which has a rounded free margin anteriorly, and which has been partly cut away in the section behind, is the basihyal and basibranchial region; the free-ending anterior part becomes the tongue (*tg.*). The tissue of which the rods are composed is cellular, very solid, and is rapidly passing into hyaline cartilage; a very evident concentric line indicates the differentiation of the perichondrium; they are imbedded between the skin and mucous membrane in a very thin layer of delicate gelatinous tissue. A transversely vertical section (fig. 8) displays the manner in which the first pair, or "trabeculæ," underprop the membranous cranium; the section is through the "first cerebral vesicle" and the rudimentary eyeball (*e.*). Here these rods seem, as seen from behind, to come into contact more nearly than they do in reality; this is caused by their being seen through the thick mucous membrane; the other sections (figs. 5-7) correct this. Immediately below the clubbed ends of these rods (fig. 8) is the upper lip; this contains a trace of solidifying cartilage of the upper labial, seen better in figs. 3 & 4 (*u.l.*). Below the mouth (*m.*) there is another and more vertical patch of young cartilage (figs. 3, 4, and 8, *l.l.*); this becomes the lower pair of labials; the first poststomals are seen from behind, and partly cut away in fig. 8: the great density and thickness of the cutaneous investment, and the tracts filled by gelatinous tissue, are shown in this figure, as also the manner in which the membranous cranium rests upon the palatal portion of the oral mucous membrane.

In the horizontal section of a hatched embryo 3 lines long (fig. 9) we have a transition towards the second stage.

The decreased "mesocephalic flexure" has carried the trabecular rods into a more horizontal position, so that the section of them is very oblique and not directly across as in fig. 7.

The next pair have freed themselves below from the better-formed rudiment of the tongue (*tg.*), and the free clubbed ends of these rudiments of the mandibular arch are now preparing for transverse fission; thus "MECKEL'S cartilage" will soon be differentiated. The next or hyoid arch is now seen to belong to the rudimentary tongue; the *gill-buds* are seen enlarging outside the first and second branchials; the fourth branchial is not yet distinct. In both the lateral views (figs. 2 & 3) the skin has been removed from over the auditory sac (*au.*): it was perfect, however; but the sac itself, already with very solid walls, is *open* on the outer side; this opening is large, oval, and turned downwards and forwards; it looks at this stage as though the whole structure had been formed as an involution of the cutaneous system. Along the "lateral cranio-facial line," in the

hinder part of which the ear-sac is planted, there is a considerable space beneath the derm, which is filled now, and for some weeks to come, with gelatinous stroma.

Second Stage.—Frog-tadpoles 4 lines long.

If figs. 2 & 10 be compared, it will be seen what great advances have been made in the development of the larval Frog, although the size is only one line longer, and the yelk-mass still fills the greater part of the thoracico-abdominal cavity.

The fore part of an embryo at this stage presents the appearance shown in fig. 10 when seen laterally, and in fig. 11 when viewed from below.

The lips (*lp.*) and mouth (*m.*) are now well developed, and the head is less bent upon itself; but the change which is of intensest interest to the morphologist is the completion of the visceral clefts (1, 2, 3, 4, 5, 6).

This dehiscence into free bands of the cephalic visceral walls characterizes the Vertebrate animal, and wholly distinguishes the stomo-pharyngeal series from all other arches.

In one sense the mouth itself is a cleft in the lowest part of the visceral wall between the preoral and first postoral arches; but I would rather consider it comparable to a neural "fontanelle," and therefore as an imperfect closure of the "membrana reuniens inferior," than to secondary openings (by dehiscence), such as we have seen the true clefts to be*. The opening between the first and second postoral arches (figs. 10 & 11, 1) only appears on the outside, in the lower third, and that imperfectly, for the skin is rather greatly attenuated than completely cleft; this is the rudiment of the "tympano-eustachian" passage. A perfect cleft, however, does appear between the preoral and 1st postoral arch; at present it can only be seen from the inner side (fig. 13, *i.n.*): this is the first appearance of the "inner nostril;" and the cleft is only completed when the nasal tube is perfect. This takes place when the *central depressed* skin over the nasal sac (*ol.*) has grown inwards, and coalesced with the mucous membrane lining the inner edges of the cleft (fig. 13, *i.n.*).

Only for a short time, and at this stage, can the cleft between the first and second postoral arches be seen externally (figs. 10 & 11, 1); it is lozenge-shaped, and has the same direction as its more perfect successors; and although the skin becomes greatly attenuated at this part, I could not discover a perfect passage. It soon closes up, afterwards to reappear as the "membrana tympani," with its overlying thin dermal layer.

The gill-buds have now become compound papillæ, of a palmate form; and the first (fig. 10, *br.* 1) has eight secondary papillæ upon it. A retral fold of the skin over the second postoral arch covers the cleft between itself and the first branchial on the outside; this is the "operculum" (figs. 10 & 11, *op.*).

The branchial clefts (2-6) are about half as long as the depth of the embryo at the same part, and are equidistant from the dorsal and ventral line; they are rounded above and more acute below; the last is the most patulous; and behind it the thoracic wall is incurved. The mouth (fig. 11, *m.*) is beginning to take on the rounded form proper to

* The lozenge-shaped opening (Plate III. fig. 1, *m.*) may be due to the absorption of a layer of cutaneous cells.

the Tadpole and like that of the Myxinoid, which it represents when its larval condition is perfect. The fronto-nasal process is now transformed into the large upper lip, with its unequal halves separated by a small sulcus.

If the fore part of an embryo at this stage be cloven vertically, we shall see what is depicted in Plate III. fig. 12.

The simple anterior cerebral vesicle (fig. 12, C 1) is now evidently composed of three lobes, namely, a small one in front, the "rhinencephalon" (fig. 12, 1^a), then a large lobe, more than hemispherical, the prosencephalon (C 1^b), and above and behind this a lobe which is compressed below; this is the "deutencephalon" (C 1^c).

Behind this third division of the anterior vesicle is the middle, and behind it the third. These are now arranged in a less curved line; for the mesocephalic flexure is becoming less day by day. This section shows the heart (*h.*) and pericardium (*pc.d.*), and also that the yolk-mass (*y.*) is retreating, the pharyngeal cavity having grown much larger and the thoracic organs more differentiated. Anteriorly, we see more clearly defined labials (*u.l.*, *l.l.*); and above the lower labial a bud of cartilage is seen ascending from the lower end of the first preoral arch; this is the first definite appearance of MECKEL'S cartilage (*m.k.*). A side view, with the skin dissected away, shows how far the facial arches have advanced since the last stage (compare Plate III. fig. 3 with Plate IV. fig. 1). The whole of the facial wall up to the yolk-mass is occupied by the moieties of the closely packed visceral arches.

This series now shows a seventh, the last, branchial (*br.* 4); it is the smallest; and the trabecula, which was the most massive, begins now to yield to the second and third. These bars have the same general form, and are much more elegant than in the first stage; they all curve *inward* both above and below, and are bowed *forward* both above and below; at their middle they are gently arcuate in the same direction (Plate IV. fig. 1).

The first pair, or preoral, have begun to adapt themselves more perfectly to the floor of the brain-sac, but they still largely retain their parallelism with the next, or first postoral pair. Below, the first postoral has not only gained a Meckelian *bud*, but it lies also at a further distance from the one behind it; this is caused principally by a commencing bend backwards of the lower half of the second postoral, preparatory to the subdivision of this pair of rods into the hyo-mandibular and cerato-hyal pieces. This arch also has now grown to be much larger than its successors (compare Plate III. fig. 3 with Plate IV. fig. 1); it also projects further outward, the skin covering it becoming the gill-cover (Plate III. fig. 10, *op.*, and Plate IV. fig. 5, *op.*). The top of this third arch is immediately below the fore end of the auditory capsule (*au.*), which is still an open sac. The remaining four arches form a series regularly decreasing in size, and their outer surface becomes more and more buried in the neck of the embryo (see also horizontal section, Plate IV. fig. 5, *br.* 1-4).

All these seven bars are still totally free, both from each other and the surrounding organs: the free, incurved upper end of the first is postorbital in position; the next

does not touch the auditory sac by a distinct space; and the third, like the four branchials, roots inward *beneath* the sac; it will afterwards coalesce with it and be carried outward to be again segmented off in a later stage. Of the many horizontal sections made in my study of this stage I have figured five (Plate IV. figs. 2-6): they dip more or less; and indeed the head is as yet bent upon itself, so as to require the section to incline forwards. In fig. 2 the three pairs of sense-capsules have been cut through (*ol.*, *e.*, *au.*), and the first cerebral vesicle, now divided into prosencephalon and deutencephalon (C 1^b, C 1^c), has been so laid open as to expose part of the pituitary body (*py.*); the upper part of the notochord (*n.c.*) is also laid bare. All that can be seen of the facial arches here, is the free incurved tops of the first and second—the third or hyoid lying in a lower plane: this view is of a solid preparation, seen from *above*. In fig. 3 the section was *arched*; the razor passing through the upper part of the yolk-mass (*y.*) below the notochord, and then severing the pituitary body from the “deutencephalon,” passed through the latter and the prosencephalon (C 1^b, C 1^c); this object was seen from *below*.

The nasal sacs are left with the lower half of the head; but the eyeballs (*e.*) are exactly halved; here we have the foremost facial arches severed lower down than in the last figure. The next section (fig. 4) is exactly horizontal in relation to the axis of the head; it is made through the notochord (*n.c.*) with its investing mass (*i.v.*), the pituitary body (*py.*), the base of the “deutencephalon” (C 1^c), and of the “prosencephalon” (C 1^b), between the eyes and nasal sacs, neither of which are displayed. The ear-sacs (*au.*) hide the tops of the third arch; but the second and first are shown in this section, which is seen from above.

In another section (Plate IV. fig. 5), which dipped considerably forwards and cleared the floor of the cranium, the whole circle of facial arches is shown with part of the notochord (*n.c.*), not its actual termination, however, but obliquely, near the first vertebra; this is shown as a *thin* slice, and demonstrates the perfect independence of the bars, besides showing the completion of the branchial clefts. Compared with the first stage (Plate III. fig. 6), we see a great change in the trabeculæ or first pair; they are growing towards each other in front, each showing a broad, squared end; posteriorly the “commissure” will be formed; anteriorly the free rounded angle of each bar will grow into a “trabecular horn.” The groove on the inside, between the first and second bar, is less deep than the next; behind the third (hyoid) the clefts are perfect. The third arch (second postoral) shows its opercular fold (*op.*); and the two next have attached to them the roots of the palmate *free gills*; the branchial arches (*br.* 1-4) are seen to be compressed in sectional form. This second stage is illustrated by another still lower section; this is a solid object seen from below (Plate III. fig. 13). Here the upper lip is cut through, and *the azygous* rudiment of the two upper labials (*u.l.*) is displayed. The mandibular and hyoid arches (first and second postorals) are cut through, and a bird's-eye view is given of the fore part of the palate. Here the mucous membrane is seen folded round the *first true cleft*, that between the preoral and first postoral arches: it is not complete at present on the outer side; but being the rudiment of the

inner nostril, it will extend to the outer side as the external nostril; like the cleft between the first and second postorals (Plate III. fig. 10, 1), it is of small *vertical* extent.

Third Stage.—Frog-tadpoles 5 lines long.

This stage illustrates the period when the *free gills* are at their fullest development before the operculum has enclosed them; they have *tertiary* papillæ at this time. In Plate IV. fig. 7, a Tadpole at this stage is shown with the skin removed from one side so as to expose the skull and face; the eye has been dissected away so as to expose the first arch more perfectly; but the nasal sac (*ol.*) and the now *finished* ear-sac are left *in situ*. All the chondrified parts, except the “investing mass” and the azygous basal elements of the face, are shown at once in this view, which is extremely instructive, and the meaning of which will be evident to the ichthyotomist at once. The facial arches have not changed their relative size so much as their *shape* and *position*; transverse segmentation is now complete in the first and second postorals; and *secondary growths*, which may be called “connectives,” have now begun to bind together these primordially free rods. The cranial cavity has now nearly lost its bend upon the spinal tube (figs. 7 and 8); and the first three arches have followed in its ascent, so that they now form an *acute* instead of a *right* angle with the general axis of the Tadpole; the gill-arches are still almost vertical. The first or preoral arch has now begun to hide itself beneath the membranous cranium, with which it will soon coalesce, and outside which it will set up the chondrifying process. Even externally it can be seen that the first and second rods are coalescing with each other above, where they lie close to each other; below this part they diverge—not, however, to lose connexion; for at the lower third a *transverse band* appears, a “connective” uniting the trabecular arch with the mandibular. This band, which had no existence in the last stage (Plate IV. fig. 1), is the first rudiment of the pterygo-palatine bar, so largely developed in the adult Frog. This “connective” lies, of necessity, *inside* the temporal (crotaphite) muscle. But the mandibular pier sends upwards and forwards another leafy growth of cartilage, which embraces the temporal muscle from its outside; this is the “orbital process” (*or.p.*), a very characteristic larval batrachian structure. We can now see what becomes of the imperfectly open cleft between the first and second primordial arches: the space between the upper coalesced part and the pterygo-palatine connective becomes the “subocular space,” whilst the space below and in front of the pterygo-palatine becomes open, first *within* and then on the *outside*, as the canal of the nasal sac, the openings being the internal and external nares. The upper part of the first postoral arch may now be called the “mandibular pier,” because the true mandible is now well developed; this is MECKEL’S cartilage (*mk.*); it is a short stout club, with a fossa for the condyle on the fore part of the lower end of the pier. It is not functional at present to a great degree, and turns upwards and inwards in thickness of the lower lip (see also fig. 8, *mk.*). The upper part of the mandibular pier, as far down as to the pterygo-palatine connective, may now take the name of the “metapterygoid region,” whilst the rest of the bar is the

“quadrate.” There is a part, however, which is not represented by the metapterygoid of the teleostean fish; this is the connective band, which has now attached it to the “investing mass,” and which I shall describe anon. In the last stage we saw (Plate III. fig. 1) that the first and second postorals were diverging below; that divergence is now very great (fig. 7), and its meaning is self-evident. With the most perfect fidelity to the ichthyic type, the auditory capsule is now overshadowing the apex of the second poststomal, ready to coalesce with it; and this bar has now begun a series of metamorphic changes that yield in interest to nothing that the morphologist encounters. It has become divided into two nearly equal parts; and the lower piece diverges backwards so far as to leave a large space between it and the “quadrate region.” The upper piece is the “hyo-mandibular,” the lower the “stylo-cerato-hyal;” the space is preparing to become the “tympano-eustachian cavity;” and the small projection of cartilage below the new condyloid hinge is a rudiment of the “symplectic” in a *plagiostomous* condition. The hyo-mandibular piece and the symplectic *bud* cleave close to the preceding bar, save at the top: all this will be seen to be full of meaning in subsequent stages. The four next, diminishing, faucial arches, the branchials, have not altered much; but they are more perfect in form, and are still quite distinct from each other and from surrounding organs. Two other cartilages are seen in this side view, namely the upper and lower labials (Plate IV. fig. 7, *u.l.*, *l.l.*); these are to be seen in the other figures. Much as a lateral view displays, there is also much to be learned from vertical and horizontal views. In fig. 9 the membranous cranium and its contents have been removed, all but the diverticulum, which contains the pituitary body (*p.y.*); the cephalic part of the notochord and the “investing mass” (*n.c.*, *i.v.*) are shown as horizontally cut through; all the rest of this view *is facial*. In this view, a solid object seen from above, the upper labial cartilage (*u.l.*), is seen to be divided into a right and a left piece; these pieces only half fill the thickness of the upper lip, which is filled with gelatinous tissue anteriorly. The middle of the fore part of the palate has been cut away, exposing the oral cavity (*m.*).

Within three or four days, whilst the embryo has grown a line more in length, the facial arches have become largely confluent. The trabeculæ have not only grown beneath the skull more perfectly, and become fused to the mandibular pier above and tied to it below by the pterygo-palatine bar, but they have also formed a large *commis-sure* in front of the pituitary body*.

This palato-facial balk is the common support and foundation, indeed, of all that is termed ethmoidal in the higher types; yet at the mid line it is a *secondary* structure. If we compare this horizontal view of the trabeculæ with that of the previous stage (fig. 5), we shall see how rapid have been the changes, not the least remarkable of which is this *closing-in* of the “palatal bands” (Gaumenleisten) round the pituitary body, which in the earlier conditions (see the position of the pituitary body, *py.*, in relation to them in fig. 5)

* This is termed by MÜLLER “vordere Commissur der Gaumenleisten unter der Nasencapsel” in the Ammonoetina stage of the Lamprey; and in the adult it forms his “knöcherner Gaumen, or hard palate” (‘Myxinoids,’ pl. 4. fig. 3, H, and fig. 7^b, d’).

were so totally unrelated. The parallel faces of the ends of the trabeculæ in fig. 5 cannot have coalesced wholly, but only behind—the free anterior rounded angle growing into the leaf-like trabecular cornua (fig. 9, *tr.c.*).

That I have not overrated the rapidity nor the kind and degree of the changes which have taken place in three or four days will be seen if fig. 2 be compared with fig. 9, as to the apex of both the first and second arch (trabecular and mandibular).

In fig. 2 we see that these tops are apiculated, inturned, free, and a long distance from the pituitary body (*py.*); in fig. 9 they have become wholly fused at the top, have nearly gained the mid line *behind* the pituitary body, and although distinct *above* from the investing mass (*i.v.*), embracing it, and forming a retral lobe, yet, seen from below (fig. 10, *tr., m.n., i.v.*) we have clear proof that these facial bars have now grafted themselves upon the investing mass, *skull and face* being now no longer distinct.

In fig. 9 the eyeball (*e*) and its surrounding stroma hide the pterygo-palatine bar; but in fig. 10 this is seen.

The top of the second postoral, or hyo-mandibular (*h.m.*), is now seen to be just *inside* the fore part of the pyriform auditory capsule (*au.*); it is close to it and is creeping outwards, ready to coalesce and be carried to the outside of the face by that part of the capsule which contains the ampulla of the horizontal semicircular canal. Behind the hyo-mandibular the section (fig. 9, *br. 1*) has displayed the top of the fourth arch, or first branchial; it is the pharyngo-branchial portion; and its counterpart is well known in Fishes, after attaching itself, quite normally, below the prootic region of the cranium. We can now see the structures on which the membranous cranium rests (figs. 8 and 9)—namely, the cephalic part of the notochord (*n.c.*), its investing mass (*i.v.*), and the auditory capsules (*au.*); the division between the cephalic and vertebral portions of the *axial skeleton* now more clearly displays the occipito-atlantal articulation, the ends of the investing mass forming the paired occipital condyles. The nature of the vertebrate skull, as, morphologically, highly compound, is well shown in these horizontal views. Even the floor of the pituitary space, the fundus of the “sella turcica,” is *cranio-facial* in its nature. In fig. 10 it is seen that cartilage is creeping beneath the pituitary body *into the substance of* that diverticulum of the membranous cranium which contains this part of the brain. Now this centripetally growing floor is derived, behind, from the “investing mass,” laterally from the trabeculæ, and in front from their secondary commissure. In this figure, which is *solid*, and seen from below, the cranio-facial base is exposed up to the front of the “commissure;” but between this part and the severed upper lip with its cartilages, the fore part of the palatal roof is shown with the *first pair of visceral clefts*, namely those which form the nasal passages. The meaning of these parts will be better shown in the *perfect Tadpole*, the next stage; but here the swelling of the mucous membrane, mesiad of the opening, is seen to be due to the overlying trabecular horn which is *inside* the nasal passage; the pterygo-palatine connective (*pg.p.*) bounds the passage *behind*; and the quadrate condyle (*q.*), here cut away, lies on its *outside*. The connective which binds the metapterygoid part of the mandibular pier to the investing mass turns suddenly

backwards, and then as suddenly forwards: these curves are clearly seen in the large Tadpole, the next stage. In this figure (10) it must be held in mind that these roots lie on a much higher plane than the amputated quadrates (*q.*). The figure must be compared with the lateral view (fig. 7); in this last the outer part of the metapterygoid is really the *elbow* shown in fig. 10; out of sight in the lateral view, the secondary connective bar grows suddenly *forwards* as well as inwards. In this lower view the upper part of the *cleft* between the prestomal and first poststomal arches is shown; it is a sigmoid tract of membrane (see also fig. 7, *s.o.f.*), the "subocular fenestra." The direction of the pterygo-palatine bar (*ppg.*) is downwards, outwards, and backwards; its development is a measure of the distance travelled by the second from the first primordial arch—the lower end of the mandibular pier (the quadrate hinge) ultimately lying directly below the exoccipital, the pterygo-palatine bar becoming nearly as long as the very elongated mandibular ramus. In the vertical section (fig. 8) many parts are brought into view and shown in their relation, which cannot be so well seen in other aspects. In the large lips we see the upper and lower left labials (*u.l.*, *l.l.*), the end of the left "trabecular cornu" under the prosencephalic region of the membranous cranium, the trabecular commissure (*tr.c.*) in section lying obliquely in a fold of palatal mucous membrane; the edge of the left moiety of the investing mass (*i.v.*) seen beneath the notochord (*n.c.*) and in the floor of the mouth cartilages are seen either as ends or sections; these will be better understood by reference to horizontal views.

The intestinal canal has now become ready for its functions, and the pharynx is narrowing where it is passing into the opening *cardia*. The heart is well formed in an ichthyic manner. In a horizontal section through the upper lip and labials (*u.l.*) and at the lower third of the facial arches (fig. 11) we get a bird's-eye view of the lower lip bulged into two rounded ridges by MECKEL'S cartilage (*mk.*), and of the tongue (*t.g.*) bulged by the massive stylo-cerato-hyals (*hy.*); the broad ramus of each side is seen in section further outwards. In front of this ramus is an oblique view, in section, of the quadrate region of the first poststomal arch; and behind the hyoid is a deep fossa severing it from the first branchial (*br. 1*); all the branchials (*br. 1-4*) are seen to be flattened from before backwards obliquely; and the termination of their intervening clefts, a good distance from the mid line, is seen. In a section made lower down and more perfectly dissected (fig. 12) the lower part of the quadrate is followed by the massive hyoid, and, the soft parts of the tongue being dissected away, there is seen a pisiform keystone of soft cartilage, soft for weeks to come, being *late* in becoming hyaline; this does not occupy the whole mesial space, but is only behind; this is the "basihyal" (*b.hy.*), and is seen in section in fig. 8.

Behind the basihyal (figs. 8 & 12, *b.hy.*) there is a large elegantly pyriform plate of cartilage forming a keystone to the first and second branchials; it is the basibranchial bar (*b.br.*), and contains two *potential* segments, the first and second of ichthyotomy. In the figure (12) the first branchial is seen to be becoming angular in section; this will be understood afterwards; the last two, seen from their lower extremity in fig. 8, are curved upwards towards the mid line, in conformity with the much narrowed pharynx. These

horizontal sections are from embryos somewhat in advance of those which are illustrated in figs. 7-10.

Fourth Stage.—Tadpoles 1 inch long.

After the digestive canal is complete the growth of the larval Frog is very rapid.

The *floating gills* become covered with the opercular fold, and at the same time lose their individuality amongst copious tufts of the same character which grow both from the outer or dermal and inner or mucous surface of the gill-arches. On the *right* side the fold of skin from outside the second poststomal (hyoid) arch coalesces with the skin of the thorax; but on the *left* side (Plate V. fig. 1, *op.*) there is a vertical oval opening for the currents of water. The coalescence of primordially distinct organs had begun in earnest in the last stage; but now, having suffered some two or three weeks to elapse, we shall find a most remarkable development of this process of mutual engrafting by the direct fusion of closely applied parts, by connective bands in lateral bars, and by azygous commissures at the mid line. The *sense-capsules* are not in the least uniform in their relation to the cranio-facial structures; for the auditory sacs are primarily distinct and then coalesce, the cartilaginous "sclerotics" are permanently distinct, whilst the nasal labyrinth, at first entirely membranous, has its floors, roofs, and walls entirely developed as "outgrowths" from the first visceral arch ("trabeculæ") and its prepituitary "commissure."

Rightly to understand the skull and face of this *perfect Tadpole* (the next stages lead to the *Frog*), it will be well to compare the corresponding figures. Beginning with the lateral view, let the eye refer back to Plate IV. fig. 7 (third stage), to Plate IV. fig. 1 (second stage), and to Plate III. fig. 3 (first stage).

Beginning with the primordial skeleton of the mouth, we see the labials at their fullest state of development; and as they are very important in relation to the various ichthyic types, especially the lower, they may now be described.

When the skin is removed from the side of the Tadpole's head (Plate V. fig. 1), or when the head is completely bisected (fig. 2), then the upper and lower labials (*u.l.*, *l.l.*) are seen to form the thickness of the wrinkled dentigerous lips (*l.p.*); between these is the nearly vertical, very small, suctorial mouth.

The upper pair (Plate V. figs. 1-6, *u.l.*) are relatively large falcate flaps of solid hyaline cartilage, the cells of which proliferate rapidly (fig. 6^a). They are almost vertically placed (figs. 1, 2), are thick and heart-shaped in section (fig. 2), the upper thick edge being grooved and embracing the decurved end of the trabecular horn (fig. 2, *u.l.*, *tr.*). They are not the germs of the præmaxillæ, nor the premaxillary axis (endoskeleton)*,

* In the "Croonian Lecture" (p. 33, fig. 9), Professor HUXLEY named the upper labial "premaxillary," and the lower "mandible;" the error was discovered too late for correction in print, as he now informs me. That is almost the only flaw I can detect in his description of the larval amphibian skull: it only extends over four or five pages (p. 31 to 35); but that and the small woodcuts illustrating it have been of inestimable value to me in working out the present paper; I should have repeatedly lost myself during my research but for this ever-present guide.

but by metamorphosis into fibrous tissue do yield *some* of the matrix in which the parosteal præmaxillæ are formed. The first possible slice that can be taken from the fore part of the Tadpole's face (Plate V. fig. 6, *u.d.g.*) when seen from its posterior or cut surface, shows that the upper horny dentigerous (*Chimæroid*) plate is formed between the upper labials and the outer skin.

The lower labials (Plate V. figs. 1-5, and Plate VI. figs. 1-3, *l.l.*) are drumstick-shaped rods of cartilage, having the lower end the stoutest; the upper end is attached to the anterior face of MECKEL'S cartilage near the symphysis. Their direction is almost vertical; they nearly meet below; and the lower dentigerous plate (*l.d.g.*) is rather below than behind these rods (Plate VI. fig. 2, *l.l.*, *l.d.g.*). The creases of the lips (Plate VI. figs. 1 & 2, *l.p.*) are covered with small hooked teeth, in addition to the two principal plates. The angle at which the lower labial is attached to the Meckelian rod (*m.k.*) is suggestive of a very different origin for the two cartilages thus unconformably related.

It would appear, from the imbedded condition of the Meckelian rods at this stage, that the lower labials are really the effective lower jaws of the Tadpole; we have in the Vertebrata a procession of three orders of mandibles—namely, the lower labials, the Meckelian rods, and the 'dentary' "parostoses."

The "trabecular horns" (Plate V. fig. 1, *tr.c.*), which sprang from the outer angle of the commissure, have grown into long, gently diverging bands, which are strongly de-curved where they articulate with the upper labials (*u.l.*).

These thickish bands are rounded at the edge; their breadth is best seen in the horizontal views (Plate V. figs. 3-5).

They are at present distinct up to the "commissure" (*eth.*, *t.c.*) (the rudimentary ethmoid), which now rises in front of the cranium as a low, rounded, transverse wall. This wall lies immediately above the pterygo-palatine bar (fig. 1, *pg.*); in this view the rest of the trabecula is largely hidden by the eyeball (*e*); that part, however, which has coalesced with the next bar is seen behind.

The sectional view (fig. 2) best shows the manner in which the ethmoidal wall has been formed, and how the rhinencephalon (C 1^a) lies behind its concave face.

The subcranial part of the trabeculæ has nearly the same thickness as the free "horns" (see edge view of right bar in Plate V. fig. 2); nor is their breadth altered in any degree (figs. 3 & 4); and in this stage it seems difficult to suppose that they do not with these horns form one continuous bar with the investing mass; nothing but a study of their development could prevent such a view being taken of them. The trabeculæ help to form the skull in the same manner as the investing mass; both lie beneath the membranous cranium, and both, by upward continuous growth of cartilaginous laminæ, enclose the fibrous sac. In the postpituitary region this is a very exact repetition of the manner in which the neural laminæ of the vertebral moieties enclose the "theca vertebralis;" and the notochordal pith is enveloped by cartilage in the same way as in a vertebra.

But the hinder part of the skull is merely a modification of the vertebral axis, whilst from the posterior boundary of the pituitary space the apparent continuity of structure has only come about by a most remarkable metamorphosis of primordial parts. The transversely oval space caused by the closing-in of the trabeculæ and the formation of the "commissure" (Plate IV. fig. 9, *py.*), has now changed into an oblong form, rounded in front and pointed behind (Plate V. fig. 3, *py.*).

We saw in the last stage (Plate IV. fig. 10, *py.*) that a floor of cartilage was forming to the pituitary space; this floor, derived both from the "investing mass" and the trabeculæ, is now complete. It no longer, however, answers merely to the floor of the "sella turcica," but is in reality the middle and anterior part of the basisphenoidal region, and also the whole of the presphenoidal. The outer edges of the trabeculæ, also, are growing upwards so as to form a cartilaginous wall outside the fibrous brain-sac; this, however, will be described when I come to the sectional views.

Referring again to the side-views (Plate III. fig. 3, Plate IV. figs. 1 & 7, and Plate V. fig. 1), we see what morphological changes the first and second poststomials have undergone. The first of these, the mandibular arch, is seen to have its once free "metapterygoid" apex connected in front to the trabecula and behind to the investing mass. As in the last stage, this connective band grows *backwards* as well as outwards and downwards (Plate V. figs. 1, 3 & 4, and Plate VI. fig. 8, *m.pg.*); above, it is separated from the ear-sac by the "foramen ovale" (5), and the remnant of the first poststomal cleft is continued as far as to the outer edge of the now dilated ear-sac. From this point, to below the cup for the styloid head of the hyoid cornu, the two arches, which were cleaving to each other in the last stage (Plate IV. fig. 7), have now entirely coalesced. Opposite the part where this hyoid portion of the large bar ceases, the mandibular pier gives off two processes and one ray.

The first of these processes is still, as in the last stage, a very short connective band, tying together the trabecula and its successor (compare Plate IV. fig. 7, *ppg.*, with Plate V. figs. 1-4, *pg.*); the pterygo-palatine bar shows as yet no signs of what it will become in the Frog. The other process (*or.p.*) is *free*, and has now grown very large, strongly bending upon the temporal muscle from without, and reaching up to the fore edge of the eye (*e*). The remaining square end of the bar (Plate V. figs. 1-5, *qu.*) is the quadrate region, with its condyle for the free ray, or MECKEL'S cartilage (*mk.*). This stout, short, clubbed rod is shown in many aspects in Plate V.; its proximal end is deeply and roundly notched to hinge upon the condyle of the quadrate; it grows upwards, inwards, and forwards, and when the mouth is closed its upper end nearly reaches the trabecula; it is joined to its fellow by fibrous tissue.

The hyoid arch has made its second great morphological change; it has coalesced with the mandibular pier in front and with the auditory capsule above (Plate V. figs. 1-4, and Plate VI. fig. 8, *s.h.m., i.h.m.*). The upper part, or supra-hyomandibular (*s.h.m.*), is attached to the auditory sac much lower down and more outward than the top of the arch in front.

In the second stage (Plate IV. fig. 1) the second poststomal was seen to be lower than the first; and now, attaching itself to the prootic region, it is carried both outwards and downwards.

This upper distinct part is small; it answers to only the upper part of the Teleostean hyo-mandibular; there is a broad sub-bifid upper head answering to the two ichthyic condyles, then a narrow neck, and then behind and below an "opercular process" (*op.p.*). Below this the two arches are fused together; but the hyoid part is demonstrated just above the commencement of the lower third, by the lunate fossa for the "styloid condyle" (Plate V. figs. 2 & 4, *st.h.*).

No further light will be thrown upon the amount of "symplectic" growth below the hinge (*sy.*) until we come to the next stage. The free terminal portion of the second poststomal bar has now become a very broad and massive plate of cartilage, the "stylo-cerato-hyal" or "hyoid cornu" (Plate V. figs. 1, 2 & 5, *hy.*); it is roughly 4-sided or lozenge-shaped, smoothly convex without, scooped within into an antero-inferior and a postero-superior fossa, divided by a ridge which passes down from the semilunar condyle. Only the posterior part of the basal line of this plate articulates with the small pisiform "basihyal," as we saw in the last stage (Plate IV. fig. 12, and Plate V. figs. 2 & 5, *b.h.*).

The four remaining arches (branchials) have arrived at their full development, and are greatly modified since the last stage (compare Plate IV. figs. 7, 11 & 12, and Plate V. figs. 1 & 5, *br.*). In the first place they have all coalesced together both above and below (Plate V. figs. 1, 1^a & 5). Three of the apices can still be seen (fig. 1^a, *p.br.*), but there is only one finger-shaped pharyngo-branchial above the first and second arches. In meeting above they form a miniature gothic arch, and the secondary bonds are thin and fenestrate; the two regions when they are joined are the "pharyngo- and epi-branchial." Below, they all unite to form a continuous "hypobranchial" region (Plate V. fig. 5, *h.br.*), which articulates on each side with the round first basibranchial and its rudimentary second segment. This hypobranchial plate, behind the basal element, overlies the pericardium (fig. 7, *h.br., pc.d.*), and lies on nearly the same plane as the summits of the arches, close beneath the mucous membrane of the throat; so that the arches, which were once immediately beneath the skin and parallel with the sides of the face (Plate III. fig. 3, *br.*), now hang like hammocks obliquely across the throat (Plate V. figs. 5 & 7, and Plate VI. fig. 5). The whole mass on each side looks like a fruit, the carpels of which are in a state of dehiscence.

This resemblance is increased by the form of the first and fourth arches; in the last stage these were acquiring an angular form as seen in section (Plate IV. fig. 12, *br. 1* & *br. 4*); but now they are baggy and crumpled, and are extremely thin. The toothings seen on their edges, which more or less alternate with each other, are covered with papillæ; but these are not calcified into teeth as in the Cod-fish and other "Teleostei," but form a rich series of transversely placed tufts—branchial tufts (Plate VI. fig. 5); in the figure the outer tufts are not shown, but they are indicated in Plate V. fig. 7. In a note

below* I give a description of the branchial tufts in a larger species, as they have been little understood hitherto.

At present little need be said of the cranial cavity; it is, as yet, largely membranous; and the cartilage related to it is, from the notochord forwards, entirely facial in its origin; and yet we have seen that the facial and the axial regions behave to the primordial membranous sac in a similar manner.

The first bone related to the skull has appeared below the elongated intertrabecular (pituitary) space; it has the same shape, and is but little larger; this is the "parasphenoid" (Plate V. figs. 2, 4, 7, *pa.s.*). The ear-sacs (*au.*) being implanted in the side-walls of the now long straight cranium, at its posterior third, the cartilage, which might have sprung up along the whole upper edge of the "investing mass," is aborted, and only appears *above*, behind, and to some degree in front of the large periotic mass (Plate V. fig. 1). That which grows up *directly from the auditory capsule* in front is the rudimentary alisphenoid (*al.s.*); that behind is the occipital arch (*so., eo.*); and that above is the pterotic (*pt.o.*): so we see that all these coalesced parts, first facial arch, periotic capsules, and alæ of investing mass, behave in a like manner, and not otherwise than the symmetrical rudiments of a vertebra as they grow upwards to enclose the "myelon" and its fibrous sheath. Yet, morphologically, how diverse are these elements! In the last stage (Plate IV. fig. 9) the periotic capsule was obliquely pyriform; but now its contents have distended it in various directions, thus altering very much its original elliptical form. The semicircular canals and their ampullæ have done this (Plate V. fig. 3); and here it is shown that even on the outside their form can be seen; and the capsule is hollowed between them, above. The horizontal canal (*h.sc.*) has not only carried the capsule outwards in front, but it has also formed a ledge which projects outwards; this is the rudiment of the "tegmen tympani" (Plate V. fig. 4, *t.ty.*). We saw that the auditory sac was *open* in the first and second, and closed

* *On the Branchiæ of Rana pipiens, Linn.*

The whole series of arches is a deep suboval shell of cartilage open at the top, and placed so as to look outwards and backwards.

There are three clefts, two cochleate bars, and between these two widish rods with rather sinuous posterior edges. On the edge of the first cochleate bar there is a rich row of tufts (the Tadpole is "Lophobranchiate"), which are principally *within*; they are well supplied with *pigment-coated* vessels, and are divided into short transverse groups.

On the second and third narrower band-like arches the vessels, which are richly coated with pigment, are covered on the outer (lower) side, behind, with short transverse rows of rich tufts; whilst from the anterior edge of the *inner* face of the bars shorter tufts, in transverse rows, grow upwards into the cavity of the shell-like branchial case; these are not pigmented, and they are large in front.

On the fourth arch the tufts are large and pigmented at the edge, and grow *less and less* in *longer* transverse rows on the inside of the spoon-shaped bar, and are not coloured black *within*, but only where they hang downwards at the free anterior edge.

The result is a most rich and almost crowded crop of free depending tufts, and a less rich development *within* and *above*.

The posterior edge of the third ray is sinuous; the *inner* tufts are set on conical elevations of *cellular* tissue.

in the third stage (Plate III. fig. 3, Plate IV. figs. 1 & 7, *au.*); it is now open again, for a long-oval segment has been as it were cut out, and yet left in, like a miniature bung; this is the "stapes" (Plate V. figs. 1, 2, 4, *st.*), and the opening is the "fenestra ovalis;" its situation is infero-lateral, and is nearly midway between the ends of the capsule.

The "glosso-pharyngeal nerve" escapes near the end of the capsule below (fig. 4, *8^a*), and the "vagus" (*8^b*) between it and the occipital cartilage; the ganglion of the fifth nerve (5) lies close to the *prootic* region, opposite the end of the notochord, and sends its branches *over* the metapterygoid connective (*m.pg.*).

The portio mollis (*7^b*) enters the capsule below the junction of the anterior and posterior canals (fig. 3, *a.sc.*, *ps.c.*, *7^b*). Posteriorly, the epiotic region (*ep.*) framed upon the posterior canal (*p.sc.*) projects nearly as far backwards as the now well-formed occipital condyles (*o.c.*).

The notochord (*n.c.*) has now become very much diminished (figs. 3-5), and is bridged over by the investing mass (*i.v.*) behind. It has *relatively* retreated in front, leaving an open fissure, the "posterior basicranial fontanelle."

Having described the face and skull from lateral and horizontal views, and from a longitudinally vertical section, I must describe the transversely vertical sections. This will involve some repetition, but a much more perfect idea will be obtained of the relation and thickness of the parts; the reader must keep the other views before him if he would understand the numerous sections.

Two things will be noticed at once in these views, namely the thickness of the "derm," and the large quantity of subcutaneous *gelatinous* stroma in which the more solid organs are enveloped.

The first transverse slice of the face (Plate V. fig. 6) has already been described; the second (Plate VI. fig. 1) shows the form of the oral opening (*m.*), and exposes the nasal tube (*ol.*) both near the skin and also near the trabeculæ, which are shown in their relation to the fore part of the palatal region. A pair of papillæ are seen lower down, projecting into the mouth, the floor of which is a deep angular fossa.

The clubbed ends of the Meckelian rods (*mk.*) are cut through on each side; and a vertical section has been made through the lower labials (*ll.*), the form and relations of which are well shown; they are invested below with the lower dentigerous plate (*l.d.g.*); and on each side the smaller teeth of the labial rugæ (*lp.*) are also shown.

This is the back view of a solid slice of the face; and the next (Plate VI. fig. 2) is the *front* view of another slice made further backwards. This section is still in front of the "trabecular commissure," and lays open a reduplication of the nasal sac (*ol.*).

Here the Meckelian rods (*mk.*) are completely displayed up to their condyloid fossa, and the lower labials (*ll.*) are seen, as also the lower dentigerous plate and labial dentigerous rugæ (*l.d.g.*, *lp.*).

The *posterior* face of the next slice (fig. 3) displays the trabeculæ in the ethmoidal region (*eth.*) immediately behind the commissure; the rhinencephala (C 1^a) are cut through.

We now see MECKEL'S cartilages (*mk.*) and the lower labials (*ll.*) from behind; the quadrate, however, is shown in section. Here we get a perfect idea of the relation of the first two visceral arches, for the section has been made through the secondary band or pterygo-palatine bar (*pa.*, *pg.*).

The remarkable "orbital" process is shown embracing the temporal muscle (*or.p.*, *t.m.*); and this muscle is almost entirely surrounded by cartilage; for there is a "pterygo-palatine process" (well seen from above in Plate V. fig. 3, *p.p.p.*), the meaning of which is not very evident, although from its relation to the lateral parts of the ethmoidal cartilage it is very probably a rudimentary "pars plana." As the section is close behind the "internal nares," a fold is seen in the mucous membrane on each side of the palate.

The next section (Plate VI. fig. 4) has been made through the hemispheres ($C1^b$), the eyes (*e.*), and the middle of the temporal muscle (*t.m.*). The manner in which the barge-shaped skull of the Frog is formed, anteriorly, is well seen in this section; for here the elongated pituitary space is bridged across; a concavo-convex plate of cartilage, representing the presphenoid (*p.s.*), and underlain by the "parasphenoid" (*pa.s.*), occupies the mid line.

Laterally, also, the trabeculæ (*tr.*) are growing gently upwards around the membranous brain-sac, and will soon form the cartilage of the orbito-sphenoidal region.

The suspensorium has been cut through close in front of the fossa for the stylo-hyal condyle, it is therefore the quadrate (*qu.*); the hinder part of the orbital process is also seen (*or.p.*). This section has been made through the hyoid cornu (*hy.*), close in front of the condyle; the manner in which these secondary (segmented) bars imitate those immediately in front of them is well shown (compare fig. 3, *mk.*, and fig. 4, *hy.*). Here, however, we encounter an additional element not seen in the mandibular arch, namely a basal azygous piece; this is the basihyal (*b.h.*); it is pear-shaped in section, the thick part below, and is composed of soft cartilage. This is a *back* view, and would seem to show that the hyoid cornua (*hy.*) were extremely solid.

A front view (fig. 4^a, *hy.*, *b.h.*) corrects this, however, and the plate is seen to be curiously sinuous and thin at parts. I shall not wait to describe the muscles which arise from the arch and which have partly been figured.

The next section (fig. 5) is the *front* view of a solid slice made through the "mesencephalon" ($C2$) and infundibulum (*inf.*); the razor passed close in front of the auditory capsules (*pro.*), *behind* the basibranchial (see Plate V. fig. 5, *b.br.*), and in *front* of the pericardium (*p.c.d.*).

Here is the upper part (the so-called origin) of the temporal muscle (*t.m.*), the fibres being attached to the anterior face of the auditory capsule and to the upper surface of the "metapterygoid connective."

The Gasserian ganglion (5) is seen lying on that band close inside the anterior face of the auditory capsule; its fibres pass *over* and in front of this mandibular *root*. The cartilage of the ear-capsule (*pro.*) is seen to be ascending on each side of the cranial sac; *behind* this view it is the pterotic, in *front* it is alisphenoidal. With regard to the

tract of cartilage running from side to side, this view is explained by part of the lower view (fig. 8); it shows the connexion of the "mandibular pier" with anterior part of the investing mass (*i.v.*).

The thick outer edge of this bar is the opercular process of the hyo-mandibular; mesiad of that the rest of the nearly horizontal part is the topmost portion of the primary mandibular rod, its metapterygoid region. The rapidly ascending part is the "metapterygoid connective," the *secondary growth* which binds this arch to the investing mass *behind* and to the "trabecular connective" (fig. 8, *tr.c.*) in *front*. The cartilage on which the infundibulum (*inf.*) rests is the *connective* or secondary portion of the investing mass (fig. 8, *i.v.c.*); this is underlain by the broadening or basitemporal portion of the "paraspheoid" (*p.a.*).

It must ever be kept in mind that a large triradiate tract of cartilage here, on each side, is entirely secondary in its growth, only appearing in the third stage; the branches of this tract may therefore be called the "connectives" of the trabeculae, metapterygoids, and investing mass (fig. 8, *tr.c.*, *m.p.g.c.*, *i.v.c.*).

Here the mouth (*m.*) is at its widest part, and looking backwards at this *front* view we see the pericardium (*p.c.d.*) overlain by the "hypobranchial" plates (*h.br.*), which nearly meet. Here also parts of the first and second branchial arches (*br. 1*, *br. 2*) are cut through, and the rich crop of *inner* branchial tufts are shown; the branchial cavity is only partly shown, the lower part of the section not being drawn, and the external branchial tufts are cut away.

The next view (Plate V. fig. 7) is a little *behind* the last; it is somewhat oblique, and catches only a small part of the infundibulum (*inf.*) beneath the "mesencephalon" (C2); the "foramina ovalia" and the right Gasserian ganglion (5) are shown in this back view of a solid section. The fore end of the "investing mass" (*iv.*) is here seen distinct from the auditory capsule on the left side, and from the "metapterygoid connective" on the right: on this side the auditory sac (*pro.*) is slightly laid open; but on the left we see the ampulla and part of the arch of the "anterior semicircular canal" (*a.s.c.*): here the *angular* height of the capsule is seen to be due to the arch of this canal. The thin, free, hypobranchial horns (figs. 5 & 7, *h.br.*) are seen investing the pericardial roof (*pcd.*); this sac is laid open, and the heart is seen *in situ*. Part of each of the four branchial arches (*br. 1-4*) appears in this section, and their convergence from before backwards is illustrated (see also fig. 5); the external branchial tufts (*e.br.*) are indicated by outlines: the whole of this section is not shown below.

The next view (Plate VI. fig. 6) is the *front* of a solid piece still further back; it is slightly oblique, and thus the right side of the mouth is seen to be becoming narrower. There is a perfect roof of cartilage over the massive "medulla oblongata" (*s.o.*, *m.ob.*); this is the superoccipital; for the occipital ring is very obliquely placed, looking forwards. The membranous cranium, now serving as perichondrium to the enclosing cartilage, is some distance from the cerebral mass, the space being filled with a very watery tissue, softer than the subcutaneous stroma.

All trace of the distinctness of the auditory capsules and the investing mass is now lost, and the occipital ring is everywhere confluent with these organs. On the left side there is a section of the ampulla of the horizontal canal, and the crown of its arch is also shown (*h.sc.*). Above and mesiad of this is part of the posterior canal (*p.sc.*). The left "fenestra ovalis" is laid open (*fs.o.*), and the right stapes (*st.*) shown in section.

The form of the "tegmen tympani" (*t.ty.*) is shown on the left side of the figure (above the stapes). The walls of the periotic capsule are very variable in thickness, the inner being thinnest; this is only apparently separate from the "investing mass," the section being made through the "meatus internus."

The oval section of the gelatinous notochord is seen to be invested below by the basal cartilage, but it is naked above (see also fig. 6^a, *nc.*, *b.o.*). A posterior view of the same slice (fig. 7) passes through the epiotic region (*ep.*), and lays bare the hinder part of the arch and the ampulla of the posterior canal (*p.sc.*). The obliquity of the occipital ring of cartilage is such that this section, although passing through the periotic mass, is yet *behind* the occipital roof.

The section has been made in front of the interspace for the "vagus" nerve; but the glosso-pharyngeal (8^a) is seen to pierce the cartilage at the junction of the auditory capsule with the investing mass. This cartilage now entirely surrounds the notochord (see also fig. 7^a, *b.o.*, *n.c.*). The oral cavity (*m.*) is now much narrowed, and is becoming the œsophagus.

Fifth Stage.—Tadpoles with hind legs reaching to end of tail.

Before the fore legs of the larval Frog appear, and whilst the tail is still of undiminished size, great changes take place in the actual and relative size of the parts composing the skull and face.

The cells of the upper and lower labials (Plate VII. fig. 1, *u.l.*, *l.l.*) have begun to pass, by proliferation, into fibrous tissue; the horns of the trabeculæ cranii (*c.tr.*) are becoming more expanded and adze-shaped, and their inner edges are growing mesiad to form the nasal floor. The upturned superior edge of the interorbital portion of the trabeculæ is growing further upwards into the side of the membranous brain-sac; and the same upgrowth of cartilage has appeared over the auditory sac in the pterotic region (*p.t.o.*).

The trabeculæ (Plate VII. fig. 2, *tr.c.*) are still distinct to within a short distance of the commissure, which is now more extended antero-posteriorly (fig. 1, *eth.*).

The nasal sacs (*ol.*), approaching the mid line, lie on the trabeculæ; at present they are membranous, but they already have a *floor* formed by the trabecular horns, and a *roof* will soon be developed.

Anteriorly the nasal sacs are only separated by soft, nascent tissue; but there is a dividing wall behind; this is the rudimentary "septum nasi," which has arisen like a rostral outgrowth from the middle of the rudimentary ethmoid (Plate VII. fig. 2, and Plate VI. figs. 9, 10, *eth.*, *s.n.*).

The relations of these parts are shown in Plate VII. fig. 1 from the side, in fig. 2 from above, and in Plate VI. figs. 9 & 10 sectionally, vertically transverse.

The broad ethmoidal wall, which had as a foundation the trabecular commissure, when seen from the front aspect (Plate VI. fig. 9), has this rudimentary "septum nasi" (*s.n.*) projecting directly from it.

The cartilage that lies between the olfactory foramina (1) answers to the "lamina perpendicularis" of the ethmoid; it is, however, very short and very thick. The lateral ethmoidal region, partly cut away in the figure (Plate VI. fig. 9) is curved gently round on each side, and passes continuously into the lateral skull-wall (Plate VII. fig. 1, *o.s.*, fig. 2, *eth.*). It also passes into the palatal bar (*pa.*), at the root of which is the curious pterygo-palatine process (Plate VII. fig. 2, *p.p.p.*), a part well seen in Tadpoles of *Rana pipiens* and *Pseudis paradoxa*; in them it has all the appearance of being a rudimentary "antorbital" or "pars plana."

A section made in front of the ethmoid, but through the growing "septum" (Plate VI. fig. 10, *s.n.*), shows the relation of the olfactory passages to the parts that are walling them in.

The trabecular horns (*tr.c.*) form a convex floor; these are connected by fibrous tissue to the partition; and a dotted line (*al.s.*) shows where the cartilaginous roof or aliseptal plates will appear. At present they are mere indifferent tissue; but soon, as the septum elongates, a laminar outgrowth of hyaline cartilage will proceed *forwards* from the anterior edge of the transverse ethmoidal wall, and *outwards* from the crest of the septum. The optic foramen (Plate VII. fig. 1, 2) and the "foramen ovale" (5) are now enclosed in cartilage; in the last stage they were passages in the membranous cranium.

The pterygo-palatine bar, which in the former stage was a mere bridge connecting the quadrate region with the prefrontal, has now acquired a length equal to that of the suspensorium; so that the subocular arch is now V-shaped.

Meantime the anterior crus of this arch has begun to lose its straight form, and to be bent a little forwards at its upper third (*pa.*); here it is partly constricted off: this transverse segmentation, although imperfect, marks where the pterygoid (*pg.*) begins; this latter part is broader than the palatine.

The metapterygoid root (*m.pg.c.*) of the mandibular arch is fast diminishing, and has begun to cling to the fore part of the ear-capsule, with which it will eventually coalesce. The temporal muscle (*t.m.*, indicated by dotted lines) still passes downwards and forwards, but much more *downwards* than before, on the inside of the orbitar process (*or.p.*); but this outgrowth is now much less, has become four-square, and is now *beneath* and *behind* the eye, not beneath and in front; it has been brought very near to the auditory sacs.

There is now a very sharp distinction between the supra- and the infrahyomandibular (*s.h.m.*, *i.h.m.*); and the upper region has become really as well as relatively less. The lower portion has grown into an ear-shaped lobe, scooped on the outside and convex within: the base of this lobe is now only half its former distance from the periotic mass.

This relative change of the infrahyomandibular has affected the hyoid cornu (*hy.*), which has been carried, skullwards, with it.

Every one is familiar with the manner in which the lower part of the first cleft is embraced entirely by the second arch in the Osseous Fishes, the *symplectic* continuation of the hyomandibular bounding this space in front, as the hyoid cornu does behind.

In this stage of the Tadpole there is a partial separation of the symplectic bar, the cartilage-cells receding from each other fore-and-aft, leaving a considerable space of clear intercellular substance entirely free from cells (Plate VII. fig. 1, *sy.*).

The segment thus partially severed is club-shaped below, and pointed above, where it reaches the cupped surface for the hyoid cornu.

Although there is a rudiment of the symplectic in the third stage (Plate IV. fig. 7, the lowest end of *h.m.*), yet I cannot find that it has developed to any extent, except to coalesce completely with the quadrate, even in the fourth stage (Plate V. fig. 1, *sy.*).

The free rays which are developed from the first and second poststomal arches to form the mandibular and hyoid arches are now much elongated. In the last stage MECKEL'S cartilage was not half so long as its suspensorium; they are now equal (Plate VII. fig. 1, *qu., mk.*). The free rod itself also has undergone a great change of form, being thickest now at its articular end; its fore part was very clubbed in the fourth stage.

The hyoid cornu (*hy.*) is not only twice as near the auditory capsule, but it is much narrower, and has coalesced with the *soft* basihyal (*b.h.*).

A deposit of calcareous matter begins now in the roof of the skull in the outer layer of the membranous brain-sac; other tracts appear in the face. These will have a definite form in the next stage, and will then be described.

Sixth Stage.—*Tadpoles with fore legs, and with tail reduced to one-half its former size.*

The last moulting of the epidermis was accompanied by so much absorption of the opercular folds as to set the fore limbs free; and now, the lungs being in function, the branchial system is fast diminishing. In this stage I will begin with that which is most apparent. We see now a pair of membrane-bones on each side of the skull-roof, closing in the great "fontanelle;" these are the frontals and parietals (Plate VII. fig. 3, *f., p.*); nor are these the only membrane-bones which have been added to the "parasphenoid;" for in the upper nasal region there is a pair of small semilunar patches, the nasals (*n.*); in front the upper labial cartilages have disappeared, and in their place, but not by immediate ossification of them, the premaxillaries (*p.mx.*) have arisen; these are short thick bars of fibrous bone, having an ascending process, the nasal process, above, whilst on the palatal region each bone is knobbed close to its fellow of the other side; this knob becomes the palatal process.

Behind the premaxillary, and below and outside the palatal bar, is a calcified web, of a styloid shape, and having an ascending process behind its first third; this is the maxillary (*m.x.*).

Within the nostril there is a small point of bone, the septo-maxillary (*s.mx.*); this will be better seen in the next stage.

The vomers have not yet appeared, but delicate spiculæ of bone are found in the fibrous stroma, lining the inner face of the suspensorium and of the pterygoid bars; these will be best described in the next stage; and when they are better developed they become the pterygoids, metapterygoids, and infrahyomandibulars.

On the outer face of the suspensorium a much better-developed plate of bone has arisen (*t.*); it is sigmoid in shape, broadish above, and pointed below; this resembles the "præoperculum," but it does not free itself from the common root of the mandibular and hyoid arches to grow backwards; it acquires a transverse "supratemporal" portion, a separate bone in *Triton*, and thus has a right to the title "squamosal" or "temporal."

On MEKCEL'S cartilage, also, membrane-bones have appeared, these are the dentary (*d.*) and the articular (*ar.*); at this stage there is no difference in the character of these bones; they are thin fenestrate plates lying in contact with the cartilage, or at least having only a slight layer of fibrous stroma between them and the rod.

The development of the cranium has been very rapid. The trabecular "horns" have united in front to form the *lower* nasal alæ; the lateral cranial walls, forming the ethmoidal, orbito-sphenoidal, and alisphenoidal regions, are now well grown (Plate VII. fig. 3, *eth.*, *o.s.*, *al.s.*).

The cranial roof, also, under the parietals, and beneath them and the frontals, is now roofed-in with an extension forwards of the pterotic cartilage (*pt.o.*): here we see the posterior half of the great upper *fontanelle* covered in.

The suborbital space or fenestra (*s.o.f.*) is greatly changed in form by a reversal of the relative length of the crura which bound it (compare Plate V. figs. 1-4 with Plate VII. fig. 3); it is also much longer from end to end. Anteriorly, the palatal region (*pa.*) is nearly segmented off by a transverse cleft from the pterygoid bar; and in front of this joint it has developed a knee-like enlargement. The pterygoid bar (*pg.*) is a very uniform flat band until it reaches the suspensorium, which part is rapidly undergoing metamorphosis. The metapterygoid root has now coalesced with the fore part of the periotic capsule. The "orbital process" (*or.p.*) is now reduced to a gently convexo-concave expansion of the fore part of the suspensorium; below, it belongs to common ground between the metapterygoid and quadrate regions, and is almost entirely *behind* the temporal muscle.

These parts are well seen from the inner side (Plate VII. fig. 4). The lower metapterygoid region as it passes into the quadrate (*m.pg.*, *qu.*) is of considerable thickness; but the starved orbital process grows out of it in front like a thin shell, its concave face inwards. But behind the middle thick part there is another shell-like plate of cartilage (*i.hm.*); this also is thin, but it has its *convex* surface on the *inner* side, and is deeply scooped externally; this is the "infrahyomandibular," between which and the metapterygoid band there is still the remains of the upper part of the first *cleft*.

The "suprahyomandibular" (fig. 3, *s.hm.*) has become a free plate of cartilage of a trifoliate form; and the hyoidean cornu, besides being longer and narrower, is acquiring a greater projection of the supero-posterior angle, whilst the condyloid part is becoming more loosely attached to the glenoid facet on the postero-internal face of the suspensorium.

But the most remarkable changes have been suffered by the branchial arches, as may be seen by comparing their condition in the fourth stage with what is depicted in this (Plate V. figs. 1 & 5, and Plate VII. fig. 3). The first and fourth arches are no longer carpelliform pouches, but are narrow bands, and all four of these bars are much attenuated. The continuous "pharyngo-branchial" tract now sends upwards six spurs or lobes; the third and fourth arches are quite free below, and the "hypobranchial" base of the first and second arches has become narrow and thick (*h.br.*). Moreover the hyoid cornua, the basihyal, the basibranchial, and the hypobranchial bars have all coalesced. These are some of the most important modifications of the branchial system preparatory to its thorough abortion.

Seventh Stage.—Young Frogs with tails reduced to a mere stump.

The metamorphic changes which for the past few days had gone on with intense activity have now produced most interesting results, many of the morphological conditions being now entirely removed from what can be seen in ichthyic types.

Many of these changes were fairly begun in the last stage; but in this further condition they make a very near approach to what is essential to the adult Frog only, or principally, being modified in the old Frog by increased size.

Beginning, as in the last stage, with the osseous plates that surround the cartilaginous basis, we find that the parietals and frontals (Plate VII. fig. 5, and Plate VIII. fig. 1, *p.f.*) have begun to coalesce; the frontals do not quite roof-in the great fontanelle (*fo.*) in front; and the parietals seem entirely to overlies a cartilaginous roof; the cartilage, however, is imperfect beneath the centre of each bone. The nasals (*n.*) are now much longer semilunar plates; and the premaxillaries and maxillaries have equally advanced: the former (*pm.x.*) have now a well-developed nasal and palatal process; and the latter (*mx.*) is forming its ascending or facial plate. Above the plate is seen a small shell-like plate of bone which helps to form a floor to the nostril (Plate VII. fig. 5, and Plate VIII. fig. 1, *s.mx.*); this is the so-called turbinal, my "septo-maxillary."

In the Frog this bone is severed from the vomer by the subnasal cartilaginous plate (Plate VII. fig. 6, *s.n.l.*). In the adult the "septo-maxillary" finds its way nearly through the nasal passage; but in the young Frog it is best seen from the outside. The squamosal (Plate VII. fig. 5, *sq.*) begins to take on its typical character, the upper part having acquired more of a transverse direction; it is also much thicker.

The upper or supratemporal region of this bone is accurately moulded upon the shell-like remnant of the "orbital process," its fore edge overlapping the margin of the cartilage (Plate VII. fig. 5, *sq., or.p.*). The descending process binds down upon the suspensorium.

The bony plates which arise in the perichondrium on the *inside* of the suspensorium and pterygoid bar can now be well seen. In the side view (Plate VII. fig. 5, *p.g.*) the pterygoid can be seen mounting above the edge of the bar; but it is best seen from within (Plate VIII. figs. 2 & 4, *p.g.*); it is a very delicate tract, much like a few threads of the skeleton of a Siliceous Sponge (fig. 4).

In front the bony pterygoid is a mere needle; but it expands at the root of the bar, then contracts, and expands once more above. The upper portion is semidistinct from the lower; it is quite distinct afterwards. Behind the metapterygoid bar another ectosteal plate has appeared, taking the form of and closely embracing the inner or convex face of the "infrahyomandibular;" this plate of bone (Plate VIII. figs. 2 & 4, *i.hm.*) answers to the inner face of the lower half of the ichthyic hyomandibular (see HUXLEY'S *Elem.* p. 176, fig. 71, *HM.*). At present there is no bony palatal on the anterior part of the subocular arch; but at its keystone there is a small style (Plate VIII. figs. 1, 2, 3, 4, *qu.*); this lies on the outside of the quadrate condyle, and projects forward; it is the ectosteal plate of the quadrate sending forward a quadrato-jugal process.

Two other bones have now appeared on each side, embracing the fifth and the eighth nerves: the foremost of them is the prootic (*pro.*); and the other is the exoccipital (*e.o.*). These patches lie principally on the underside (Plate VIII. figs. 2 & 4, *pro., eo.*), but they are also lateral (Plate VII. fig. 5, *pro., eo.*).

They do not commence in the perichondrium, but in the superficial cells of the cartilaginous cranium ("superficial endostosis"); but, unlike endosteal tracts hereafter developed, they ossify the cartilage throughout. Each tract is sickle-shaped; the prootic commences external to the nerve outlet, soon to embrace it; the exoccipital begins on the inner side. Now also can be seen a pair of fibrous bones, which never, I believe, graft themselves on cartilage or take on an ectosteal character; these are the "vomeres" (Plate VIII. fig. 2, *v.*). They are, at this stage, little spicular radiating tracts of ossified fibre, lying somewhat mesiad of the inner nares. The great basicranial splint, the parasphenoid (Plate VIII. fig. 2, *pa.s.*), has now become cross-shaped by acquiring *basitemporal wings*; in front it reaches to between the palatal roots in the prefrontal region; behind it nearly reaches to the end of the basioccipital region; and on each side its wings almost touch the edge of the "fenestra ovalis." This bone is convex and subcarinate below, and scooped above, where it undergirds the basis cranii. The dentary and the articulare are both easily separable from the cartilage (Plate VII. figs. 5, *d., ar., m.k.*); they are fast increasing in size and density.

The relation of the membrane-bones to the cartilaginous cranium is well seen in sections. The parasphenoid is seen as cut through at various points in Plate VII. figs. 7-10, *pa.s.*, the frontals in figs. 7-9, *f.*, the parietals in fig. 10, *f.*, the nasals and vomeres in fig. 6, *n., v.* They are so delicate at first, and so closely in contact with the face of the cartilage, that here at least the parosteal tracts have nothing to distinguish them from the ectosteal. From the rudimentary condition of the bony tracts it results that as yet the

zygoma is imperfect, a tract of fibrous tissue tying the minute quadrate style to the extremity of the maxillary (Plates VII. & VIII., *mx.*, *qu.*).

If the relations of the maxillaries to the endoskeleton be considered (Plate VII. & VIII., *m.x.*), it will be seen that they are rather applied as splints to the nasal capsule than to the pterygo-palatine bar; this relation to the nasal sacs is still more evident in the pre- and septo-maxillaries.

But even the maxillary itself is applied persistently as a splint, in front, to the posterior spur of the bifid "snout-cartilage." Since the last stage but one (fifth) the nasal region has undergone a remarkable series of changes, and these not easily understood. I have, however, studied this metamorphosis very carefully, both in the small common species and in other and larger types. The condition of things in the fifth stage must be kept before the eye, and then the various illustrations in this (seventh) can be read off.

The more enlarged figure of the anterior half of the primordial skull (Plate VIII. fig. 11) shows the appearance of the nasal labyrinth from above, after the removal of the bony plates. Here, this part of the skull shows that the trabeculæ have become nearly lost in the general cartilaginous growth, and that an inturned lamina from the lateral walls is continuous with a growth from the posterior edge of the ethmoid (*eth.*). But if this figure be compared with its counterpart of the fifth stage (Plate VII. fig. 2), it will be seen to what an extent cartilage has been developed around the nasal sacs. The septum nasi (*s.n.*) has now grown to the front of the face; and from its right and left edges above, and also from the anterior edge of the transverse ethmoidal wall, there has been developed a continuous *roof* of cartilage to the nasal sacs. Sectional views explain this; for the dotted line of the fifth stage (Plate VI. fig. 10, *al.s.*) is now an elegant arch of cartilage (Plate VII. fig. 6, *al.s.*).

But the septum is not only continuous with the *roof*; a *floor* has been formed by the thinning out of the trabeculæ and their coalescence with the inferior edge of the septum (Plate VII. fig. 6, *tr.*, *s.n.*). In this latter figure the septum is thickened below its middle; this is where the septal outgrowths (to be described in the last stage) terminate posteriorly.

The ends of the trabecular horns can just be traced in this more advanced stage as a pair of emarginate outgrowths, "snout-cartilages" (Plate VII. fig. 11, *sn.c.*), each projecting outwards from the front angles.

The position of these processes is at the upper surface, although in the former stages the trabeculæ turned downwards (Plate VII. fig. 1, *tr.*); but they have changed their direction, as may be seen in the palatal figure (Plate VIII. fig. 2, *s.n.l.*), where the sub-nasal laminae, or outspread trabecular horns, are seen to turn upwards behind the pre-maxillaries (*p.mx.*). Each snout-cartilage forms a valvular process over the external nostril (*v.e.n.*) in front of which it lies. But the external nostril (Plate VII. fig. 11, *e.n.*) is largely embraced by a peculiar development of the laminar roof. On the inner edge of the opening the aliseptal plate (*al.s.*) ends free; that free edge is then curled

round the greater part of the opening behind; and then the cartilage ends in a broad process which abuts against the snout-cartilage (*sn.c.*). If we now consider the manner in which the *roof* grows down into the *side wall*, it will be observed that there is a large swelling pouch on each side, connected by a broad tract with the aliseptal plate (*al.s.*), but sharply distinct from the alioethmoid (*al.e.*). Indeed, close to the ethmoid this pouch seems to be undergoing dehiscence, so as to separate the side-wall from the roof. These lateral pouches are the "alinasal" cartilages (*al.n.*); they terminate on the underside by curving in a falcate manner round the internal nostril (Plate VIII. fig. 2, *i.n.*).

The falcate process nearly applies itself to the elegant semicircular space between the outer edge of the trabecula, and the anterior margin of the palatine bar (*s.n.l., pa.*); this is the normal position of the internal nostril (see Plate IV. fig. 10, and Plate V. fig. 4, *ol.*). A triangular fibrous valve is seen within the internal opening (Plate VIII. fig. 2, *i.n.*). The passage itself is very correctly circular. The alinasal pouches are very large (relatively) at this stage.

Mesial of the inner nostril there is a delicate tract of ossified fibrous tissue, spreading like a patch of small crystals; this is the "vomer," (*v.*) related by its outer edge to the inner nostril (*i.n.*).

The peculiar position of the symmetrical vomers and the extreme distance of the inner nares, depends upon their relation to the "trabecular horns." If these coalesce to form merely the thickened base of the septum nasi, then the vomer is generally azygous, and the palatal openings of the nasal labyrinth are merely separated by the thickness of the septal base and the width of the azygous vomer. In the Frog, however, we have not merely the primary width of the diverging trabecular horns, but also their after-spreading, which gives still further lateral extension to the basinasal region (Plate VIII. fig. 2). The olfactory crura (Plate VII. fig. 11, 1) are now much nearer together; for the "perpendicular ethmoid" (*p.e.*) has grown into a definite (posterior) part of the general internasal septum, whereas formerly (Plate VI. fig. 9, 1) it was merely so much cartilage as lay between the olfactory openings in the low, thick, transverse cranio-facial wall.

The sides of this *barge-shaped* skull are now well chondrified, each ascending lamina ending in a neat selvedge above (Plate VIII. fig. 1); the *regions* of this wall are the "ethmoid," "orbito-sphenoid," and "alisphenoid" (Plate VII. fig. 5, *eth., o.s., al.s.*); the last of these has already received some bony deposit from the prootic centre (*pro.*).

Sections made transversely through the skull show well the relation of the various parts. The first, through the anterior part of the "hemisphere" (Plate VII. fig. 7), shows the cartilage of the ethmoidal region where it begins to be orbito-sphenoidal; a bulging floor connects the trabecular thickenings; and beneath this is the fore end of the parasphenoid (*pa.s.*); the ascending plate is first thin, then thick, and is then bevelled before it terminates above.

The "fontanelle" has here the tips of the frontals (*f.*) partly enclosing it; on the sides

part of each eyeball (*e.*) is shown. The next section (fig. 8) made through the posterior part of the hemispheres shows a flatter and thicker floor, and diminished trabecular and upper thickenings; the frontals (*f.*) nearly cover the top; and the parasphenoid (*pa.s.*) largely underlies the floor.

Another section (fig. 9) passes exactly through the middle of the posterior sphenoidal region, cutting through the optic lobes and infundibulum (C 2, *inf.*); and here we see that the "infundibulum" rests upon a cartilaginous floor, the original hypophysial space being filled-in by a long commissure. Here also we see an ichthyic condition—namely, perfectly continuous cartilage, from base to top, overlain by the bony matter (*f.p.*) of the "coronal" synostosis. Here, again, the trabecular thickenings (*tr.*) are evident; but on the whole the cartilage is thin.

If we look at the sectional view of the Tadpole's skull (Plate V. fig. 2), *below* and *behind* the infundibulum (*inf.*) the skull floor is imperfect. This is a remnant, partly of the original pituitary space, and partly of the fissure between the moieties of the investing mass in which the notochord terminated (Plate V. figs. 3 & 4).

In this stage it has expanded (Plate IX. fig. 10, *p.b.c.f.*) into the "posterior basicranial fontanelle" of RATHKE; it is only transitory in the Frog.

The "stern" of this barge-shaped skull keeps its "deck" now to the end; it becomes extremely wide, having the ear-capsules impacted in its sides. In the sectional view (Plate VII. fig. 10) the thin cartilaginous roof, cut through where the supraoccipital region passes into the "pterotic," is seen to pass directly into the ear-capsule, close above the arch of the posterior canal (*p.s.c.*). The apparent want of continuity in the rest of the section arises from the fact that it has been made through the "fenestra ovalis" (*fs.o.*) and the "meatus internus" (7^b). The basitemporal wings of the parasphenoid (*pa.s.*) underlie most of the width of the broad basicranial floor in which the notochord (*n.c.*) lies imbedded; it is here free above, and, below, lies on a cartilaginous commissure. Part of the stapedia plate (*st.*) has been left to this section, which also shows the posterior half of the horizontal canal (*h.s.c.*), the vestibule (*v.b.*), and the huge "medulla oblongata (*m.ob.*):" large as this is, it does not fill the cranial cavity. The two remnants of the notochordal fissure are seen from above in Plate IX. fig. 1 more highly magnified (30 diam.). The gelatinous remnant of the notochord (*n.c.*) is seen in the posterior space, which is a deep groove; the anterior space is the triangular "posterior basicranial fontanelle."

The changes that have taken place in the subocular or palato-quadrangle arch are very instructive.

The anterior crus is becoming very long in proportion to the posterior, and the palatine portion (*pa.*) is very nearly constricted off from the pterygoid (*p.g.*).

The small knuckle in front of the bend in the palatal has now become a spur (Plate VIII. figs. 1 & 2), so that there are now three regions to the palatal, namely the suspensorial or "suprapalatal," the "prepalatal," and the postpalatal (Plate VII. fig. 11, *e.pa.*, *pr.pa.*, and *pt.pa.*).

The pterygoid bar (*pg.*) is very uniform in size, but becomes broader as it passes into the suspensorium; the orbital process of the metapterygoid (Plate VIII. figs. 3, 4, *or.p.*) is now overlapped by the temporal or squamosal (*sq.*); it is a mere semielliptical expansion, convex externally and concave within.

MECKEL'S cartilage (*mk.*) has greatly increased in length, like the palato-ptyergoid bar. The quadrato-symplectic half-cleft (*qu.sy*) is still quite visible, the infrahyomandibular (*i.hm.*) is turning its inner convex face forwards, which it will do more and more. Between its upper margin and that of the sessile "orbital process" is seen the narrow metapterygoid connective (Plate VIII. figs. 3, 4, *m.pg.*), the upper part of which has now coalesced with the prootic region of the ear-capsule. Mesial of the infrahyomandibular (Plate VIII. figs. 4, 7^a), the "portio-dura" nerve escaping from the posterior angle of the "foramen ovale" passes in front of the periotic cartilage; it then runs downwards and forwards (Plate VII. fig 5, 7^a) on the inside of the posterior margin of the suspensorium, and halfway down divides into a large branch, the "chorda tympani," for the mandible, and two lesser "hyoid branches"*

For the sake of clearness of ideas we may now recapitulate the changes undergone by the first and second postoral bars. The mandibular pier is now scarcely two-thirds the length of the free mandibular ray or articulo-meckelian bar (Plate VII. fig. 5, *ar., mk.*); and the angle formed by the upper or suspensorial part with the basicranial axis is becoming almost a right angle: thus the distance between the two points of the trabecular and mandibular bars, which was at first so small as to be joined by a very narrow connective, are now united by the long pterygo-palatine rod. That part of the hyoid pier which first coalesced with the mandibular is still one with it; but the free upper head has now become segmented off as completely as the recurved lower half of the arch, namely the "stylo-cerato-hyal." There is therefore now a free "suprahyomandibular," an "infrahyomandibular" confluent with the mandibular pier, and sending down behind that bar a secondary *symplectic* selvedge. Finally, there is the proper hyoid cornu comprising the styloid and cerato-hyal regions, the latter coalesced now with its basal element.

The hyoid now becomes a long narrow bar, very unlike its earlier conditions, and becoming not only loosely attached to its original fossa, but also gaining continually a more basicranial position (Plate VII. fig. 5, *hy., st.h.*). Towards its base the bar thickens and projects forwards as a hypohyal process (*hy. h*) before it is bent backwards to unite with the still soft basal element; the latter part is confluent with the basibranchial (*b.br.*). The upper part of the hyoid pier is that in which the metamorphic changes are most remarkable and of greatest interest.

The more highly magnified views (Plate VIII. figs. 3, 4) give the best idea of these parts. The "suprahyomandibular," losing all relation to the hyoid arch, becomes now part of the *middle ear*; and a cartilaginous "opercular" of a crescentic shape (indicated by a dotted outline in Plate VIII. fig. 3, *a.t.*) forms the outer part of the auditory appa-

* I have carefully studied the distribution of the "portio dura" in the Bull-frog.

ratus, namely the "annulus tympanicus." The *essential* element of the middle ear, the stapes (*st.*), was seen in the fourth stage; the condyles and opercular process of the hyomandibular are now being prepared to form an osseo-cartilaginous chain from the "membrana tympani" to the stapes. Under these conditions a new nomenclature will be required; and this will be made to depend upon the *stapedial* relationship of the chain, notwithstanding its different morphological origin*.

I shall now call the lobes of this trifoliate plate of cartilage as follows—namely, the antero-superior "suprastapedial," the postero-superior "medio-stapedial," and the freed opercular process "extrastapedial (*s.st.*, *m.st.*, *e.st.*).

The stapes (*st.*) sends no *stalk* forwards to meet the new elements, but they grow towards it; this will be seen in the next stage. It may be remarked, in passing, that the top-most part of the second postoral arch, in becoming *free* from the periotic capsule, is merely *reverting* to its primordial condition.

The branchial arches are beginning to be atrophied (Plate VII. fig. 5); the cells forming the pharyngo-branchial spurs (*p.br.*) have proliferated into connective tissue; the arches have become very slender; and the small hypobranchial spur on each side has grown into a solid diverging horn (*h.br.*); the whole basi-hyobranchial bar has enlarged into a flat plate of nearly even breadth.

Eighth Stage.—Young Frogs of the first early summer.

During the next six or eight weeks (that is, by the commencement of summer) the young Frog has become larger by one-half, has acquired much more of its *specific* character, is more elegant in form, and much less like the Toad than in the newly metamorphosed condition.

Similar modifications have taken place in the skeleton, some of which are of the highest morphological interest; this is especially the case with regard to the "middle ear."

The flat plate which was segmented from the top of the second poststomal arch has become a narrow ray with two terete branches as bifurcations, one large and the other small (compare Plate VII. fig. 12, *s.hm.*, with Plate VII. fig. 13, *e.st.*, *s.st.*, *m.st.*). The free antero-inferior bar is spatulate, flat within, rounded without, a little bent and dilated at the end, and serves, like the "manubrium mallei" of the Mammal, for the tension of the membrana tympani, the edges of which are attached to the almost circular cartilaginous opercular. This process, the extrastapedial, is not, however, the representative of the "malleus," but is the liberated "opercular pedicle." The antero-superior lobe (Plate VII. fig. 13, *s.st.*) has now grown into a delicate terete cartilaginous ray, directly continuous with the free descending extrastapedial, but much smaller, and occupying only *one-third* of its top where it passes into it; this is the "suprastapedial;" it is attached loosely by fibrous tissue to the fore part of the tegmen tympani at the junction

* These terms are partly from Professor HUXLEY's paper "On the Representatives of the Malleus and the Incus of the Mammalia in the other Vertebrata (Zool. Proc. May 27, 1869, pp. 391-407), and are partly terms suggested to me by him in conversation.

of the prootic and pterotic regions, and therefore still retains the relation of the anterior condyle of the hyo-mandibular.

The remaining two-thirds of the top of the "extrastapedial" is occupied by the commencement of a bony ray, which has been developed out of the postero-superior lobe, the posterior hyo-mandibular head (Plate VII. figs. 12 & 13, *m.st.*); this is the "mediostapedial" (*H. & P.*).

This *apparent* "columella auris" is a somewhat crooked rod of solid bone; it is bony up to the extrastapedial and nearly to its base, which, however, is never entirely ossified. Its larger posterior end is greatly bevelled towards the skull; and a little while since, it did terminate in a large snail's-foot-like expansion of cartilage, which was growing backwards towards the stapedial plate. This expansion, formed out of the posterior margin of the third lobe in the trifoliate "suprahyomandibular" (Plate VII. fig. 12, *s.hm.*), has become a perfectly distinct segment having a cordate form, the *apex* of which is directed backwards (Plate VII. fig. 13, *it.st.*); this is the "interstapedial" (*H. & P.*); it now slightly overlaps the elegant oval valve of the "fenestra ovalis"—the "stapes" (*st.*).

In the figure (Plate VII. fig. 13) the stapes is slightly dislocated from the fenestra to show how little this *periotic segment* has changed since it was evident for the first time (Plate V. figs. 1 & 4, *st.*).

In the Frog, at any rate, there is no tendency in the stapedial plate to send a *connective process* towards the metamorphosed parts of the top of the second poststomal arch.

In the last stage the dentary was still distinct from MECKEL'S cartilage in front (Plate VII. fig. 5, *d., mk.*, & Plate VIII. fig. 5); there is now another stage of things.

In this more advanced condition the *chin-end* of MECKEL'S cartilage has been ossified into a "mento-meckelian" rod of bone (Plate VIII. fig. 6, *mk., m.mk.*); this is the "lower intermaxillary rudiment" of REICHERT. This part is very short, and is strongly united by a fibrous ligament to its fellow. The dentary (*d.*) has already coalesced with it; but the ectosteal plate *did not form* it; it is a proper endosteal bone, rapidly ossifying through the cartilage, like the prootic and exoccipital. Originally MECKEL'S cartilage was much clubbed at its distal end; even *now* the enlargement is shown, as this terminal bony part is thicker at its end than subterminally.

The branchial arches have almost entirely disappeared (Plate X. fig. 1), and the skeletal parts of the tongue are now nearly like those of the adult (fig. 2). The "stylocerato-hyal" (*st.h., ch.*) is now a narrow band of cartilage, equally attached by fibrous tissue to the suspensorium and to the opisthotic region. This band, still sending forwards a "hypohyal lobe" passing into a cartilaginous plate, belongs both to the basihyal and basibranchial, which is now entirely composed of hyaline cartilage. The whole structure is apron-shaped, the hyoidean cornu forming the upper strings. Between its upper and broadest part it has a concave *throat* edge; and below, it gives off two pairs of shorter strings. These are very different morphologically; for the first, which are feeble and unossified, are the remains of the first and second branchial arches, coalesced and almost absorbed, whilst the hinder pair are the "free hypobranchial horns" (see Plate V.

fig. 5, and Plate X. figs. 1 & 2, *h.br.*), which have now become solid bony rays, soft at the end and diverging at nearly a right angle to each other, so as to enclose the larynx (*l.x.*); and thus they form a pair of true "cornua majora ossis hyoidei."

Ninth Stage.—Frogs of the first autumn.

In the course of the first summer the Frog more than doubles its bulk; and these more developed individuals present several important changes. As the head at this stage is still, when partly macerated, a small, flat, and compressible object, it can be mounted in glycerine after being treated with caustic soda, and thus have all its parts brought into view under different magnifying powers; the figures (Plate VIII. figs. 7, 7^a, 8, 8^a) are taken from such a preparation.

The premaxillaries (figs. 7, 8, *p.mx.*) are now well developed in both their processes, nasal above and palatine below, and have become dentigerous.

The "septo-maxillary" (fig. 7, *s.mx.*) is now better seen as a notched and grooved plate of bone lying on the floor of the nostril. The maxillaries (*mx.*) are now dentigerous, and their ascending facial plate and zygomatic process are now much advanced; the latter, however, does not yet reach the quadrato-jugal process of the quadrate (*q.*).

The nasals (*n.*) are much altered in shape: they have retained their curve; but the upper part is now a broad semioval shell, sending down the lower as a mere spur overlying the palatal suspensorium.

The "coronal suture" is still visible between the frontals and parietals (*f.*, *p.*); and the former are making a more perfect roof to the front end of the great fontanelle (*fo.*).

"Below, the vomers (fig. 8, *v.*) have acquired their trifoliate shape; the *teeth* easily peel away from their *stalk* or posterior process; the internal nostril lies between and external to the second and third lobes; the first lobe grows forwards and nearly touches the premaxillary. The "parasphenoid" (fig. 8, *pa.s.*) has become much denser; it is also broader in front. Laterally, we see that the temporal bone (figs. 7 & 7^a, *s.t.*, *sq.*) has become typical; for now the supratemporal longitudinal bar (*s.t.*) is well developed, clamping the extended periotic capsule behind, and running forwards into the postorbital region. Its descending bar is now very characteristic, being stout and expanded below as a strong suspensorial splint. The quadrate ectosteal plate (*q.*), with its long quadrato-jugal process, is now more easily to be understood; for it has fairly grafted itself upon the quadrate cartilage, which the mere "quadrato-jugal" never does.

On the under or inner side (fig. 8) we see a new bony bar; it is *f*-shaped, delicate and narrow, and is immediately applied to the suspensorial part of the palatal cartilage; this is the Batrachian counterpart of the perfect bony sheath of the Fish's palatal; it does not yet touch the pterygoid. This latter ectosteal plate (*pg.*) is now well developed, although it does not quite embrace the cartilaginous rod (fig. 7^a & 8^a, *p.g.*). Its posterior descending process is very *Reptilian*; its metapterygoid process (*m.p.g.*) is now a mere spur of bone binding the front of the "infrahyomandibular," a bone which

retains its separateness, and is now seen as an ovoidal shell lining the lower two-thirds *within* of the *free* "infrahyomandibular lobe" (fig. 8^a, *i.h.m.*).

The "mento-meckelian" bone (figs. 7 & 8, *m.m.k.*) is now in a very characteristic state, with its dentary continuation (*d.*) along the *outside* of the Meckelian rod; the "articular ectostosis" (*ar.*) is now seen to be of great length, reaching on the *inside* nearly to the "mento-meckelian shaft."

The prootics and exoccipitals (*pro., e.o.*) are much extended into the surrounding cartilage, and form complete rings to the fifth and eighth nerves.

A new osseous centre has also made its appearance, and one of extreme interest, as it is especially a *Batrachian* bone; this is the "ethmoid," or "os en ceinture." It commences where the ethmoidal cartilage forms a narrow transverse ledge to the front of the boat-like skull, the anterior boundary of the great fontanelle (fig. 7, *eth.*). This bone appears to have both its ectosteal and its endosteal portions formed quite synchronously; at present no trace of it can be seen from the sides or from below (fig. 8).

After the fashion of the "Placoidei," the cartilaginous skull has begun to acquire bony matter; but this *direct calcification* of the peripheral cells of the hyaline cartilage does not take the form of *tesseræ* as in them, nor of proper morphological regions as in the higher types; it does, however, tend to *crowd itself* where, in another type, a proper bone-territory would be established.

This initial allotment is best seen in the epiotic region (*ep.*), but it can be traced on the superoccipital (*s.o.*), on the pterotic, on the basisphenoidal, and on the upper and lower nasal regions; this "superficial endostosis" can now be beautifully seen, the bony deposit being in very small grains—in semilunes half round a cell, and in separate and connected rings.

Looking at the primordial skull as a whole, we see at this stage (compare figs. 7 & 8 with figs. 1 & 2) that the cranial cavity is less oblong (it is now broader behind), and that the more extended periotic masses are relatively shorter antero-posteriorly.

The "alinasal" folds (fig. 7, *al.n.*) have lost their articulation with the ethmoid; the "prepalatal" bar is more extended and acute; the whole subocular arch is now more elegantly arcuate, and extends much further backwards. But the suspensorium has changed most; for it now turns *backwards* instead of forwards, forming an obtuse angle with the basicranial line. The extension backwards of the quadrate condyle is accompanied by much elongation of the mandible (figs. 7 & 8, *m.k.*), and the gape is now very similar to what is seen in the Crocodile.

The upper part of the suspensorium is still very distinctly seen to be double (see Plate VIII. fig. 8^a, where the parts are somewhat drawn out for display, and the retraction, so to speak, of the quadrate angle, has brought the two heads of the suspensorium into the same vertical line), the infrahyomandibular (*i.h.m.*) now lying directly *inside* the metapterygoid band (*m.pg.*). But it is the metapterygoid which has changed its place, by what I have already described, namely by fusion of the upper part of its root with the fore face of the auditory mass, whilst the "infrahyomandibular" has attained such

a position as that of a Teleostean Fish would if a similar segmentation were to take place—if the hyo-mandibular were cut away below the opercular knob, and the lower half of the bone brought up to the prootic region. The bony metapterygoid process is now a mere spur clamping the *front* of the infrahyomandibular (fig. 8^a), which has now grown into an elegant hatchet-shaped plate, the sharp bevelled edge of which glides over the smooth unossified part of the prootic at some distance outside the prootic and parasphenoidal ossifications. The deep fissure between the continuous metapterygoid and the free infrahyomandibular is the persistent upper half of the first cleft (see Plate VIII. fig. 8^a as compared with Plate VI. fig. 8, *mpg.*, *hm.* *). A specialization of a lower part of this primordial cleft is seen (shown in dotted outline) in the rounded angle between the infrahyomandibular and the descending part of the pterygoid (Plate VIII. fig. 8^a, *eu.*, *i.hm.*, *pg.*): this is the “Eustachian tube” or passage; and the remainder of the cleft has a tympanic function, and is bounded in front by the posterior margin of the suspensorium (*qu.*, *sy.*, *pg.*), and behind by the stylo-ceratohyal (*st.h.*, *c.h.*). I have already shown that the lower half of this cleft is partly occluded by the symplectic (*sy.*), which now has become completely fused with the quadrate. This stage is excellent for showing how the stylo-hyal effects its transit from the infrahyomandibular. First we saw this part articulating by a solid condyloid head with the middle of the very elongated suspensorium behind (Plate V.); then, as the upper half of the suspensorium became relatively shorter and shorter, thus carrying the stylo-hyal nearer and nearer to the skull, we also saw that the condyloid head became shorter, the joint-cavity lost, and the fibres of the capsular ligament elongated to form a lengthening fibrous band (Plate VII. figs. 1, 3, 5, *i.hm.*, *st.h.*).

In this stage (Plate VIII. fig. 8^a) the “stylo-hyomandibular ligament” is a long wavy band of fibrous tissue, still connecting the stylo-hyal region with the fossa, which was originally a “glenoid” facet.

The two heads of the suspensorium are hidden on the outer side by the supratemporal portion of the temporal bone, and by the large semilunar cartilage, the “annulus tympanicus.” This curved plate does not yet meet at its two ends; its inner or upper edge is thin, and its outer or lower has a thickened and strong selvedge (Plate VIII. fig. 8^a, *a.t.*): the “extrastapedial” bar (*e.st.*) is seen through the transparent “membrana tympani.”

The structures of the middle ear are best seen from below (fig. 8^a). The “suprastapedial” (*s.st.*) is but a feeble ray, and is loosely attached to the periotic where it is projecting outward and passing into the metapterygoid root. The “medio-stapedial” (*m.st.*) has grown longer, relatively, and is very similar to the columelliform bar of the Lizard and Bird. The interstapedial (Plate VII. fig. 14, and Plate VIII. fig. 8^a, *it.st.*) is now broadest behind, but it still retains its heart-shaped outline and is rather thin.

* This space is very large in the adult Bull-frog, and is partly filled up by a membrane-bone, the counterpart of which I have not seen in any other type.

The "stapedial," proper (*st.*), seen edgewise in Plate VIII. fig. 8^a, is in shape not unlike a mussel-shell (its front portion is shown in Plate VII. fig. 14); it is still thin, and not much larger than the fenestra ovalis (*f.o.*). The figures show these parts from below (Plate VII. fig. 14 is a more highly magnified view of part of what is seen in Plate VIII. fig. 8^a); and it is seen that the bevelled end of the "medio-stapedial" overlaps the "inter-stapedial," which in its turn overlaps the "stapedial." This takes place to a greater extent than in the Seventh Stage, which was a large advance upon the stage before it; in the adult these segments are much more compactly arranged (Plate VIII. fig. 9).

Tenth Stage.—The adult Frog.

The structure of the skull in old specimens can now be better understood. I shall begin with what first strikes the eye, namely the outer bony plates.

These have now become fairly specialized into two varieties:—first, those which refuse to enter into combination with the endoskeleton, the parostoses; and secondly, those which either directly combine with the cartilage or *lie bare* upon it, having ossified the perichondrium which separated them. Yet in no other group is the difficulty of separating parostoses from ectostoses so great as in the Amphibia*.

The premaxillaries (Plate IX. figs. 1–3, *p.mx.*) have not merely increased in size since the last stage; for the nasal processes (*n.px.*) are longer and more decurved, and the palatal processes (fig. 2, *p.px.*) are delicate and sharp. The maxillaries (*mx.*) have acquired a better facial plate (fig. 3, *f.mx.*), which articulates largely with the nasals (*n.*); and the zygomatic process (*z.mx.*), most of which is edentate, reaches to within a short distance of the quadrate, and largely overlaps its quadrato-jugal process; this is a thoroughly Batrachian condition; I am not aware that any other type has this kind of zygoma. The "septo-maxillary" (*s.mx.*) is not easy to understand; it appears *above* as a little grain of bone jammed in between the nasal process of the premaxillary and the facial plate of the maxillary (figs. 1 & 3, *f.mx.*) in front of the outer nostril. *Below*, it is seen as a little curled spicule of bone in the inner nostril (Plate X. fig. 5, *s.mx.*). A transversely vertical section, seen from behind, shows that it is more than half a tube, lining the front of the nasal passage and sending down a curled process which can be seen from the palate (Plate X. fig. 4, *s.mx.*). Another section (Plate X. fig. 6, *s.mx.*) shows how it rests upon the nasal cartilage, outside, close behind the little valvular flap (*v.e.n.*) which partly occludes the external nostril. The nasal (Plate IX. figs. 1 & 3, *n.*) is largely

* In my figures I have given an ochreous tint to those bones which *become* endoskeletal, if even they were developed from fibrous tissue at first, and have left those bones uncoloured which, *as a rule*, continue distinct from the endoskeleton of the Vertebrata generally.

There are, however, *four* varieties of bone in the adult Frog's skull, namely:—first, the unmistakable parostoses, such as the maxillaries; second, the loosely applied ectosteal patches, which may or may not become grafted on to the cartilage; third, bone-territories which affect the whole thickness of the cartilage, and in which the ectostosis and endostosis is nearly synchronous, as the ethmoid, prootic, and exoccipital; fourth, superficial endostosis with no fibrous bone grafted upon it, as in the epiotic and superoccipital regions; this last is the dying out of the chondropterygeous type of endoskeletal bone.

developed; for there is here no preorbital or lacrymal to set bounds to it*; it does not nearly meet its fellow on the broad, flat nasal cartilage; just like the vomer below. The nasal is scooped where it lies above the external nostril, and then it becomes narrow where it joins the facial plate of the maxillary, and ends in a blunt-pointed preorbital process. The roof-bones of the skull (*f.p.*) have become thick, smooth, and bevelled towards the sagittal suture, which is persistent. Not so the coronal; it is all obliterated save a small notch on the sagittal edge. These compound bones *dip* towards each other considerably; they are scooped behind above the prootics (*pro.*), to which the parietal portion is joined. Each parietal region diverges from its fellow behind, exposing the cartilaginous roof. The thick outer edge overlaps the cranial wall, and, descending, is scooped to form an "orbital process of the frontal" (Plate IX. fig. 3, and Plate X. fig. 8, *f.*). The parietal region is higher than the frontal. The relation of the nasals and fronto-parietals to the endoskeleton is shown in the sectional views (Plate X. figs. 3, 7, 8, 9). The Frog is not much more liberally supplied with bony plates than the *Lepidosiren*; for we everywhere find large bones occupying a *double* territory, if not taking the place of *three*. The so-called "temporo-mastoid" (Plate IX. figs. 1 & 3, *t.*) would seem to combine the supratemporal and preopercular of the *Triton* or of the Siluroid or Ganoid Fish; it has also a process which represents the "postorbital" of the Lizard. The manner in which the squamosal or supra-temporal bone applies itself to the protruded prootic is seen in the sectional view (Plate X. fig. 8, *pro., t.*). The descending portion speaks strongly for the subdivision of membrane-bones into parosteal and ectosteal; for it is separated from the endoskeleton by a stratum of perichondrium, and, *overlapping* the quadrate bony plate, it is separated from it by a layer of periosteum (Plate IX. figs. 1 & 3, *t., q.*).

The vomers (Plate IX. fig. 2, *v.*) are very elegant trifoliate plates of bone, wide apart, like the nasals, on account of the outspread form of the face, and correlative to the broad "subnasal laminæ." The middle leaf, which is emarginate, and the narrow falcate posterior leaf, together largely surround the internal nostril; the pointed front leaf nearly reaches the suture between the maxillary and intermaxillary; and the rounded *stalk*, which converges towards its fellow, is dentigerous. The "septo-maxillary" (Plate IX. fig. 2, and Plate X. fig. 5) can just be seen between the middle and posterior leaflets of the vomer.

The "parasphenoid" has not lost its ichthyic dimensions (Plate IX. fig. 2, *pa.*); but it has become more elegant in form. The fore part is the "rostral region" (*r.*); the transverse bars which undergird the expanded auditory masses are the "basitemporal processes" (*b.t.*). The rostrum is subcarinate, the basitemporal plates are obliquely truncated postero-externally; the median part ends behind the transverse bars, and supports the narrow unossified basioccipital cartilage (*b.o.*). Sections involving the parasphenoid are figured (Plate X. figs. 7-10, *pa.s.*), and show the differentiation of a definite perichondrial layer between it and the endoskeletal basis cranii, from the ethmoid (*eth.*) to

* In the Bull-frog there is a lacrymal.

the basioccipital (*b.o.*); so that during development it has remained true to its original character.

The rest of the bony centres may be studied as part of the endoskeletal skull; they are shown thus in the figures (Plate VII. fig. 16, Plate VIII. figs. 9, 10, Plate IX. figs. 1-9, Plate X. figs. 7-10), which represent them both from the surface and in sections.

When the parostoses are removed from a partially macerated skull, a very remarkable osseo-cartilaginous structure remains (Plate IX. fig. 6, upper view, and fig. 7, lower view); for whilst the cranium itself is like a flat-bottomed boat, the superpalatals near the front, and the auditory masses behind, project like two pairs of *out-riggers*.

These projections are connected together by the bowed pterygo-palatal bars; and the quadrate *dips* its condyle outwards, backwards, and downwards. Forthstanding from the fore end of the skull we see a symmetrical pair of chambers; these are continuous above and below, and are parted by a septum (Plate X. figs. 3 & 7, *s.n.*), the "septum nasi;" the whole structure, seen from above and below, is ox-head-shaped, the "horns" being, each, the main lobe of the right and left emarginate snout-cartilage, the axis of the premaxillaries, the only *free* part of the "cornua" of the trabeculæ.

Both above and below (figs. 6 & 7, *sn.c.*), these sessile snout-cartilages send back a retral process which has a valvular relation to the nasal openings, outer and inner, partly closing the opening on its outer side (Plate IX. figs. 6, 7, *v.e.n.*, *v.i.n.*).

On the inner side of the inner nostril there is another valvular process (fig. 7, *i.v.p.*); this is better seen in the more enlarged figure and in the sectional views (Plate X. figs. 3, 4, 5, *i.v.p.*); it is a small curved horn of cartilage with a broad fixed root in front.

The transverse anterior margin of the nasal labyrinth is elegantly crenate, and the cartilage, both above and below, is partially hardened by endosteal bone on its superficies; the mid line is gently concave, both above and below (Plate X. fig. 7). The nasal roof is made by the "aliseptal" laminae (*al.s.*), the floor by the "subnasal" or trabecular laminae (*s.n.l.*).

The external nostril is surrounded below and behind by the "alinasal lamina" (*al.n.*), which has greatly changed from its condition in the 7th stage (compare Plate VII. fig. 11, and Plate IX. fig. 6, *al.n.*); for this curled cartilage was relatively very large, and articulated behind with the ethmoid above the superpalatal bar; but now it is small, has become more freely segmented from the nasal roof, and the part which articulated with the ethmoid turns forwards and has a free notched end. There are no turbinal outgrowths in the Frog's nasal capsule, and yet it is very complicated anteriorly; this complication is *septal*, and does not arise from the "alæ," as is the case with true *turbinals*. A transversely vertical section (Plate X. fig. 3) through the outer nostrils displays an unexpected number of laminae, which I have only been able to understand by reference to what takes place in higher types. The section has been made exactly through the external nostril (*e.n.*), and close to the fore edge of the internal nostril (see Plate IX. fig. 7, *i.n.*); it has passed through the nasal process of the premaxillary (*n.px.*) above, and through the palatal process (*p.px.*) below. The aliseptal lamina (*al.s.*) is here at its narrowest,

and the subnasal (*s.n.l*) at its greatest width. At the outer angle, below, the maxillary (*m.x.*) has been cut through, and mesiad of it the vomer (*v.*) at a great distance from the palatal processes of the premaxillaries (see also Plate IX. fig. 2). Here we see that the septum nasi (*s.n.*) gives off three pairs of alæ—the aliseptal above, the subnasal below, and between them, near the top, another, which passes downwards and outwards, forming a floor to the external nostril (*e.n.*). The alinasal is at this part *fixed*, although it is *free* behind; and it is continuous with the intermediate cartilaginous ala, which may be called the “transeptal lamina.” Although there is no free “alinasal turbinal,” there is nevertheless a fixed lamina answering in some degree to it (compare Plate X. fig. 3, *al.n.*, *t.s.l.*, with that of the *Tinamou*, ‘Skull of the Ostrich-tribe,’ plate 15. fig. 11, *n.t.b.*); for the “transeptal lamina” splits, when nearly half across, into two nearly equal layers, both of which terminate externally; the lower of these is evidently the *fixed* counterpart of the free “alinasal turbinal” of the Bird.

That the valvular processes are free “horns” is evident from this view, which shows the valvular process of the external nostril (*v.e.n.*), and the inner valvular process of the internal nostril (*i.v.p.*), both quite separate as sections.

A section made through the anterior margin of the annular ethmoid (Plate X. fig. 7, *eth.*) shows the perfect simplicity of the *true olfactory region*, which is of great width, and is closed externally where the upper and lower alæ pass into the “superpalatal” (*s.pa.*). Above (Plate IX. fig. 6, *s.pa.*, *al.e.*), the “ala,” now “aliethmoid,” passes directly into the “superpalatal” without any notch; but below, the “subnasal lamina” becomes narrow, and has a deep notch separating it from the thin lower flap which thickens to pass into the “superpalatal” (Plate IX. fig. 7). The ethmoidal roof, even a little in front of the annular bony mass, is the part from which the upper turbinals arise in higher types; the foundation for the middle turbinals must be sought for in the prefrontal wall on the posterior surface of the two laminæ which pass into the “superpalatal.” The sectional view does not show this, for the razor passed immediately in front of it; but in the bird’s-eye view (Plate IX. fig. 6, *p.r.f.*) the back of the *folded* lamina is seen, and on the postero-superior surface, which is bevelled, sloping down to the orbit, there is a very notable prefrontal patch of *endostosis*, the morphological counterpart of the “prefrontal” of the Teleostean fish, the Crocodile, and the Monitor, the “antorbital” of the Bird, and the “pars plana” of the Mammal; this would be the root of a “middle turbinal,” if such there were.

The “notch” between the “subnasal” and the foundation of the palatal pier is cut through in the section (Plate X. fig. 7, *no.*); mesiad of this notch the dentigerous part of the vomer (*v.*) is severed, and outside it the thin ectosteal palatal (*pa.*), whilst on the roof is seen the nasal (*n.*). The bony substance of the ethmoid is seen both above and below the section, which has been made through the pointed middle portion (Plate IX. figs. 6, 7, *eth.*); this is the part where the “perpendicular ethmoid” ends and the proper “septum nasi” begins (see Plate VII. fig. 11, *p.e.*). A section made immediately behind the olfactory passages (Plate IX. fig. 8, 1) shows the fossæ in which the “rhinencephala”

rest, separated by the free end of the perpendicular ethmoid; this part is a feebly carinate projection, and sends backwards nothing that can be called a "crista galli." The nerve-outlet is single on each side; but this passage answers to the slit on each side the "crista galli" in the Mammalia, which in them is bridged over by many bars of bone, and thus converted into a series of foramina.

The ethmoid is *cranial* as well as *axio-facial*, and just so much room as the "rhinencephala" need belongs to it by right, so that the "girdle-bone" is not the absolute measure of this region; it does not reach far enough in the young of the Common Frog, nor in the adult of some species, whilst in others it trespasses on the surrounding territories when they are unprovided with their own bony centres.

Here, indeed, the "rhinencephalic lobes" do not reach so far back as the ethmoidal walls would indicate; for these are partly built upon orbito-sphenoidal ground. There is scarcely any tendency to the production of a *subcranial keel* as a continuation backwards of the perpendicular ethmoid; but the basis cranii is flat and shark-like, only modified by a gentle bulging below (Plate IX. fig. 9). Where the basal part of the ethmoid joins the presphenoid its margin is gently concave; it is more scooped above, where the bony matter first began; for here it forms the front margin of the great fontanelle (*fo.*).

To sum up the characters of this simple ethmoid, let it be noted that the "*rhinencephalic fossæ*," the *roof* upon which the frontals and, in most types, the top of the nasals rest, the *floor*, which in many types of Vertebrata joins a similar presphenoid behind, and the "*pars perpendicularis*"—all these are formed from one bony centre in the back wall of the nasal cavities, and the front end of the cranium. The cartilaginous foundations of this structure were laid in that part of the "*trabeculæ*" which was the first to coalesce, in front of the original pituitary space, and from which coalesced portion there grew, at a very early period, a transverse wall separating the brain from the nasal sacs (Plate V. figs. 1, 2, 3).

With regard to the succeeding regions, which have received anthropotomical names from the well-known bony centres, these must be surveyed from strictly *neural* landmarks, and not measured by the very indefinite bony tracts. The anterior sphenoidal region extends from an ideal line drawn circularly round the cranium outside the posterior margin of the "rhinencephala" to the "foramen opticum" (2). A section through the middle of this region shows the large orbital alæ, "orbito-sphenoids," as a rather thin lamina of hyaline cartilage, which ends by a sharp edge above (Plate IX. fig. 9, *os.*).[¶]

These alæ pass into the "presphenoidal" region below, which is somewhat thicker where it bulges down upon its undergirding bone, the "parasphenoid" (*p.s.*, *pa.s.*); these alæ, thus united below, enclose the "prosencephalon" (C'), the roof being strongly finished by the frontals, which send downwards rudimentary orbital plates. The anterior margin of the orbital alæ has been ossified by the ethmoid; for the rest there is only incipient "endostosis" below, in the presphenoidal region; and this is not divided off

from a like deposit in the basisphenoidal, whilst, common to both, is the permanently separate cortical plate, the "parasphenoid."

The posterior sphenoidal region, like the anterior, is devoid of any distinct bony centre, and must likewise be surveyed by the primordial land-marks, the nerve-passages. Thus the lines that fall unto it are from the "fenestra," in which the optic passage lies in its fore part, to the great "foramen ovale" behind. *Apparently* its landmark has been removed; for the "prootic" stretches forwards over two-thirds of this space (Plate VIII. fig. 9, *al.s.*, *pro.*).

Below, in the basisphenoidal region, and on the sides, as far as they are unaffected by the prootics, the posterior resembles the anterior sphenoid in all that is essential; above, however, we note a difference; for we are now *behind* the great fontanelle, and the alisphenoids end above in a roof-plate, a rudiment of the very perfect cartilaginous roof of the Shark, in which type the "fontanelle" looks forwards at the fore end of the cranium. In Osseous Fishes the thick upper edge of the alisphenoidal cartilage adjoining the roof is separately ossified, and forms their large "postfrontal," the cartilaginous basis of which may, or may not, pass across the primary "fontanelle."

The postsphenoidal roof-plate is feebly ossified by endostosis, the rudiment of a "suprasphenoidal" bone. This upper tract is lozenge-shaped, but the posterior and lateral angles pass into the adjacent regions (Plate IX. fig. 6, *su.s.*).

The outstretched auditory region has acquired one large pair of bony centres, the "prootics" (*pro.*); but the roof-crest ("pterotic"), the supero-posterior ("epiotic"), and the infero-posterior ("opisthotic") regions are but little differentiated in this way; yet the auditory masses are largely ossified behind, having a borrowed source of bone, the "exoccipitals" (*e.o.*).

Seen from the inside (Plate IX. fig. 5), the periotic masses have a smoothly rounded face, which, projecting inwards, takes from the cranial cavity (Plate X. fig. 9); outside, as in the Lacertians, these masses project so as to increase the breadth of the skull threefold, thus throwing out the mandibular pier, and giving the mouth its enormous gape.

In a section made through the "foramen ovale" (Plate X. fig. 8, 5), the ampulla of the anterior canal is exposed with part of its arch; here the parietal (*p.*) is the only roof to the skull in one place, above the posterior fontanelle (*p.fo.*); externally the fore edge of the prootic region (*pro.*) is rather flat and largely unossified; this is the part where the "metapterygoid root" has coalesced with the front face of the auditory capsule. This narrow outer half of the projecting prootic region is strongly clamped by the supratemporal part of the squamosal (*s.t.*). Ossification has affected the rest of the cartilage throughout, and it reaches nearly to the "posterior fontanelle" above, and to the thick part of the parasphenoid (*pa.s.*) below. The "Gasserian ganglion" (5) is seen *in situ*, and above it a projecting spur of bone.

In the next section (fig. 9) the crown of the arch of the anterior canal is cut through (*a.sc.*), and the whole width of the labyrinth-cavity is exposed, near the middle of which

is seen the ampulla and part of the arch of the "horizontal canal" (*h.sc.*). This section has been made close behind the posterior fontanelle, between the prootic and exoccipital (see Plate IX. fig. 6, *pro., eo., p.fo.*), cutting through the posterior part of the parietal (*p.*), and the broad basitemporal portion of the parasphenoid (*pa.s.*); on the inner side the auditory nerve (*7^b*) is seen passing through the "meatus internus." A little of the prootic (*pro.*) is seen here, both in the cranial and in the auditory cavity; and above, it encloses the crown of the anterior canal, and reaches that of the horizontal (*a.sc., h.sc.*). The outermost part of the projecting periotic mass is thicker here and is deeply scooped. If the section had been made a little further backwards, it would have passed through the "fenestra ovalis" (see Plate VIII. fig. 4, *fs.o.*); but in the adult the original fenestra is largely walled-in with cartilage, leaving only a small opening to the "vestibule" (Plate VII. fig. 16, *fs.o.*). The piece of cartilage seen in the fenestral pit is the stapedial (*st.*); and below the pit the unossified cartilage is "opisthotic" (*op.*), regionally considered. This section fortunately runs through a very important articulation, namely that of the stylo-hyal (*st.h.*) with the opisthotic cartilage.

The original ovoidal form of the periotic capsule is not entirely lost, as may be seen by comparing the inner view (Plate IX. fig. 5) with this section, which shows the form of the cavity, and the bulging inwards of the inner wall.

Only a narrow border-land is left above between the overgrown prootic and exoccipital bony centres (Plate VIII. fig. 9, Plate IX. figs. 1, 3, 4, 5, 6), and the occipital arch is, as in all the "Sauropsida," confused in its ossification with the posterior face of the periotic mass; nothing can more plainly bespeak caution in determining true morphological *regions* from encroaching bony growths; we never see the auditory sense-capsule perfectly differentiated from the occipital and sphenoidal regions, as a bony mass, until we reach the Mammalia.

A section made still further back passes through the epiotic eminence (Plate X. fig. 10, *ep.*), which is affected by endostosis at the surface; this eminence is caused by the development of the arch of the "posterior canal" (*p.sc.*), which passes downwards and forwards to reunite with the anterior canal. It is crossed close above its ampulla by the "horizontal canal" (*h.sc.*), the ampulla of which was shown in the last section (fig. 9); part of the stapes (*st.*) is seen in the fenestral fossa behind; and part of the parasphenoid (*pa.s.*) is seen towards the mid line of the skull. Across this part the skull is tolerably well ossified—not, however, by a "periotic" centre, but by the exoccipital. There the bone is so thick that medullary cavities are seen in it; it reaches to the narrow basioccipital region below (*b.o.*), and to the wider supraoccipital region (*s.o.*) above; this is ossified superficially, but the basioccipital region is not.

Further explanation of the transverse sections is given by a side view, in which the outer surface has been partly pared away (Plate VIII. fig. 9); in this way it is seen that the ampullæ of the anterior and horizontal canals (*a.sc., h.sc.*) are imbedded in the large spreading prootic (*pro.*), whilst the ampulla of the posterior canal (*p.sc.*) is enclosed in the exoccipital (*eo.*) Below the posterior ampulla is the exit for the compound 8th

nerve (8); below the two bony masses is the huge deep fossa for the stapedia and interstapedial cartilages (*st.*, *it.st.*); and below this hollow is the rounded unossified opisthotic region (*op.*), to which the stylo-hyal (*st.h.*) has at last become closely attached. The broad occipital condyle (*o.c.*) is capped with persistent cartilage; and the exoccipital bony mass mounts up above the condyle into the supraoccipital region, and descends below into the base of the skull.

The endoskeletal part of the premaxillary region has been described with the nose-capsule; we now come to the lateral regions. There has been no tendency to segmentation of the "superpalatal" bar from the prefrontal mass (Plate IX. figs. 6, 7, *s.pa.*, *pr.f.*); and the "prepalatal" (*p.pa.*) is now a flat triangular projection slightly affected by endostosis, continuous with that of the rest of the bar. The constriction between the "postpalatal" and pterygoid regions is now obliterated (*pt.pa.*, *p.g.*); the ectosteal palatal lamina (fig. 7) has not increased in size *relatively*; thus most of the palatal region is left unarmed with bony matter.

The "subocular fenestra" (*s.o.f.*) is a large ellipsoidal space made slightly reniform by the bulging of the cranial side-wall; outside it is bounded by the elegantly arcuate anterior part of the pterygoid (*pg.*).

There is still a very solid core of hyaline cartilage to the pterygoid, the "Anoura" being very remarkable in that the ectosteal plates show, for the most part, so feeble an affinity for the cartilage within, and even for the endosteal bone into which the cartilage is changed ('Shoulder-girdle and Sternum,' pls. 5-8, pp. 66-89). This unchanged core is most exposed on the upper surface (Plate IX. fig. 6). The metapterygoid bony spur (*m.pg.*) is now small and placed *anterior* to the triangular "infrahyomandibular" (*i.h.m.*); behind the latter is the deep recess which bounds the "Eustachian tube;" and then the pterygoid grows downwards, backwards, and outwards, strongly clamping the suspensorium (figs. 1-7); this posterior portion of the "ectosteal pterygoid" is a *supererogatory* growth of fibrous bone, its proper cartilaginous axis ending at the front margin of the suspensorium.

The posterior part of the bony pterygoid is best seen from behind (fig. 4, *p.g.*), in which view we can most readily understand the manner in which the suspensorium is continuous with the skull in its metapterygoid or antero-external portion, and how it glides on the skull by its postero-internal portion, the infrahyomandibular (*m.pg.*, *i.h.m.*).

The metapterygoid portion of the suspensorium is overhung by an *eave* of cartilage from the projecting periotic capsule; this eave is cut through in front of the suspensorium in the section (Plate X. fig. 8); and under the shadow of this eave the "extrastapedial" *spatula* turns forwards to receive, on its outer surface, the fibres of the "membrana tympani" (Plate IX. fig. 3, *a.t.*, *e.st.*). The cartilaginous eave is *tiled* over by the embracing supratemporal part of the squamosal, the projecting edge of which forms a strong ridge for the attachment of the ends of the cartilaginous "annulus," which have now met each other (Plate IX. fig. 3, *a.t.*, *s.t.*).

The quadrate angle of the subocular arch now projects almost as much backwards as

it once did forwards, so that the angle formed by the suspensorium with the basicranial axis is very obtuse (see Plate IX. fig. 3, *g.*). The ectosteal plate of the quadrate is overlapped in its broad grafting portion by the spatulate lower end of the squamosal; in front of the cartilage the quadrate plate grows into a long quadrato-jugal process which largely overlaps the long jugal process of the maxillary.

The posterior lobe of the quadrate condyle is, in reality, the "symplectic lobe" (*sy.*); but, as in the palato-pterygoid, the cleft has filled-in again*, which for a time separated it from the mass of the quadrate: this return to a lower type seems to be peculiar, but must be caused by some general law.

The rest of the mandible has changed very little from its condition in the last stage. The "intermaxillary rudiment" or "mento-meckelian" (Plate IX. fig. 3, *m.mk.*) is permanently small, and the dentary runs back two-fifths of the length of the ramus; the "articulare" ensheaths the inner side completely, but a wide space of the permanently unossified core is bare on the outside. The articular condyle (*ar.c.*) is a smooth egg-like mass, with its long axis longitudinal; it rolls very freely beneath the smoothly scooped base of the quadrate.

The pier of the next arch has been differentiated into most of the structures of the middle ear, as well as the hyoid crus; it has been subjected to a large amount of special metamorphosis, the hyoid arch lending, as it were, much of its substance to the organ of hearing.

When the parts which have grown by modification of the suprahyomandibular segment are examined *in situ* (Plate IX.), it is seen that they reach from the stapedia plate (*st.*) to near the anterior edge of the membrana tympani (Plate IX. fig. 3, *m.t.*, *s.st.*). Seen from behind (fig. 4) the whole series is arcuate; for the "medio-stapedial" ascends a little, and the extrastapedial descends in the same degree; but the principal direction of the former is *outwards*, and of the latter *forwards*, whilst the feeble "suprastapedial" ray passes upwards, backwards, and inwards, and is loosely attached to the "tegmen tympani" by a delicate fibrous ligament. In the enlarged side view (Plate VIII. fig. 9) the whole series of "middle-ear" elements is drawn out, longitudinally, for display, the "tegmen" being pared away, the osseous medio-stapedial (*m.st.*) being bent towards the skull, and the cartilaginous parts freed from their attachments. The "suprastapedial" (*s.st.*) is a delicate rounded rod continuous with the "extrastapedial" below, and forming an acute angle with the medio-stapedial" (*m.st.*); it is the "anterior hyomandibular fork" modified (see Plate VI. fig. 8). The "extrastapedial" (*e.st.*) is an elegant spatula; it is thin, convex on the outer and concave on the inner side, and on its *convex* side it receives the fibrous mesh of the "membrana tympani" (Plate IX. fig. 3). At first sight it would seem strange that this free cartilaginous *spatula* should answer to the outstanding condyle on which the "principal opercular" is articulated in the Osseous Fish; but a reference to the early condition of these parts in both Fish and Frog will make things clear. If my fourth stage (Plate V. figs. 1-4, and Plate VI. fig. 8) be

* Here we have what may be called *retrograde metamorphosis*.

compared with the embryonic skull of the Teleostean (HUXLEY, 'Croonian Lecture,' p. 29, fig. 8, and 'Elem. Comp. Anat.' p. 185, fig. 72), it will be seen that the hyo-mandibular runs almost directly *forwards*, and that the boss to which the "opercular" is attached grows out a little distance below the posterior hyo-mandibular fork. Now the segmentation of the hyo-mandibular in the Frog takes place immediately below this *boss*, leaving it free; and from the first it has a direction *forwards*, which is only intensified and not altered in the adult. The "medio-stapedial" (*m.st.*) has now all the appearance of the osseous auditory "columella" of the Lizard; it is twisted and curved somewhat, is very slender at first, and then bulges behind; it is bevelled at its end, towards the skull, and is slightly unossified at its edge behind. The bevelled inner face of the "medio-stapedial" articulates with the lower half of the outer face of the "interstapedial," the segment which was taken from its base. This intercalary piece, the undoubted homologue of the mammalian "os orbiculare," has now become a solid wedge of hyaline cartilage, and has found lodgement in the anterior part of the deep "stapedial fossa." The "interstapedial" is pointed in front, has a convex upper, and concave posterior and lower margins; it is thick and solid, especially behind, where it articulates with the stapedial plate. The homology of the "interstapedial" is with the *condyle* of the "posterior hyo-mandibular fork" of the Osseous Fish; its function is to connect the true "stapedial" (or auditory) segment with the medio-stapedial *hyoid* element. The periotic element, "stapedial" (*st.*), is elegantly elliptical in shape; but the anterior margin is shortened, where it fits to the subconcave face of the "interstapedial" (Plate VIII. fig. 9, *st.*, *i.st.*); it is gently concave on the inner face, and is very thick and convex on the outer (Plate VII. fig. 15, *st.*); like the other parts of the middle ear, with the exception of the medio-stapedial, it is wholly unossified. It is attached to the edges of the fenestral fossa by a delicate band of fibrous tissue (see Plate VIII. fig. 10, where it is seen from within); but much of the inner face is in immediate contact with the cavity of the vestibule.

The "fenestral or stapedial fossa" (Plate VII. fig. 16, *st.f.*) is beautifully egg-shaped and of considerable depth (see section, fig. 15); behind, the exoccipital (*e.o.*) keeps at some distance from its rim; but in front the prootic (*pro.*) sends a small wedge of bone into its fundus. The "fenestra ovalis" (*fs.o.*) takes up the postero-inferior third of the fundus; it is reniform, with the concave edge looking obliquely forwards and upwards; it nowhere reaches the edge of the pit; the main otoconial mass (*ot.*) can be seen through the "fenestra." This operculated cleft in the "periotic" wall was once the size of the stapedial plate; the floor of the pit has grown, whilst the stapedial plate has been thickening, as the creature has become full-sized. The "stylo-hyal" (*st.h.*) has its permanent attachment a short distance below the rim of the *fossa* at its interior third (Plate VII. fig. 15, Plate X. fig. 9, *st.h.*).

The "stylo-cerato-hyal" band of cartilage has changed but little since the Frog was two or three months old; it has not become osseous (Plate IX. fig. 3, *st.h.* and Plate X. fig. 2). The "hypohyal" region (*hy.h.*) retains the lobe, both before and behind, which was seen in the Tadpole (Plate V. fig. 2): these lobes have now become

elegant leafy plates of cartilage ; they both look forwards and are separated by a narrow band. The deeply concave anterior margin is accurately semielliptical in outline ; behind this great "notch" the broad cartilaginous "basi-hyo-branchial" plate is continued backwards so as to have a length equal to its greatest breadth ; it is narrower behind than before, and the sides are concave.

The single pair of remnants of the first and second branchial arches (*br.*) are curiously dissimilar ; they are not much in front of the "free hypobranchial horns" or thyro-hyals (*th.*) : these latter have become much more slender in the shaft, and are wide behind ; they are well ossified by an ectosteal sheath or "shaft-bone."

The great basal plate has irregular patches of "superficial endostosis" on its surfaces ; but its various outgrowths are soft ; it has lost the symmetrical foramina (fig. 1). The upper surface of this evenly spread lamina of cartilage is gently concave ; its long sigmoid suspensors, the hyoid cornua, give it its exquisite mobility (see Plate IX. fig. 3, *hy.*), a state of things of no little consequence to the Frog with its peculiar mode of respiration.

SUMMARY.

It appears to the writer that several things are *proved* in the foregoing descriptions which could only be *guessed at* if the subject had not been treated in a somewhat exhaustive manner. The most important part of this attempted demonstration of the morphology of the Frog's skull is that which treats of the first two stages ; without these the labour would have been greatly in vain, as nothing could have been determined as to what is a *primary morphological element*, and what is a mere *secondary* structure, uniting together and, by that fusion, immediately *masking* the simple primordial structure.

But the processes of growth are so rapid, the *axis* of the embryo is subject to such peculiar bending and straightening processes, the relation of parts so greatly altered by that which was afar off being brought near, and *vice versa*, that a complete mastery of the earliest differentiation is fundamental to the whole business of research. This teaching was long ago impressed upon me by the "Croonian Lecture," which contained the rudiments of this extended monograph ; I can appreciate its value now that I have worked for a long while at the real objects.

In the skeletal parts I consider that to be a *primary morphological organ* or *element* which is first differentiated into a definite tract of tissue more solid than the surrounding blastema, and which continues thus distinct until it can be demonstrated to be cartilage by the formation of a concentric line which marks off the outer or cortical cells as the perichondrial layer. This can be done in the Frog-embryo when it is only one-sixth of an inch in length, two or three days before hatching, and when the cephalic and caudal extremities project very little beyond the yelk-mass : this is my first stage. This is not the point at which to commence *general* embryological research into the structure of the Frog, but is a very convenient stage for the *special* morphology of the skeletal parts.

Any *opening* found at this stage in the *walls* of the embryo is evidently *primary* ; for it is anterior to that most remarkable *dehiscence* of the visceral walls by which the "facial

clefts" are formed; there is at this stage an opening of this kind, a *visceral fontanelle*; it is the opening of the mouth (Plate III. figs. 1 & 8, *m.*). The secondary openings (*clefts*) are of the utmost interest, as the two foremost of them are persistent in the highest Vertebrata, and form the passages necessary to the organs of *smell* and *hearing*.

The primordial cartilaginous bars which are so definitely separated by the clefts are modified to an unlooked-for extent themselves, and also serve as a foundation upon which, *continuously*, structures are built with which they could have had no primary relation.

The Cranium,

in the first place, may be remarked upon as being largely constructed upon facial bars, as well as having a true *axial* region, continuous with the vertebral column.

The neural axis, whilst passing from a grooved into a tubular form, acquires a membranous investment; this investment lies immediately upon the notochord and the symmetrical vertebral rudiments. In the vertebral part of the axis this is a mere cylinder; but in the cephalic region, where the vertebral rudiments are *continuous* to the end of the notochord, the neural mass becomes swollen into vesicles, and the membranous investment into *pouches*. This lobular bag, with its cerebral contents, does not derive the skull, which more strongly encloses it, from the continuation of the axis merely; for the axial part stops short behind the down-turned pituitary vesicle (Plate III. fig. 4).

The remainder of the skull has a *facial* foundation; it is built upon the first pair of facial arches, which straighten themselves beneath the membranous cranium, and then send outgrowths of cartilage upwards which form walls on each side and in front.

Not only so, but the auditory sacs imbed themselves in the lateral walls, which are really derived from the *axis*, thus forming a large "fenestra" on each side, which, however, is closed by the auditory sac.

Thus it is seen that the skull of the Frog is a *morphologically compound* structure.

The Sense-capsules.

Two pairs of these, the optic and the auditory, have their own cartilaginous *pouch*, and are, primarily, equally independent of all the surrounding skeletal structures, the *earball* as much as the eyeball.

The olfactory sacs, however, are entirely membranous; and the labyrinthic chambers in which they are lodged, and to which they form a lining, are developed independently as superstructures upon the first pair of visceral arches, and upon the *secondary* "connective" which binds them together.

If all this be true, then the terms *cranium* and *face* are commonly used in a very arbitrary manner; the terms *axial*, *visceral*, and *sensory* must be used as much as possible if we would speak correctly of these things.

But the term *skull* for the cartilaginous or bony box enclosing the whole brain can

never be misunderstood if its composite character be borne in mind; the sensory organs, as well as the jaws, cheeks, and parts of the throat, must all be included in the term *face*.

The Visceral (Facial) Arches.

The Frog develops seven pairs of visceral arches: the seventh is not differentiated until a few days after hatching; and these simple, free, subarcuate descending rods undergo an amazing amount of metamorphosis.

The last four, the gill-arches, are transitory, and their remains are of little importance in the adult; the first three concentrate nearly all the interest upon themselves.

The diagrammatic figures (Plate X. figs. 11–20) are intended to illustrate ten stages in the morphology of these three arches; and as the auditory capsule enters into such remarkable relation with two, and especially with the last, it is figured also.

The first arch is shown in dotted outline, the second in continuous outline, and the third is coloured.

In the first stage (fig. 11) we see three curved clubbed rods, slenderest above, where they end in somewhat twisted points, which turn a little forwards. The first (1 *tr.*) is the “trabecular” rod; it is *recurved*, and diverges from the next; for here is the oral opening. The other two (2 *mn.*, 3 *hy.*) are very similar; but the foremost is the thicker of the two; they are curved somewhat backwards as well as inwards, below. Here we have the rudiments of the first and second “postoral bars,” or the mandibular and the hyoid. The auditory pouch is *above* and *behind* the third bar.

Fig. 12 represents the second stage, a few days after hatching; in this already there are some changes to be noticed.

The slight curve forwards of the narrowing upper part of the two foremost bars (1 *tr.*, 2 *mn.*) has increased, the lower part of each has expanded, and the second has formed a small inturned bud, the rudiment of MECKEL'S cartilage (*mk.*).

Another important change is the divergence, backwards, of the lower half of the third arch; and the approximation of the auditory sac to this arch above is noteworthy (3 *hy.*, *au.*).

Fig. 13 represents these arches in a Tadpole 5 lines in length; here the changes have been sudden and great.

The “mesocephalic flexure” is almost obliterated, and the first pair of bars (1 *tr.*) have also ascended; but they have likewise applied themselves more accurately to the base of the membranous cranium, and have coalesced with each other in front of the pituitary body and with the second arch in two places.

The second arch (2 *mn.*) has coalesced above with the investing mass and with the first arch; it has diverged in its descent much more from the trabecular bar; but at its lower third a connective bar has bound the two together (*p.pg.*); outside this connective there has appeared a leafy flap of cartilage which encloses the temporal muscle. The free leaf of cartilage is the “orbital process” (*or.p.*), and the fixed secondary band is the first rudiment of the pterygo-palatine arcade; this therefore is not in the Frog a primary arch.

MECKEL'S cartilage (*mk.*) is now well developed as a free segment cut off from the second facial (first postoral) arch.

The auditory capsule (*au.*), now a closed pouch of cartilage, has overgrown the top of the third arch (*3 hy.*); and the upper part of this arch has applied itself close to the antero-inferior face of the sac. It is then free, and then applies itself closely, to beyond its middle, to the second arch; but the diverging lower part has now become segmented from the upper, an oblique joint-cavity has been formed, and a small angle of the upper part projects below the joint.

All this is typically *ichthyic*; the upper part, closely applied to but not coalesced with the auditory sac, is the "hyo-mandibular" (*hm.*); the small angular projection below the joint is the "symplectic" (*sy.*); and the free segment is the "hyoid cornu" ("stylocerato-hyal") (*hy.*).

Fig. 14.—In perfect Tadpoles an inch or more in length, the cranial cavity, its trabecular *rests*, and the suspensory part of the short Meckelian rod have all undergone great relative as well as real elongation. The free outgrowths of the trabeculæ ("cornua," *c.tr.*) now form large unsegmented counterparts of the Meckelian segments of the next arch, and behind the commissure they have become united by a thin connective tract, which forms the cranial floor. The pterygo-palatine band has not lengthened, so that the suspensory portion of the second arch now forms a very acute angle with the basicranial axis. It has become largely bowed-out, however, and has thus formed the large "subocular fenestra" (*s.o.f.*), an expansion of the *true* first cleft, or that between the trabecular and mandibular bars.

The connective at the top of the second arch is now long, bows outwards and backwards, and is confluent with the investing mass behind and the trabecular root above. The second cleft (first "postoral") has its upper part still very evident in the space between the band in front, and the auditory sac and top of the third bar behind. This remnant of the second cleft is rounded below; and thence the rest of the hyo-mandibular ("infrahyomandibular," *i.hm.*) has become completely fused with the arch in front; this region also is greatly elongated, so that the elegant condyle of the "hyoid cornu" (*hy.*) is articulated to the lower third of the compound suspensorium, and the more mobile parts of the face and mouth are here as far from the ear-sac as in *Syngnathus*.

The free hyoid cornu is now of great breadth, but, as in the third stage, it has not coalesced below with the basihyal. The "suprahyomandibular" region (*s.hm.*) is now relatively much smaller; it has gained a more external position with regard to the ear-sac, with which it has coalesced by a pedate or sub-bifurcate head. The neck is narrow; and below the neck it bulges downwards so as to form an "opercular process," a truly *ichthyic* structure. The ear-sac has opened again; and its *own* opercular piece, the "stapes" (*st.*), is some distance behind, and more internal than, the head of the hyo-mandibular.

In the fifth stage (fig. 15) the mandibular pier (*qu.*) has receded from the trabecular

region (1 *tr.*), thus giving rise to an elongated pterygo-palatine (*pa.*, *pg.*), now as long as the suspensorium; this bar is semisegmented. MECKEL'S cartilage (*mk.*) has similarly increased in size; the orbital process (*or.p.*) is becoming starved, and is changing an anteorbital for a postorbital position; and the connective of the second arch is not so far from the front of the ear-sac.

But the most interesting changes are taking place in the third, or "second postoral arch." The "suprahyomandibular" (*s.h.m.*) has become nearly free; and the "infrahyomandibular" (*i.h.m.*) has grown upwards into a large leafy lobe, which turns its convex side somewhat inwards. Moreover the whole upper region is only half as long as in the last stage, so that the free hyoid cornu is so much nearer to the skull; it is also much narrower in form.

The "symplectic" rudiment (*sy.*) has grown down the posterior edge of the much elongated quadrate region, and is partially segmented from it.

In the 6th stage (fig. 16), Tadpoles with stumpy tails, MECKEL'S cartilages and the pterygo-palatine bars (*mk.*, *pa.pg.*) are both longer than the suspensorium, on the front face of which, near the top, is seen the remains of the "orbital process" (*or.p.*). The elongating hyoid cornu (*hy.*) is becoming detached from its fossa, the joint-cavity degenerating into a mere loose ligamentous union. The "infrahyomandibular" (*i.h.m.*) has its free lobular edge still higher up; and the *starved* "suprahyomandibular" (*s.h.m.*) has become a free trifoliate plate of cartilage. It has now lost its ichthyic character, and is becoming *functionally related* to the stapes (*st.*) as part of the middle ear; and its lobes can now be identified with the processes of cartilage which are connected with the stapes in the "Sauropsida." The antero-superior lobe is the "suprastapedial," the postero-superior is the "medio-stapedial," and the free process, which grows downwards and *forwards*, is the "extrastapedial;" the whole piece is now detached from the auditory capsule above, and it is still some distance in front of the stapes.

Seventh Stage (fig. 17).—This is when the little Frogs have nearly lost the tail-stump; a cartilaginous "annulus tympanicus" can now be seen. There is not much difference between this stage and the last in many respects; but the "hyoid cornu" (*hy.*) has become very long and narrow, is quite loosened from its original attachment, and is gaining a new one above. In the sixth stage the palatine (*pa.*) was bending forwards; it is now pointed in front; in both the "trabecular horns" are almost entirely involved in the nasal labyrinth.

Eighth Stage (fig. 18).—In Frogs taken a month or two later, the pterygo-palatine and MECKEL'S cartilage (*pa.pg.*, *mk.*) are still more elongated, and the relatively shortened suspensorium (*qu.*) forms a right angle with the basicranial axis. The metapterygoid root clings more closely to the periotic cartilage; and the "infrahyomandibular" (*i.h.m.*), relatively smaller, is acquiring a more *inward* position. The *narrowing* hyoid bar is now quite loosened from its old attachment, and is very near to the opisthotic region. The detached "suprahyomandibular" has now undergone a more perfect metamorphosis than can be seen in either Lizard, Crocodile, or Bird. The anterior head has become a

delicate terete rod which passes upwards and backwards, and is attached to the "tegmē tympani" by a fibrous ligament; this is the "suprastapedial" (*s.st.*). The freed "opercular lobe" has become an elegant spatulate "extrastapedial" (*e.st.*); and it is tilted more upwards than when it was unsegmented in the fourth stage (fig. 14). The hinder head of the "hyo-mandibular" has bent itself downwards a little, has become relatively very long, and has become ossified into a little bony shaft. The "condyle" at its free end has become segmented off into an "orbicular element," the "interstapedial" (*it.st.*); the bony bar is the "medio-stapedial" (*m.st.*).

Ninth Stage (fig. 19).—In three months more the facial bars are becoming more and more like those of the adult, the pterygo-palatine and Meckelian rods larger still; and as a correlate of this, the suspensorium now forms an *obtuse* angle with the basicranial axis. The "infrahyomandibular" (*i.hm.*) now forms an elegant hatchet-shaped condyle, which glides over the antero-inferior face of the periotic cartilage directly *inside* the metapterygoid root. The elements superadded to the stapedial are lengthened, are more elegant in form, and more completely adapted to the proper stapedial plate. A long sinuous ligament still binds the stylo-hyal head to the inferior angle of the "infrahyomandibular;" but a new ligament ties it to the periotic capsule below the stapes.

Tenth Stage (fig. 20).—We now come to the skull of the old Frog, where we see what is typical in the *highest* form of the Batrachian. The first or trabecular bar (1 *tr.*) still shows the tips of these "horns" on the front of the nasal box; but, for the rest, they are completely amalgamated with the nasal and cranial structures. Between them and the second bars (first postorals, *qu.*) there now intervenes the long, elegantly arcuate, fore-spurred pterygo-palatines (*pa.pg.*); and yet this second bar, to which the *middle third* of the third bar has coalesced, has much the same curve in itself, and has a similar angular relation to the basicranial axis as in the first stage (compare figs. 11 & 20). Thus the mandibular pier, leaving out of consideration the free Meckelian rod, has gradually travelled so far forwards as to be nearly parallel with the basis cranii (fig. 14), and then has slowly grown backwards until it has more than regained its original position. The middle third of the third (second postoral, *i.hm.*) still retains its suspensorial function, although it has long lost its distinctness. Having been carried upwards during growth, it reaches just to the point where the *apex* of the arch was in the third stage (fig. 13, *h.m.*), when the auditory sac had grown so far forwards as to overshadow the bar. Having lost the upper third, which was segmented off to form the uniting chain, it now articulates by a gliding joint (Plate IX. figs. 2, 4, 7, *i.hm.*) with that same region of the ear-sac; and the mandibular pier, having clung to the much-projecting cartilage of that sac, is now exactly *outside* this remnant of the third bar. The 4-cornered free hyoid segment, once so far from the ear-sac, and being indeed the lowest *two-fifths* of the third bar (fig. 13), is now a *long band* articulating with the ear-sac a little way *behind* the *head* of the middle part ("infrahyomandibular"), from the *base* of which it was first taken (fig. 13 & fig. 20). The highly metamorphosed upper end of the second postoral bar now forms four out of five of the elements of the "middle-ear" chain. The stapedial plug (*st.*) and the ter-

minal segment of the superadded series, the "interstapedial" (*it.st.*), now lie in a deep fossa in the thick periotic wall; and the "fenestra ovalis" only occupies the posterior third of the fundus. Rounded in front, the stapes fits into the concave end of the parrot-beak-shaped interstapedial by a cup-and-ball joint; the piece in front, "medio-stapedial" (*m.st.*), is attached to the latter by the upper edge of its bevelled broad base, which is not entirely ossified; but there is no joint between this narrow-topped bony bar and the two unossified rays in front—namely, the delicate terete "suprastapedial" (*s.st.*), and the large spatulate extrastapedial (*e.st.*).

With regard to the *clefts* that part these foremost facial bars, it may be seen that although they are persistent yet they have undergone very curious morphological changes. The first cleft, that between the trabecula and mandibular rod, began to open *inside* the angle where the two clefts diverge (fig. 11) in front of the part where the transverse connective afterwards appears (fig. 13).

It slowly completed itself by dehiscence of the dermal tissue; and thus an external and internal nostril were formed. The pterygo-palatine bar filled up the next part of the cleaving space; and the remainder was filled in below by fibrous membrane, and above by fusion of the heads of the two arches.

The next *secondary* opening, the cleft between the first and second postorals, forms for a little while an obscure, imperfect opening through the skin, in the space in front of the divergence which forms the free hyoid cornu (figs. 1, 3). On the inner side, above, there lingers for a long while a mere membranous tract between the heads of the two arches; and this is in some degree persistent, for the joint-cavity between the "infrahyomandibular" and the ear-sac (Plate IX. figs. 2 & 7) is the remnant of this space.

But opposite the partial external opening, in the space formed by the divergence of the lower third of the bars (figs. 1, 2), there is no filling-in on the inner side. The angular space between the descending quadrate and the hyoid cornu (see figs. 13 & 14) becomes modified (Plate IX. fig. 7, *eu.*), and is completed into a ring by membrane; this is the outer end of the "Eustachian tube;" and this short tube, which opens into the throat within, expands externally into the tympanic cavity, between the "extrastapedial," the "stylo-hyal," and the "quadrate."

Thus the first postoral cleft, although showing so little on the outside, is yet largely developed on the *inner*, and, like the persistent portion of the *preoral cleft*, becomes a structure of the highest importance; the one helps to perfect the olfactory organ, the other the organ of hearing. Not only so, they are intimately related in their higher morphological conditions; they both open on the same plane into the great oral chasm; and the foremost pair form the *bellows* which supply with air the hindermost in their tympanic function. The process of dehiscence by which the nostrils, Eustachian tubes, and ear-drums were formed, was taking place in my first stage (Plate III. fig. 11), before the formation of the heart and liver, and a long while before the intestinal cavity.

I need not recapitulate what has been said of the transitory arches, the branchials; their *clefts*, although by far the most perfect, entirely disappear.

Bibliographical references and comparisons with other Vertebrate types.

Considering that the present paper is merely one of a series, and that its character is very *special*, there will be little need for reference to the invaluable works which have reference to the *general* structure and development of the Amphibia.

The most important help, indeed, has been derived from works treating of *other types*, especially where the *skeletal* parts have been worked out.

In my endeavour to make plain to others what to my own mind was for a long while a labyrinth of difficulties, I have had constant recourse to the works of Professor HUXLEY, especially his "Croonian Lecture," 'Elements,' and "Representatives of Malleus and Incus in other Vertebrata." But such reference is only part of the matter; for we have been workers together in this research.

Another most valued author, whose works have been always with me from my youth up, must be mentioned, viz. the late Professor JOH. MÜLLER; his Monograph on the 'Myxinoids' has been vital to this attempt to make plain the intricate morphology of the Batrachian skull.

I shall make comparisons of the present subject with the structure of various Vertebrate types, and, first, may give

A. *A comparison of the Skull of the Common Frog with that of other "Anura."*

In the Bull-frog (*Rana pipiens*, L.), with a perfect general agreement, there are variations in particulars of the utmost interest*.

In the Bull-frog the upper labial is both notched and fenestrate, but it is never cut through as in the Common Frog, in which it was single at first. This corresponds with what is seen in the Lamprey (MÜLLER, 'Myxinoids,' pl. 4. figs. 2-4, N).

The external angles, however, are almost segmented off, showing a tendency to form the "rod-shaped appendage of the labial ring" (MÜLLER, *op. cit.* pl. 4. fig. 2, Q); the lower labials are much more developed than in the common kind, and are relatively nearly as large as those of the Lamprey. Another myxinoid character in the Bull-frog is the large amount of free trabecular horns left in front of the nasal sacs after the latter are well formed; they persist also in the adult as free leaf-like flaps, the divided counterparts of the Lamprey's emarginate "ethmo-vomerine plate" (MÜLLER, *op. cit.* pl. 4. figs. 2-4, L).

Full twice as many bones, "ectostoses" and "parostoses," are found in the Bull-frog as compared with the common kind; these especially abound in and on the "suspensorium," and have been very instructive to me in working out the Grey Frog, enabling me to speak more confidently of *ichthyic parts* and *regions*.

One thing must be mentioned in: *R. pipiens* as in *Hatteria* (HUXLEY, "On the Representatives of the Malleus and Incus," p. 397, fig. 4), the "suprastapedial" retains its *secondary* fusion with the auditory sac. The cartilaginous "annulus tympanicus"

* I am now drawing from unpublished material; the dissections and drawings of the larval Bull-frogs and of a huge Tadpole of *Pseudis paradoxa* were made from specimens given me by Professor FLOWER; the adult Bull-frog I received from Dr. MURIE.

forms a perfect ring in the Bull-frog, its ends becoming completely confluent; its "pteric" and "epiotic" regions, although soft, are as well developed as in the "Teleostean" Fishes.

One thing appears to be quite unique, although it will perhaps turn up in some other type, and perchance in the extinct "Labyrinthodont;" this is the presence of an *anterior* "parasphenoid," the fore part of the "rostrum" being separately ossified.

A similar breaking-up of centres is seen in the palatines, maxillaries, "infrahyomandibulars," &c.

My great use of the larval *Pseudis* has been to obtain a thoroughly satisfactory elucidation of the formation of the nasal alæ and septum; and in it I first clearly saw that the pterygo-palatine band was an entirely *secondary* growth: in this type there is another "connective" *in front of* the nasal opening, from the inner angle of the quadrate to the trabecular horn. In *Bufo vulgaris* the "extrastapedial" is shaped like a peltate leaf; its "suprastapedial" is small, terete, and *free*; its "medio-stapedial" bar is very long, and is ossified by a small shaft bone where it passes into the "extrastapedial," and the rest by a larger shaft.

The "stylo-cerato-hyal" is very large in the larval condition; it undergoes the same morphological changes as in the Frog, and ultimately *coalesces* with the auditory sac, as in the Mammalia.

B. Comparison of the Frog's Skull with that of various ichthyic types.

1. With *Petromyzon marinus*.—In the larval stage ("*Ammocætes*") as given by MÜLLER (*op. cit.* pl. 4. figs. 6–10), the "trabeculæ" have coalesced, but the "horns" have not budded out; thus it is later than my second stage, and earlier than the third. The author has not shown the other facial bars; the first pair (D), as here figured, have already become nearly straight, and, besides uniting by the "anterior commissure," they have coalesced with the "investing mass" (*d*).

In the adult (*op. cit.* figs. 2–4) an amount of morphological change has taken place wholly beyond what might have been expected in so low a Fish. The three foremost pairs of arches have coalesced with each other above, and also with the investing mass. In front of the "commissure" the trabeculæ have developed an azygous bilobate plate, the equivalent of the symmetrical "horns" of the larval Frog; and their immediate successors, the mandibular bars, have each sent forwards a styloid rudiment of MECKEL'S cartilage (fig. 2, *i*), which, however, like its trabecular counterpart, is not segmented off. The pterygo-palatine bar (*I*) is as large as in my "fifth stage." The hyo-mandibular (*i'*) diverges early from the mandibular pier, with which it is largely confluent above; it has cut off a "stylo-cerato-hyal" (*i''*).

The branchial arches (*d, d, d*) are tied together above by a continuous "connective," which runs into the fused roots of the mandibular and hyoid arches. They are converted into an exquisite piece of basket-work by being extensively bound together by similar *secondary* growths. (OWEN, 'Lect. Comp. Anat.' p. 52, fig. 11.)

So much, at any rate, may be said of the skull and face of the Lamprey as read in the light of the development of the same parts in the Frog; they mutually illustrate each other; and in my ten stages, whilst the earliest is two steps lower than the Ammocœtine larva, as given by MÜLLER, yet, if the oldest stage of the Frog's skull (see Plate IX. figs. 6 & 7) be compared with that of the adult Lamprey, it is evident at once that, notwithstanding its almost *mammalian* metamorphosis of certain parts, much that is truly *petromyzine* remains in the old Frog.

2. *With the Skull of Chimæra*.—The skull and face of this remarkable type may be illustrated by the earliest conditions of those of the Tadpole.

In the Chimæroids the excessive growth of cartilage (MÜLLER, *op. cit.*; HUXLEY, Elem. pp. 195–197, figs. 77, 78) has obliterated all traces of distinction between the “investing mass,” “trabeculæ,” a large part of the first and second postoral arches, and the auditory capsules.

The space formed by divergence of the trabecular and mandibular bars is entirely filled in by cartilage, so that the “orbital process” is not a distinct flap from the pterygo-palatine; and the “subocular fenestra” is also completely occupied by the same growth. Thus there is no distinction between the “metapterygoid” and “mesopterygoid” regions (HUXLEY, fig. 78, *D*); and there is no boundary between the prefrontal and palatal regions. The “trabecula rhorns” are thoroughly involved in the nasal walls; but they send out symmetrical and also single outgrowths as “snout-cartilages” (MÜLLER, *op. cit.* pl. 5, fig. 2, *i, h*). The mandibular arch also develops an outgrowth below as in the Lamprey; but this is segmented off as in the Frog: this thick mass of cartilage (*C*) is “MECKEL'S rod.” The third (hyoid) arch is largely confluent with the second; but in HUXLEY'S figure of *Chimæra monstrosa* a groove is shown on the inner side (fig. 78); this is the remnant of the upper half of the first postoral cleft; yet the parts before and behind it, the metapterygoid and hyo-mandibular regions, are thoroughly confluent. As in the Lamprey and Frog, the lower diverging half becomes segmented off from the second postoral as the hyoidean apparatus (MÜLLER, fig. 2, *k, l, m*; HUXLEY, fig. 77, *o*). There are many upper and lateral “labials;” but there is a large single horseshoe-shaped lower piece (MÜLLER, *c*).

The trabecular floor of the skull (HUXLEY, fig. 78) is thin; and from the commissural region there proceeds a transverse wall separating the *cranial* from the nasal cavity, exactly as in the Tadpole.

The great “upper fontanelle” is entirely roofed-in with solid cartilage, which is continuous with the shelving nasal roof (*Na*): thus in *Chimæra* we have middle and lateral ethmoids, with their upper alar growths all marked out, and also the Batrachian *trabecular floor*.

3. *With the Skull of Sharks and Rays*.—In *Squatina* (MÜLLER, *op. cit.* pl. 5. figs. 5, 6; HUXLEY, Elem. p. 198, figs. 79, 80) the trabeculæ are entirely involved in the skull and nasal sacs, so that the front part is short and transverse as in the Frog. The labial plate was broken up into two rays on each side above, and one below. But the things

of interest are the large size of the pterygo-palatine band, the abortion of the first post-stomal arch down to the giving off of the pterygoid (MÜLLER, *a*; HUXLEY, *h*), the immense Meckelian bars, and the equally immense "hyo-mandibular," which ends abruptly at the point where the lower half of the bar bent backwards, to be segmented off as the free hyoid crus (HUXLEY, fig. 80, *g*, *Hy*). The suspensorial part of the palatine rolls freely on the prefrontal part of the trabecula; and it sends forth a large "prepalatal" projection, like that of the Frog, but much larger.

In the Skate (*Raia*) the trabecular horns, after they have coalesced, give off a long "prenasal" or snout-cartilage, as in the Bird; in the Sharks, as a rule, there are besides this an additional pair growing from the nasal walls, and converging in front to the tip of the azygous rod, to form the skeleton of the "breakwater."

The metapterygoid region of the mandibular arch is not always absorbed; in *Narcine* (MÜLLER, *op. cit.* pl. 5. figs. 3, 4) a slender *f*-shaped free metapterygoid exists above the pterygo-quadrate region, and the roof of the palate has in it a pair of *free* cartilages. Here the upper labials are single on each side* above and below.

My third stage well illustrates the "placoid" type of skull, especially if we suppose the metapterygoid to be either aborted or segmented off (see Plate IV. fig. 7, and Plate X. fig. 13). If this stage be examined, it will be seen that the tops of the trabecular and mandibular bars are as yet unconformed to the membranous brain-sac: compare this state of things with what is seen in *Carcharius* (HUXLEY and HAWKINS'S Atlas, plate 5. fig. 4), where a bowed band of cartilage grows out behind the optic foramen, and regains the skull in front of the hyo-mandibular. Here, I doubt not, the upper free ends of the two foremost facial bars had coalesced by a "connective," and had passed into the "investing mass" behind; the trabecular bar then grew inwards to form the subcranial beam, whilst a large portion of the second bar became absorbed, leaving only the quadrate angle with its huge forthstanding pterygo-palatine in front, and having the equally large Meckelian segment articulated to it below.

4. *With the Skull of the Sturgeon and Spatularia.*—In *Spatularia* (MÜLLER, *op. cit.* pl. 5. fig. 7; HUXLEY, Elem. p. 202, fig. 81) the palatine freely moves on the prefrontal region of the highly modified "trabecula," and the metapterygoid region is wholly absorbed, as in the generality of the Placoids. But the second postoral arch is divided in a new manner. The entire bar is divided into three main portions, namely:—a "suprahyomandibular," which is very large; then a shorter piece, which is the infrahyomandibular and "symplectic" in one; and then the free "hyoid cornu" (MÜLLER, *op. cit.* pl. 5. fig. 8, *d*, *f*, *h*). The projecting lower end of the "suprahyomandibular" is the "opercular lobe," and carries the fan-shaped radiating "opercular."

On the whole the Sturgeon agrees with *Spatularia*; but there are important differences. I cannot find space to describe the immense but quite intelligible modification of the trabecular bands (MÜLLER, *op. cit.* pl. 9. fig. 10). The pterygo-palatal con-

* These two pairs of cartilages appear to correspond to the azygous lozenge-shaped piece in the Sturgeon (MÜLLER, pl. 9. figs. 10 & 11 A, *b*).

nective (*ce*) is wholly loosened from the prefrontal region and runs back into the severed quadrate angle, below which is articulated the short, thick Meckelian rod (*p*). But above the severed quadrato-ptyergoid there is, not as in *Narcine*, two pairs of cartilages, but one lozenge-shaped piece (*b*), evidently the two "metapterygoids" in one. This marvellously metamorphosed mandibular arch is followed by a most massive hyoidean apparatus, the result of segmentation and overgrowth of the second postoral bar. The little "suprahyomandibular" of the Frog is here represented by a thick rib of cartilage having an ectosteal sheath near its upper condyle (MÜLLER, fig. 10, M', M, N; HUXLEY, *f, g*; HUXLEY and HAWKINS, pl. 5. fig. 3^b). The broad unossified part carries the "opercular" behind, and, below, ends in a round condyle, which is tied to the cup on the top of the next segment. This shorter but equally massive piece is invested with bone, and has articulating with it, behind, a nodule of cartilage; this is above the middle, and separates the "infrahyomandibular" and "symplectic" regions; it is the "stylo-hyal" (see the figs. in OWEN'S Lect. Comp. Anat. vol. ii. p. 131, fig. 43, *between* Nos. 28 & 40). To the stylo-hyal is articulated the shortish, partly ossified, inferiorly segmented cerato-hyal. (OWEN, *ut supra*, No. 40; HUXLEY and HAWKINS'S Atlas, pl. 5. fig. 3^b, *Hy*).

Here, in the Sturgeon, apparently for the first time, that segment is found in the second postoral bar which answers to the Mammalian "incus;" *its prototype* is the Sturgeon's "suprahyomandibular."

5. *With the Skull of Lepidosiren*.—Save for the addition of bony investing plates, the skull in this type answers very closely to that of the Chimæroids (see HUXLEY, Elem. pp. 207–210, figs. 84, 85). There is the same filling-in of the gaping space between the first two bars by the "pterygo-palatine connective;" and the piers of the first two postorals are entirely confluent; the Meckelian and hyoidean rods are similarly free. I find a pair of oval upper labials attached to a short azygous "snout-cartilage" ("prenasal").

6. *With the Skull of Teleostean Fishes*.—As I hope to make the Teleostean my next subject, I shall merely refer to what Professor HUXLEY has done with regard to the structure of the skull in very young *Gasterosteii*. In his earliest stage (Croon. Lect. p. 29, fig. 8, left-hand figure, and Elem. p. 185, fig. 72 A.) the trabeculæ, investing mass, and auditory sacs have become confluent, the commissure, which is the foundation of the ethmoid, is complete, and from this conjoined part of the trabeculæ there proceed a pair of short emarginate "cornua trabeculæ." The first postoral bar (mandibular), instead of attaching its free, rounded, upper end to the trabeculæ and investing mass, has retained its freedom, and has somewhat descended from the skull.

The auditory sac has grown over the top of the second postoral; and it has expanded into a pedate form above, to embrace the sac *antero-externally*. MECKEL'S rod, not shown in this figure, has been differentiated from the quadrate end of the mandibular arch, which has sent forward a triangular pterygo-palatine "connective," the apex of which touches the prefrontal region of the "trabecula."

Let this stage be compared with my third (Plate IV. fig. 7, and Plate X. fig. 13), and

it will be seen that, whilst the first and second postorals are similarly distinct, yet there is a great difference between the Fish and the Frog. In the Fish the second postoral not only *diverges*, it also *bifurcates*, an anterior slender fork passing down close behind the preceding bar in front of the gaping space (*Sy.*), and a posterior stout fork passes behind this space (*Hy.*); the slender "symplectic" fork ossifies separately (Elem. fig. 72, B, C, *Sy.*); another bony sheath encloses the broad-topped upper piece, "hyo-mandibular" (*H.M.*); the top of the diverging bar becomes segmented off and ossified as the "stylo-hyal;" and the remainder becomes a thick rib of bone, from which a distal segment is cut clean off as the "hypohyal." Both this latter and the larger piece are ossified by two centres each. Above the process which becomes the "stylo-hyal" there is a knob, the "opercular process," the part which becomes the "extrastapedial" of the Frog. The synchondrosis between the "hyo-mandibular" and the symplectic of the Teleostean Fish does not correspond with the joint-cavity which *passes through* the "hyo-mandibular" itself in the Sturgeon and the Frog.

The symplectic is a mere rudiment in my third stage of the Frog, but it develops more afterwards; it is persistently free from the quadrate in most Teleosteans, but early coalesces with that part in the Eels (e.g. *Anguilla acutirostris*): in these Fishes the pterygo-palatine connective is early aborted, and is feebly indicated in very young individuals by a delicate rod of ossified membrane, the "pterygo-palatine" bone.

C. Comparison of the Frog's Skull with that of the Urodelous Amphibia.

These lower forms of Amphibia lie between *Lepidosiren* and the "Anura." They agree largely with the former; but the pterygo-palatine cartilage is very much aborted, as in the Eel. There is a "stapes;" but there is no metamorphosis of the top of the hyoidean bar to form any secondary elements to the "middle ear."

D. Comparison of the Frog's Skull and Face with that of the "Sauropsida."

1. *With the Reptilia.*—This comparison has been in some degree anticipated by my use of Professor HUXLEY'S terms, as given in his paper on the prototypes of the Malleus and Incus (Zool. Proc. 1869).

My first and second stages throw an unexpected light on the *hyo-stapedial* structures of *Sphenodon* (*op. cit.* p. 397, fig. 4). The second postoral of this Lizard has coalesced and retained its coalescence with the auditory mass. It has not segmented itself into upper, middle, and lower parts, but the "supra-" and "infrahyomandibular" regions are permanently continuous with each other and with the "stylo-cerato-hyal." The semicircular scooped "extrastapedial" (*E.St*) is the "opercular process;" and from this there grows backwards a "medio-stapedial" bar, which is continuous with the cartilage that is ossified to form the columelliform rod of the "stapes:" here the stapedial plate early formed a union, by means of a *secondary connective bar*, with the continuous (unsegmented) hyoid arch.

With regard to the "pterygo-palatine connective," it may be remarked that the Reptilia develop but little cartilage, and that of a very simple type, in this region; it is

almost entirely formed of membrane, and then afterwards of membrane bones. Where, as in Chelonians, and especially Lacertians, something more solid is early developed, it soon ossifies, and becomes curiously modified as the "epipterygoidean columella." Not only the Reptilian group, generally, but the Lacertilians themselves, vary in their facial structures much more than the so-called Bird-Class; three of the "Families" may suffice for illustration. In the "Varanians" (e. g. *Psammosaurus*) the long outgrowth of the stapes is only differentiated from the top of the second postoral by stoppage of ossification, as in the Crocodile and *Sphenodon*; its *stapedius* muscle sends its tendon through the two forks of the "suprastapedial" to the end of the spatulate "extrastapedial;" and the cartilage sends down an "infrastapedial" close in front of the stapedial shaft. The long, flexible stylo-hyal is free as in the newly metamorphosed Frog, and articulates with the cerato-hyal below (HUXLEY and HAWKINS, "Atlas," pl. 8. fig. 15, *b*). Here the Ichthyic and Batrachian structures are but thinly veiled.

In the Chameleons (*C. vulgaris*) the "membrana tympani" is abortively developed; there is no "fenestra rotunda," and the stapedial connective *articulates* with the top of the second postoral, a joint-cavity intervening between it and the "medio-stapedial" process. Nearly all the suprastapedial is reduced to membrane; there is no distinction between the extra- and the infrastapedial regions.

In the Cyclodonts (*Cyclodus nigro-luteus*, and *Trachydosaurus rugosus*) there is a "fenestra rotunda;" but the "membrana tympani" is a mere band, as in *Sphenodon*. Here the unossified end of the stapedial shaft is bulbous, and is loosely attached to a feeble unossified "hyo-mandibular," which ends above in a very short, rounded "suprastapedial" process; a feeble aculeate "extrastapedial," grows from its side, and it ends below in a bluntly styloid "infrastapedial." These types are introduced to illustrate what I have said of "secondary connectives;" in the Crocodile, *Sphenodon*, and Monitor the stapes passes into the hyoid pier just as the quadrate region of the second facial bar passes into the prefrontal region of the first in the Frog.

In the Chameleon and Cyclodont the stapes sends forwards the "connective," which, however, does not pass into the hyoid, just like the pterygo-palatine connective of most of the Orders of the Fish-class.

2. *With the Skull and Face of Birds.*—The parts under especial consideration are described by Professor HUXLEY in his above-cited paper (pp. 398, 399); but I cannot agree with one expression—namely, that the "suprastapedial" is represented *only* by fibrous tissue; I would say *principally*.

The broad bent end of the infrastapedial (*op. cit.* fig. 5, *I.S*) is not unfrequently ossified, and much more developed than in the Fowl; this bony centre is not segmented off, and yet it is evidently the stylo-hyal; it is hatchet-shaped in *Gymnorhina tibicen*, spatulate in *Fruticicola rubetra*, and styloid in *Sula alba*.

In my last paper (Philosophical Transactions, 1869, pp. 755–807, Plate LXXXI.–LXXXVII.) I have not worked out the relation of the stapes to the hyoid arch in the first stage. In the second (Plate LXXXI. figs 5 & 9) the stapedial plate is already continuous with the aborted hyoid pier: that rudiment has already three processes, the first appearance of the

“supra-,” “extra-,” and “infrastapedials.” At page 759 I have said of the “trabecular horns” that they “do not coalesce to form the intermaxillary axis or “prenasal cartilage.” This is quite true; for the cornua have coalesced before that rod is developed. I did not, however, get a full insight into the formation of the nasal labyrinth from my researches into the structure of the Chick; the huge Tadpole of *Pseudis paradoxa* gave me the true insight. I here make correction of my imperfect and somewhat erroneous description of my first stage (Plate LXXXI. figs. 1, 2, p. 759).

The “first stage” in the Fowl answers to the third in the Frog-embryo, so that the parts are already highly modified. The first pair of visceral arches (trabeculæ, *tr.*) are by the “meso-cephalic flexure” bent over and backwards into the shape of hooks, so that two-thirds are seen above (fig. 2) and one-third below (fig. 1). The apex of each bar is seen projecting outwards at the part where it has coalesced with the investing mass (*i.v.*); this free apex becomes the “lingula” (Plate LXXXII. fig. 3, *l.g.*). In front of the oval pituitary space a large “commissure” has tied the two bars together for a large space, part of which can be seen from below (fig. 1); in this aspect we see the free “cornua” which have grown into the “naso-frontal process” (*f.n.*) from the conjugated part of these bars.

The pituitary space (*py.*) soon shortens, and the commissural region rapidly lengthens; the trabeculæ, themselves thus united, form the thick base of a large crest, which intervenes (fig. 3, *eth., p.s.*) between them and the floor of the membranous cranium; this secondary crest is the “orbito-nasal septum;” and the roof of the nasal sacs grows from its top. The first visceral arch has become widely divergent from the second; and between them an arcuate “connective” (“pterygo-palatine,” *pa., p.g.*) has appeared; it is very slightly connected with either bar, and scarcely undergoes chondrification. The first, second, and third visceral bars neither coalesce with each other nor with the auditory sac.

E. Comparison of the Frog with the Mammal.

If the figures given by Professor HUXLEY (Elem. p. 143) from ECKER’S work be compared with my earliest stages, the complete correspondence will at once be seen between the human embryo and that of the Frog.

The “maxillary process” (*a*) seems, as in the Bird (*op. cit.* p. 139, fig. 57, F, *l*), to be a small additional arch, but it does not chondrify, and is merely a *process* of the second or mandibular bar, and is developed into the palatine, pterygoid, maxillary, and malar bones.

From the middle of the “sella turcica” to the end of the nasal septum, the cranio-facial base is formed of the first (trabecular) pair of arches; and if the reader would see what these minute threads of soft cartilage may become by metamorphosis and growth, he should consult the posthumous work of Dr. ESCHRICHT on the Anatomy of the Cetacea, which has recently appeared under the editorship of Dr. REINHARDT* (plate 2 showing the primordial skull of *Balaena japonica*).

* “Ni Tavler til Oplysning af Hvaldyrenes Bygning, udførte til utrykte Foredrag af afdøde Etatsraad Dr. D. F. ESCHRICHT. Med tilhørende Forklaring.” Copenhagen, 1869.

The space between the true cranial sac and the trabecular undergirders, which in the Lamprey (MÜLLER, *op. cit.* pl. 4. figs. 1, 3, 9, 10) permits the passage backwards of the azygous nasal pouch (fig. 1, *h''*), reappears by a sort of retrograde metamorphosis in the Mammal; here the pouch, or rather air-cavity, is common to two symmetrical nasal sacs, and not to an azygous sac as in the Lamprey. In the Aye-Aye (OWEN, *Trans. Zool. Soc.* 1863, pl. 20. fig. 6, *q*) this air-sac completely divides the proper cranial floor from its trabecular addition, up to the very point at which the trabeculæ became confluent with the investing mass in the early embryo. Another return to embryonic conditions is well seen in the complete separation of the "pars petrosa" from the sphenoidal and occipital regions of the skull; this is most exquisitely seen in *Scotophilus pipistrellus*.

In Mammalia the second visceral arch (mandibular) never undergoes segmentation above; the upper part of the head of the malleus answers to the "quadrate" (HUXLEY, "Malleus and Incus," p. 402, fig. 6, *M*), the rest of the head to the articular region, and the processus gracilis to the Meckelian bar*. The "articular" region gives off a manubrium similar to the "opercular process" of the "hyo-mandibular" ("extrastapedial"); and this serves the same purpose, namely to stretch the tympanic membrane.

The third bar (second "postoral") becomes very much subdivided; its segments are well shown in Professor HUXLEY'S figure. The upper part of the first postoral cleft is converted into the joint-cavity between the "malleus and incus;" the rest forms the tympanic cavity and Eustachian tube. The "suprastapedial" region is here represented by the head and "short crus" of the incus, the "medio-stapedial" by the "long crus," the "interstapedial" by the "os orbiculare;" there is no extrastapedial.

The remainder of the hyo-mandibular region or upper half of the primary bar is a small "infrastapedial" ("infrahyomandibular") rod (*a*), which runs parallel with the tendon of the "stapedius" muscle. The stylo-hyal" (*st.h*) is separated from this little rod, from the lower end of which it was segmented at an earlier period (Mr. HUXLEY'S figure is from a fœtus five months old); these segments are now separated by nearly all the length of the belly of the "stapedius."

The decurved and transverse position of the infrastapedial is evidently due to the *upward* movement of the freed "stylo-hyal;" most of the tissue of the bent and broken part of this visceral arch has been converted into the tendon and belly of the "stapedius." The head of the stylo-hyal, overgrowing the bent portion above it, has ascended to the "opisthotic" region, and has completely coalesced with it as in the Common Toad; this is a coalescence of two cartilaginous tracts totally unrelated morphologically.

In the Mole (*Talpa europæa*) the part of the malleus articulating with the incus is half severed from the rest, forming an upper *quadrate* lobe; the "short crus" of the incus is very feeble. A similar well-marked quadrate lobe is seen in the Shrew (*Sorex tetragonurus*); and it has a still smaller "short crus" to the incus; the "orbiculare" is, relatively, nearly as large as in the Frog.

* The fore part of the Meckelian rod is ossified separately as the "inferior intermaxillary rudiment" (see CALLENDER, *Philosophical Transactions*, 1869, Plate XIII. fig. 6, *a*, p. 170); there the Batrachian structure is repeated; the same "mento-meckelian" ossicle may be seen in old Sturgeons.

Concluding Remarks.

The foregoing comparisons are given under the impression that they may be of some immediate use to the student, although they must be given on a larger scale after several more types have been worked out.

Moreover it is no little relief to the worker himself thus to be able to rise from a task which has used the leisure of well nigh two years; such an expatiation is necessary before the renewal of a similarly persistent concentration to new work of the same kind. He contends, also, that the mind both of the reader and the writer will be strengthened as well as refreshed by a wider view, and that each separate type will then be seen in the light of many other types. Indeed thus alone will it be possible to obtain broad views in vertebrate morphology, "as a man conveniently placed in some eminent station may possibly see, at one view, all the successive parts of a gliding stream; but he that sits by the water's side, not changing his place, sees the same parts only because they succeed, and those that pass make way for them that follow to come under his eye."

I must confess to having subjected myself to this mole-like burrowing into so limited a territory that I may obtain fresh material for ratiocination—"that way of attaining the knowledge of things, by comparing one thing with another, considering their mutual relations, connexions, dependencies, and so arguing out what was more doubtful and obscure, from what was more known and evident."

To have worked out one single species in this way may seem to be but like the forming of a single track in a primæval forest; yet when well cleared, so perfect is the unity of each subkingdom, by such a narrow path the worker is "regularly led on through the labyrinths of Nature, when still new discoveries are successfully made, every further inquiry ending in a further prospect, and every new scene of things entertaining the mind with fresh delight." Leaving for a while the suggestive morphology of the Frog, it may be worth while for the palæontologist to reflect upon the empty spaces in the great vertebrate circle which are darkly but really revealed by what is seen in both the earliest and the latest stages of the Frog.

Territories vacant, but larger far than those now occupied by family after family, and order after order, have been suggested to me by my long attention to the growth of the skull and face in this Amphibian.

Empty spaces of almost indefinite extent seem, to my mind, to stretch themselves *below* the Myxinoid prototypes of the Batrachia, and *above and beyond* the Frogs and Toads, in the direction of the Mammalia.

This last space is wholly undefined, and no light has yet penetrated its deep abyss, in which lie buried the fundamental Mammalian types. The lowest Mammals known to us, the Platypus and the Echidna, may be fundamental to the Edentata; they are not, they cannot be, to the Marsupials, the Insectivora, and the Rodentia.

Between the Monotremes and the Batrachia we certainly have the Sauropsida—Reptiles, and Birds; but I am bold to say that no Sauropsidan lies in a direct line between, forms any part of a *phylum* which should connect together, the nobler Amphibian forms

and the lowest Mammal. On the Mammalian side of this empty space we must suppose a form which should be general to the whole class; I need not say that no such form is extant. The extraordinary and unlooked-for morphological elevation of the adult "Anuran," an elevation in very important structures attained by no Reptile or Bird, and which brings it almost into contact at certain points with the Mammalian margin, is very suggestive. Such a discovery sheds a certain but feeble light, useful though faint.

The fact that the higher Batrachia go on metamorphosing until several of their structures are so perfect as to require but the gentlest modification to make them fit for the Mammal, does not require one to suppose that the Toad and the Frog lie in the direct route from the Ichthyic to the Mammalian types. That such power of variation, such aptitude for transformation exists in these essential but metamorphic Fish, suggests the probability that some of the very earliest of the Amphibia, filial perhaps to forms far lower than the Lamprey, did not stop at the last metamorphic stage of an Anuran, but changed still further, and thus laid the foundation of the higher classes.

The formation of the *amnion* and the *allantois* in the early stage of an embryo may have been a *sudden variation*; when once developed, however, the essentials were present for the development of a *Reptile* ("Sauropsidan") as distinct from a mere Amphibian.

We are all looking for further traces of the *phylum* which shall complete the connexion between the cold-blooded, scaly types of "Sauropsida" and the feathered, warm-blooded Birds; even should this never be attained to, yet no one will doubt that it has existed.

An Amphibian, full of latent power of change, need not have taken in its metamorphosis merely the path that leads to the Reptile and the Bird; for the least deflection at first may have sufficed to bring about all the differences which now, in this late, *human* period, we see between the Mammal and the Bird. These warm-blooded groups are huge culminating branches of the tree of Vertebrate life; yet it is not a wild fancy to suppose that they may once have existed together in the same common trunk.

So much for the vacant space *above* the Myxinoids; the *lower* is much larger and even more pathless.

The lowest existing Fish but one is the "Myxinoid" (Lamprey, Hag, *Bdellostoma*); between it and the lowest known Vertebrate, the Lancelet (*Amphioxus*), there is a gap the extent of which has never been imagined; and yet even the Lancelet itself is not necessarily the actual boundary form.

I have shown in my comparisons that the larval Lamprey (*Ammocætes*) is only a little lower than my third stage of the Frog, whilst my fourth stage answers very closely to the adult Lamprey.

Let us imagine three families of extinct Fishes *below* the Lamprey:—first, a group arrested *as to type* at the Ammocæte stage; secondly, a group which may be morphologically represented by my second stage of the Batrachian embryo; and thirdly, a group no higher than my first stage.

These three "Families" may have abounded in genera and species, and have been as

perfectly in harmony with their surroundings as the highly specialized and noble Ganoid Fishes. How far these groups would tend to fill up the space between the *Amphioxus* and the simplest of their species, I need not say. Every anatomist will at once see that a creature no higher in type than the unhatched embryo of the Frog is yet an untold distance in advance of the Lancelet, which yet is only the *known lowest* of the great Vertebrate subkingdom.

My next subject will be the Salmon, a subtypical "Teleostean;" after that I hope to work out one of the lowest of the placental Mammalia, namely the Guinea-pig.

The present paper has thrown some light upon the obscurer early stages of my last subject, the Fowl; this I have spoken of in the comparisons which have been made of the various types.

Meantime, if any one desires to earn the lasting gratitude of morphologists, let him work out the development of a "Myxinoid," a Lamprey, or, still better, the *Bdellostoma* (see MÜLLER'S "Myxinoids," pls. 1, 2, 3, 6, 7, 8). In the last type, especially, the labial cartilages, the facial cartilages and branchial "basket," the axial structures, and the sense-capsules—these might all receive the most beautiful and invaluable elucidations if the early stages were known of a creature so low in the scale and yet at the same time so intensely specialized and modified from its primordial condition. It is impossible for us not to search after the types that arose above the Lancelet; and although they are most probably *nearly all extinct*, yet a clear comprehension of the stages of a *Bdellostoma* would give us pictures, diagrammatic indeed, but essentially true representatives of whole groups of lost "Families" of the simpler types of Fish.

This would be a new joy to the zoologist; but to the morphologist it would be as a lamp, giving the light of a new life to his science; and then would he be willing to break up his last idol, the mere creation of a fanciful transcendentalism, reasoning henceforth about the actual forms presented to him by Nature herself.

EXPLANATION OF ABBREVIATIONS.

- al.n.* alinasal.
al.s. aliseptal.
al.s. alisphenoid.
ar. articular.
ar.c. articular condyle.
a.sc. anterior semicircular canal.
au. auditory sac (periotic mass).
a.t. annulus tympanicus.
atl. atlas.
b.br. basibranchial.
b.h. basihyal.
b.t. basitemporal processes.
br. branchial arch.
ct. cutaneous system.
c.a.t. cartilaginous annulus tympanicus.
c.br. cerato-branchial.
cl. 1. 1st cleft.
c.p. claspers.
C 1. 1st cerebral vesicle.
C 1^a. rhinencephalon.
C 1^b. prosencephalon.
C 1^c. deutencephalon.
C 2. mesencephalon, or middle cerebral vesicle.
C 3. 3rd cerebral vesicle.
cr. cranium.
c.tr. cornu trabeculæ.
d. dentary.
dr. derm.
e. eyeball.
e.br. epibranchial.
e.bra. external branchiæ.
e.n. external nostril.
ep. epiotic.
e.pa. ethmo-palatal.
e.st. extrastapedial.
eth. ethmoid.
f. frontal
f.f. fenestral fossa.
f.m. facial muscle.
f.m.x. facial plate of maxillary.
f.n. fronto-nasal process.
fo. fontanelle.
f.r. fenestra rotunda.
f.s.o. fenestra ovalis.
f.w. facial wall.
- g.l.t.* gelatinous tissue.
h.br. hypobranchial.
h.c. hyaline cartilage.
h.h. hypohyal.
h.m. hyo-mandibular.
h.sc. horizontal semicircular canal.
hy. hyoid.
hy.h. hypohyal.
i.br. internal branchiæ.
i.f.st. infrastapedial.
i.h.m. infra-hyomandibular.
i.n. internal nostril.
inf. infundibulum.
it.st. interstapedial.
iv. investing mass.
iv.c. investing-mass connective.
i.v.p. inner valvular process.
l. labyrinth.
l.d.g. lower dentigerous plate.
l.l. lower labial.
lp. lips.
l.t. labial teeth.
lx. larynx.
m. mouth.
m.c. membranous cranium.
m.d. digastric muscle.
mk. MECKEL'S cartilage.
m.mk. mento-meckelian.
m.ob. medulla oblongata.
m.p.g. metapterygoid.
m.p.g.c. metapterygoid connective.
m.s. medulla spinalis.
m.x. maxillary.
n. nasal.
nc. notochord.
no. notch.
n.p.x. nasal process of premaxillary.
o.c. occipital condyles.
ol. olfactory sac, or tube.
o.l. C 2. optic lobes.
op. opisthotic.
op.m. operculum.
op.o. opercular opening.
op.p. opercular process.
or.p. orbital process.

- o.s.* orbito-sphenoid.
ot. otoliths, or otoconia.
p. parietal.
pa. palatal.
pa.s. parasphenoid.
p.b.c.f. posterior basicranial fontanelle.
p.br. pharyngo-branchial.
p.c.d. pericardium.
p.e. perpendicular ethmoid.
p.fo. posterior fontanelle.
p.g. pterygoid.
pg.p. pterygo-palatine.
phx. pharynx.
p.mx. premaxillary.
p.op. præoperculum.
p.p.p. pterygo-palatal process.
p.p.x. palatal process of premaxillary.
pr.f. prefrontal.
pr.hm. prehyomandibular.
pr.m. promontory.
pro. prootic.
pr.pa. prepalatal.
p.s. presphenoid.
p.sc. posterior semicircular canal.
pt.o. pterotic.
pt.hm. posthyomandibular.
p.t.o. postorbital.
pt.pa. postpalatal.
py. pituitary space.
q. quadrate.
r. rostrum of parasphenoid.
s.c. simple cartilage.
s.hm. suprahyomandibular.
s.m.v. septo-maxillary.
s.n. septum nasi.
sn.c. snout-cartilage.
s.n.l. subnasal lamina.
s.o.f. subocular fenestra.
sp. suspensorium.
s.st. suprastapedial.
st. stapedial.
s.t. supratemporal.
st.f. stapedial fossa.
st.h. stylo-hyal.
su.s. suprasphenoidal.
sy. symplectic.
t. temporal bone.
tg. tongue.
th. thyro-hyal.
th.v. theca vertebralis.
t.m. temporal muscle.
tr. trabecula cranii.
t.c. trabecular commissure.
t.s.l. transeptal lamina.
t.ty. tegmen tympani.
u.d.g. upper dentigerous plate.
u.l. upper labial.
vb. vestibule.
v.e.n. valvular process of external nostril.
v.i.n. valvular process of internal nostril.
y. yelk.
z.m.x. zygomatic process of maxillary.
 1. olfactory nerve.
 2. optic nerve.
 5. trigeminal nerve.
 7^a. portio-dura nerve.
 7^b. portio-mollis nerve.
 8^a. glosso-pharyngeal nerve.
 8^b. vagus nerve.

DESCRIPTION OF THE PLATES*.

PLATE III.

First Stage.—*Embryo of Frog 2-3 lines long; two days before and two days after hatching.*

- Fig. 1. Front view of head before hatching. $\times 20$ diameters.
 Fig. 2. Side view of the same, with ear-sac exposed. $\times 20$ diameters.
 Fig. 3. Same as last, with facial arches, as well as ear-sacs, exposed. $\times 20$ diameters.
 Fig. 4. Vertical section of head of the same. $\times 20$ diameters.
 Fig. 5. Horizontal section of the same, immediately below the cranial cavity. $\times 20$ diameters.
 Fig. 6. A similar section taken a little lower down. $\times 20$ diameters.
 Fig. 7. Another similar section, still lower down, and showing the floor of the mouth. $\times 20$ diameters.
 Fig. 8. A transversely vertical section of fore part of face, seen from behind. $\times 20$ diameters.
 Fig. 9. A section, like fig. 5, of a more developed embryo (3 lines long). $\times 15$ diameters.

Second Stage.—*Embryos 4 lines long, four or five days after hatching.*

- Fig. 10. Side view of head. $\times 20$ diameters.
 Fig. 11. Under view of the same. $\times 20$ diameters.
 Fig. 12. Vertical section of the same. $\times 20$ diameters.
 Fig. 13. Fore part of horizontal section of the same, from below, and showing the palate and inner nares. $\times 20$ diameters.

PLATE IV.

Second Stage (continued).

- Fig. 1. Side view of head with sensory organs and facial arches exposed. $\times 20$ diameters.
 Fig. 2. Horizontal section of head through eyeballs, ear-sacs, brain, and notochord. $\times 20$ diameters.
 Fig. 3. Another horizontal section, dipping a little backwards, so as to expose the yolk-sac, below the notochord. $\times 20$ diameters.

* The hyaline cartilage, whether totally unossified or slightly affected by "endostosis," is coloured lilac, the endostosis being shown by a coarser marking than in that which is wholly unossified. The more solid bones, including all true "ectostoses," are coloured ochre-yellow, whilst the "parostoses" and fibrous membranes are not tinted.

- Fig. 4. A similar section, in which the dip is forwards, so as to be below the eye and through the notochord and pituitary body and ear-sacs. $\times 20$ diameters.
- Fig. 5. A horizontal section below the brain and through all the facial arches and the end of the notochord: the pituitary body is indicated by dotted lines. $\times 20$ diameters.
- Fig. 6. Horizontal section of head, through eyes, ear-sacs, brain, and notochord. $\times 20$ diameters.

Third Stage.—Young Tadpoles 5 lines long.

- Fig. 7. Lateral view of head, with eyes removed, and nasal and auditory sacs and facial cartilages exposed. $\times 20$ diameters.
- Fig. 8. Vertical section of head, showing brain, notochord, oral cavity, and heart. $\times 20$ diameters.
- Fig. 9. A *dissected* horizontal section, showing basis cranii from above; with eyeballs, ear-sacs, upper labial cartilage, and part of oral cavity. $\times 20$ diameters.
- Fig. 10. A similar *dissected* section seen from below, and showing the openings of the nasal sacs into the fore part of the palate immediately in front of the pterygo-palatine connectives. $\times 20$ diameters.
- Fig. 11. Horizontal section through the facial arches and upper lip of a somewhat more advanced Tadpole, showing the floor of the mouth and its opening. $\times 20$ diameters.
- Fig. 12. A similar section lower down; here the mucous membrane has been removed, and with it the tongue and lips. $\times 20$ diameters.

PLATE V.

Fourth Stage.—Tadpoles 1 inch long.

- Fig. 1. Side view of head and part of trunk of Tadpole with first appearance of hind limbs, as far as to the left (or azygous) opercular opening. The skin has been removed, and the parts so dissected as to display the cerebral masses and sense-capsules, skull, face, and branchial arches. The hyoid and branchial arches are somewhat drawn downwards for display. $\times 14$ diameters.
- Fig. 1^a. Upper part of branchial arches. $\times 30$ diameters.
- Fig. 2. A vertical section of the same as fig. 1, showing the right side from within. $\times 15$ diameters.
- Fig. 3. Upper view of skull and face of Tadpole somewhat more advanced, so dissected as to display the fundus of the cranium and the cavity of the ear-capsule. $\times 12$ diameters.
- Fig. 4. The same as fig. 3, but shown from below. $\times 12$ diameters.
- Fig. 5. Lower view of skull, face, and branchial arches of younger Tadpole (same as figs. 1 & 2): the outer "branchiæ" have been removed, and the dentate elevations from which the inner filaments grow are displayed. $\times 14$ diameters.

- Fig. 6. No. 1 of a series of vertically transverse sections through the skull and face of the younger Tadpole: this has been taken in front of the mouth, and is seen from behind. $\times 15$ diameters.
- Fig. 6^a. Part of the same, being the thin edge of the upper labial cartilage. $\times 200$ diameters.
- Fig. 7. Section No. 7, made through the optic lobes (*o.l.*), foramina ovalia (5), and pericardium (*p.c.d.*). $\times 14$ diameters.

PLATE VI.

Fourth Stage (continued), and part of Fifth Stage.

- Fig. 1. Section No. 2, made through the fore part of the nasal sac (*n*), the mouth, the ends of MECKEL'S cartilages (*m.k.*), and through the substance of the "inferior labials" (*l.l.*). $\times 14$ diameters.
- Fig. 2. Section No. 3, made through the nasal sacs, close behind the lower labials (*l.l.*), and in front of the quadrate condyle. $\times 14$ diameters.
- Fig. 3. Section No. 4, made through the olfactory lobes (C 1^a), the quadrate condyle (*q.*), the orbitar process (*or.p.*), and *behind* the Meckelian and lower labial cartilages. $\times 14$ diameters.
- Fig. 4. Section No. 5, made through the prosencephalon (hemispheres) (C 1^b), eyeballs (*e.*), the quadrate condyle (*q.*), and the hyoid arch (*hy*). $\times 14$ diameters.
- Fig. 4^a. Part of hyoid arch, seen from behind.
- Fig. 5. Section No. 6, made through optic lobes (C 2), infundibulum (*inf.*), metapterygoid (*m.pg.*), and close in front of pericardium (*p.c.d.*) and auditory capsules (*au.*). $\times 14$ diameters.
- Fig. 6. Section No. 8, made through the medulla oblongata (*m.ob*), the middle of the auditory sac (*au.*), and behind the branchial arches. $\times 14$ diameters.
- Fig. 7. Section No. 9, made through the posterior part of auditory sac, in the occipital region, so as to cut through the epiotic eminences (*ep.*). $\times 14$ diameters.
- Fig. 8. Part of fig. 4, in Plate V., showing the metapterygoid (*m.pg.*), hyo-mandibular (*h.m.*), and auditory sac (*au.*) from below. $\times 20$ diameters.
- Fig. 9. A section of the skull in the 5th stage, showing the trabecular horns and the septum nasi, both in continuity with the front of the ethmoidal wall. $\times 30$ diameters.
- Fig. 10. Transversely vertical section of the skull in the 5th stage, a little in front of the ethmoidal wall, showing the trabecular horns distinct from the septum nasi. $\times 30$ diameters.

PLATE VII.

Fifth Stage (continued).

- Fig. 1. Side view of skull, without the branchial arches, of a Tadpole further advanced, in which the hinder legs had increased in size and the tail had begun to shrink. The dotted lines carried from the foramen ovale (5) to MÆCKEL'S cartilage (*mk.*) show the direction of the temporal ("crotaphite") muscle (*t.m.*); the hyoid arch (*hy.*) is drawn downwards for display. × 15 diameters.
- Fig. 1^a. Part of the same, showing the auditory capsule (*au.*) from the inner side. × 15 diameters.
- Fig. 2. Anterior part of cranium and cornua trabeculæ of the same, seen from above, and showing transverse ethmoidal wall, rudiment of septum nasi, and olfactory crura. × 18 diameters.

Sixth Stage.—Frogs with short tails.

- Fig. 3. Side view of skull of a young Frog which had *moulted* the larval skin so as to expose the fore limbs, and in which the tail was reduced to half its former size. The facial arches are drawn downwards for display. × 15 diameters.
- Fig. 4. Part of the same, seen from the inner side, the skull having been bisected. × 15 diameters.

Seventh Stage.—Frogs with tails absorbed.

- Fig. 5. Side view of skull of a young Frog still further advanced, completely *curtailed*, with the facial arches drawn downwards for display. × 15 diameters.
- Fig. 6. Section No. 1, made in a vertically transverse direction through the skull at this stage (7th): this shows the "alisseptal" (*al.s.*) and "subnasal" (*s.n.l.*) laminae as outgrowths of the "septum nasi" (*s.n.*). × 18 diameters.
- Fig. 7. Section No. 2, made through the hemispheres (C 1^b) and through the skull-wall at the point where the ethmoid (*eth.*) passes into the orbito-sphenoid. × 18 diameters.
- Fig. 8. Section No. 3, made through the hemispheres further backward, between the eyeballs (*e.*). × 18 diameters.
- Fig. 9. Section No. 4, made through the fore part of the optic lobes (C 2) and the infundibulum (*inf.*), behind the great fontanelle; so that the skull is here completely roofed-in with cartilage. × 18 diameters.
- Fig. 10. Section No. 5, made through the medulla oblongata (*m.ob.*) and through the middle of the auditory capsule. × 18 diameters.
- Fig. 11. Upper view of anterior half of the same skull with the membrane bones removed. × 20 diameters.
- Fig. 12. Part of fig 2, showing "suprahyomandibular" and stapedial cartilages. × 30 diameters.

- Fig. 13. Eighth Stage.—Middle-ear chain, with fenestra ovalis and part of auditory capsule, the “stapes” partly displaced. $\times 30$ diameters.
- Fig. 14. Part of middle-ear chain (9th Stage) with medio-stapedial and stapedial cut through. $\times 30$ diameters.
- Fig. 15. Section through “stapedial plate,” “fenestra ovalis,” and exoccipital and opisthotic edges of the “fenestral fossa” (old Frog). $\times 12$ diameters.
- Fig. 16. Part of the skull of an adult Frog, with stapedial plate removed to show “fenestra ovalis” and “fenestral fossa.” $\times 12$ diameters.

PLATE VIII.

Seventh Stage (continued).

- Fig. 1. Upper view of skull of young Frog with right mandible attached, and hyoid cornua cut through. $\times 12$ diameters.
- Fig. 2. The same, lower view. $\times 12$ diameters.
- Fig. 3. Part of fig. 1, suspensorium and auditory capsule. $\times 24$ diameters.
- Fig. 4. Part of fig. 2, ditto. $\times 24$ diameters.
- Fig. 5. Distal part of MECKEL'S cartilage (*mk.*) with dentary plate (*d.*) still distinct. $\times 45$ diameters.

Eighth Stage.—Frogs of 1st early Summer.

- Fig. 6. Fore part of MECKEL'S cartilage (ossified) with part of “dentary” and “articulare.” $\times 45$ diameters.

Ninth Stage.—Frogs of 1st autumn.

- Fig. 7. Upper view of skull of a young Frog examined towards the end of the 1st summer; right mandible removed. $\times 7\frac{1}{2}$ diameters.
- Fig. 7^a. Part of the same, showing right suspensorium and auditory region. $\times 15$ diameters.
- Fig. 8. The same skull, seen from below. $\times 7\frac{1}{2}$ diameters.
- Fig. 8^a. Part of fig. 8, showing lower view of suspensorium and auditory region. $\times 15$ diameters.
- Fig. 9. Tenth Stage.—Side view of auditory region of adult Frog with semicircular canals exposed and parts of middle ear displayed. $\times 7\frac{1}{2}$ diameters.
- Fig. 10. Tenth Stage.—Section showing “fenestra ovalis” and “stapedial plate” from within. $\times 12$ diameters.

PLATE IX.

Tenth Stage.—Old Frogs.

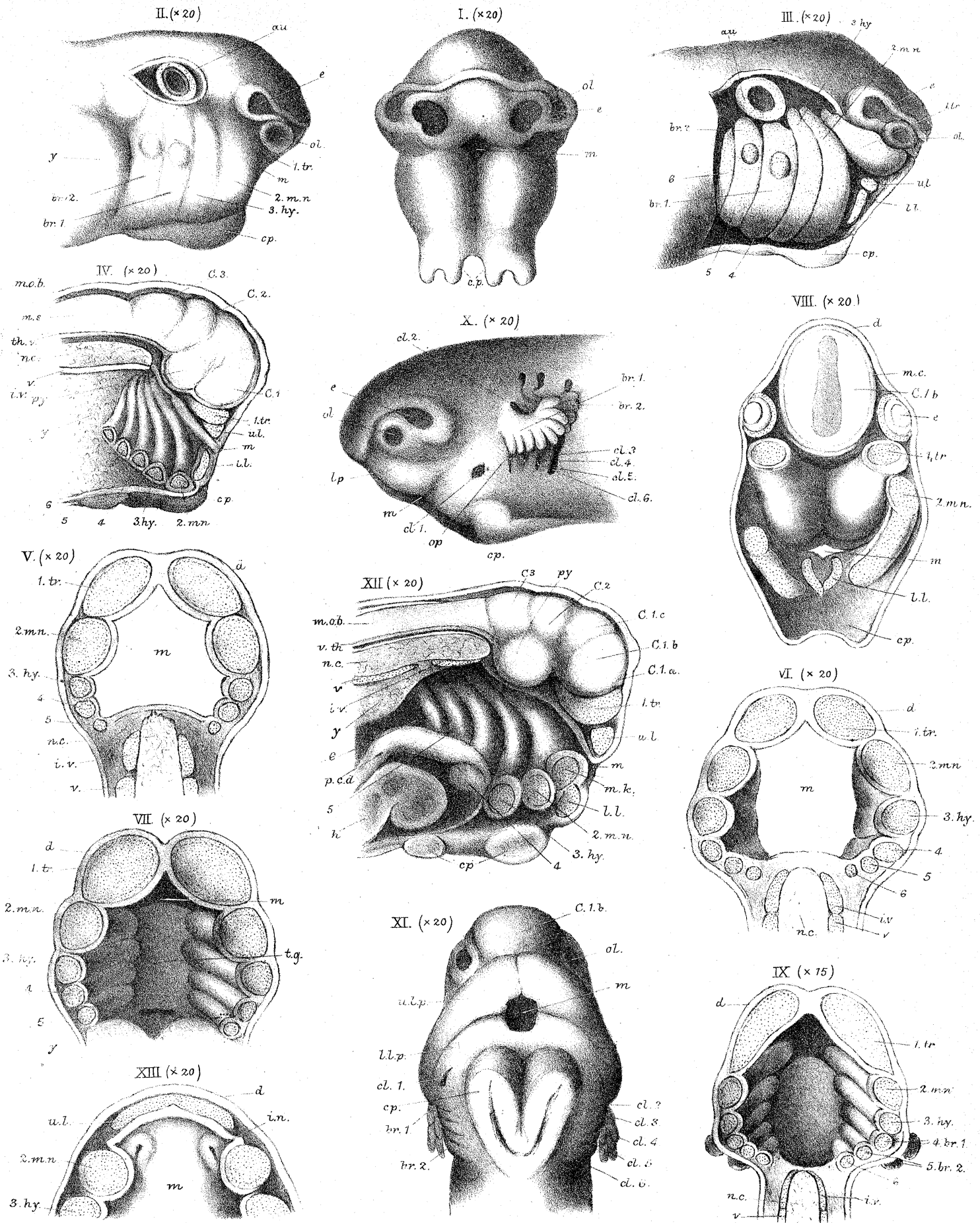
- Fig. 1. Upper view of skull of adult Frog with all the bones *in situ*. $\times 4$ diameters.
- Fig. 2. Lower view of the same. $\times 4$ diameters.

- Fig. 3. Side view of the same. $\times 4$ diameters.
 Fig. 4. End view of the same. $\times 4$ diameters.
 Fig. 5. Sectional view of the same. $\times 4$ diameters.
 Fig. 6. Upper view of skull of adult Frog from which the parosteal bones have been removed. $\times 4$ diameters.
 Fig. 7. Lower view of the same. $\times 4$ diameters.
 Fig. 8. Section through the "girdle-bone" (ethmoid), seen from behind, and showing the gentle projection answering to the "crista galli" (the end of the meso-ethmoid), and the olfactory foramina piercing the ethmoid in the middle of the rhinencephalic fossæ. $\times 12$ diameters.
 Fig. 9. Section through the hemispheres at the anterior border of the orbito-sphenoidal walls. $\times 12$ diameters.
 Fig. 10. Posterior part of floor of the skull in the 7th Stage, seen from above, and showing "posterior basicranial fontanelle" and notochord (*n.c.*). $\times 45$ diameters.

PLATE X.

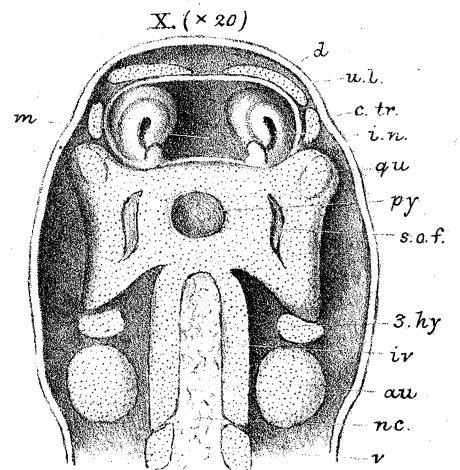
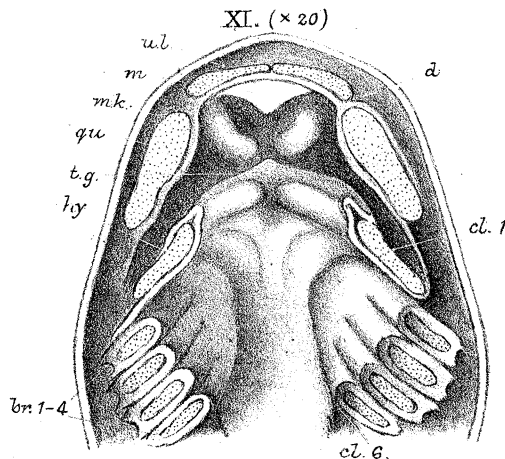
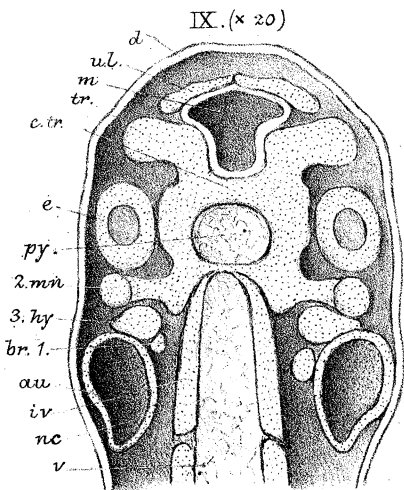
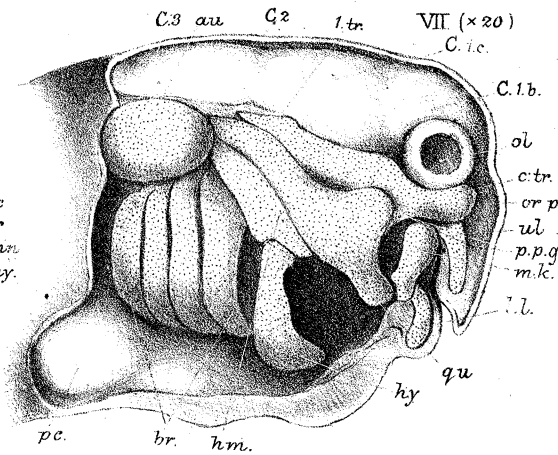
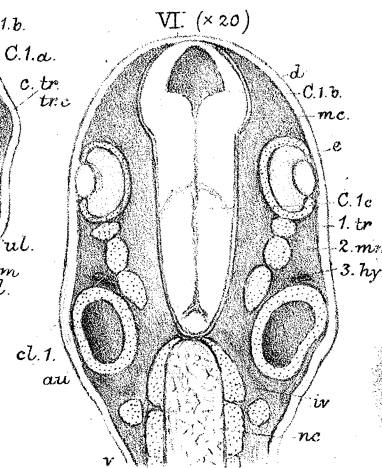
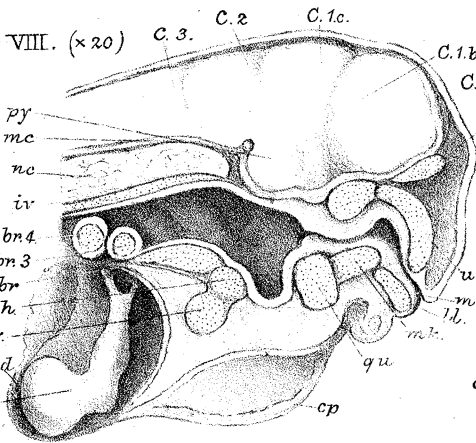
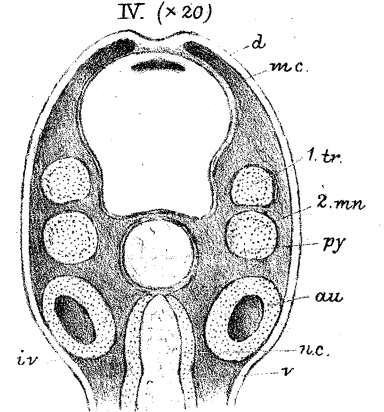
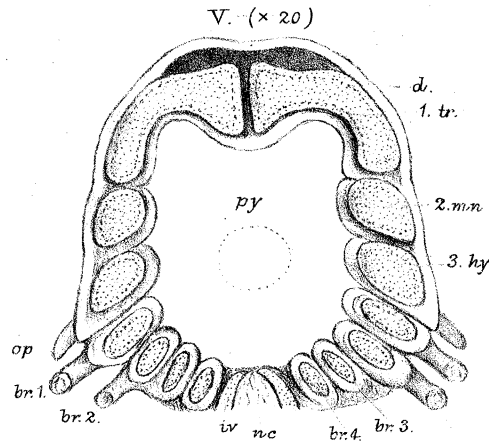
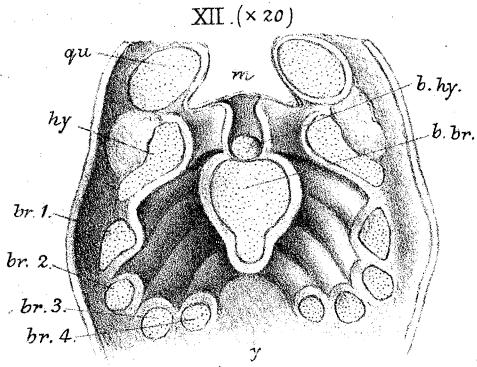
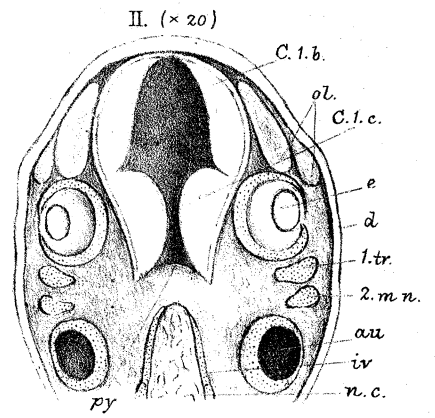
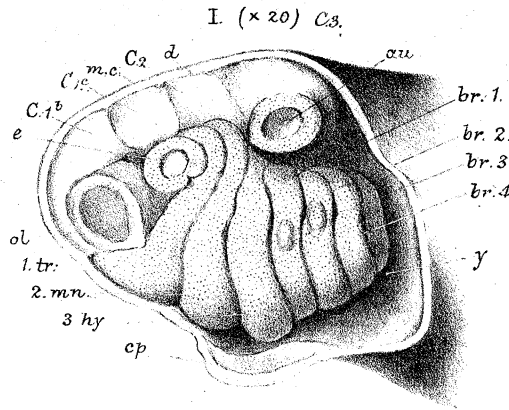
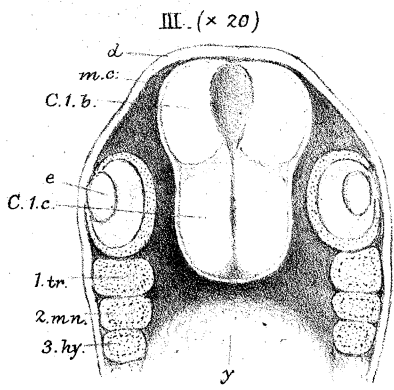
Various Stages.

- Fig. 1. Hyoid apparatus of young Frog in the 8th Stage. Magnified 12 diameters.
 Fig. 2. Lower view of hyoid cornua and basihyobranchial plate, with ossified thyro-hyals (adult Frog). $\times 4$ diameters.
 Fig. 3. Section (more than half) through fore part of nasal capsule of adult Frog. 12 diameters.
 Fig. 4. Section through right nostril, showing how the nasal canal is lined by the "septo-maxillary," a lobe of which is seen to project downwards, appearing in the inner nares. 12 diameters.
 Fig. 5. Inner nostril of right side, seen from below (part of fig. 7 in Plate IX.); the descending spur of the septo-maxillary is seen enclosed in a fold of membrane. $\times 12$ diameters.
 Fig. 6. Part of fig. 3, further back—posterior face of the same section. $\times 12$ diameters.
 Fig. 7. Section (more than half) through hinder part of nasal capsules of the same. 12 diameters.
 Fig. 8. Section (front view of left side) through the "foramen ovale" and anterior part of auditory capsule. $\times 12$ diameters.
 Fig. 9. Section (front view of right side) through the middle of the auditory capsule, and passing through fenestral fossa and stylo-hyal on the outside, and through the "meatus internus" on the inner. $\times 12$ diameters.
 Fig. 10. Section (front view of right side) through the supraoccipital and epiotic regions, the stapedia plate being severed at its hinder extremity. $\times 12$ diameters.
 Figs. 11–20. Diagrams showing the metamorphoses undergone by the first three facial arches, and their relation to the ear-capsule.



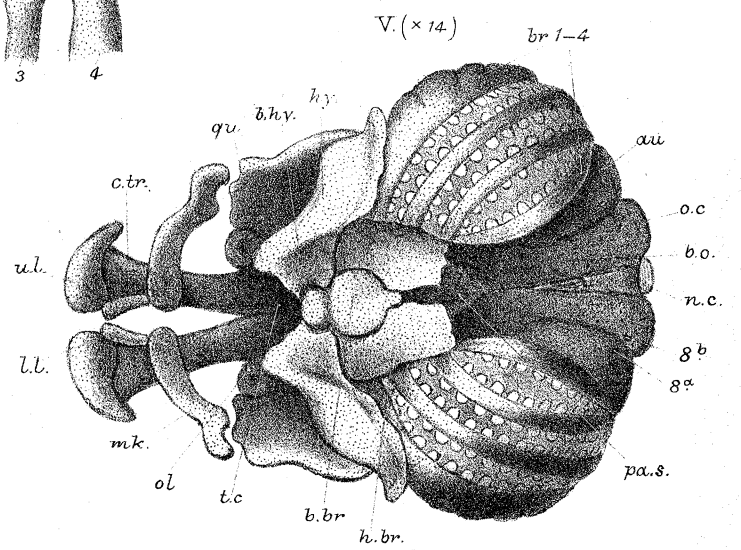
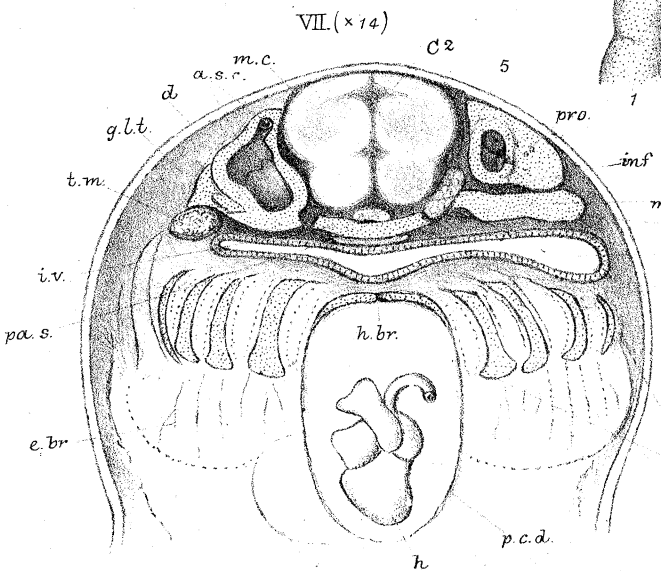
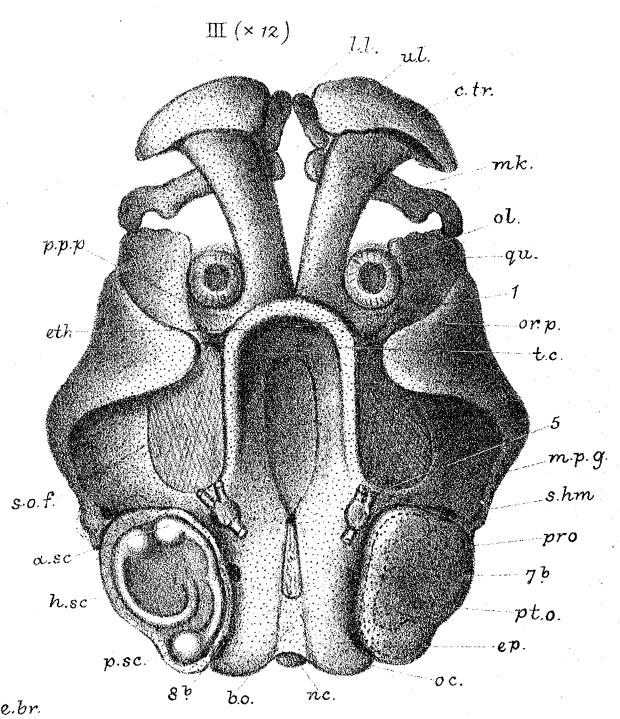
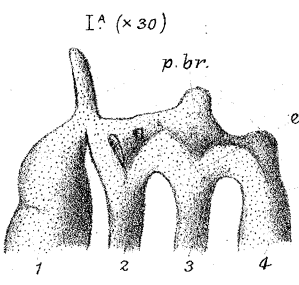
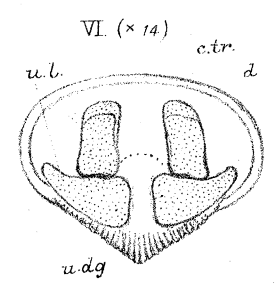
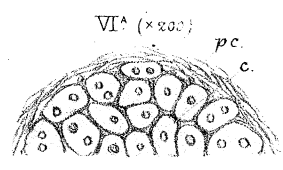
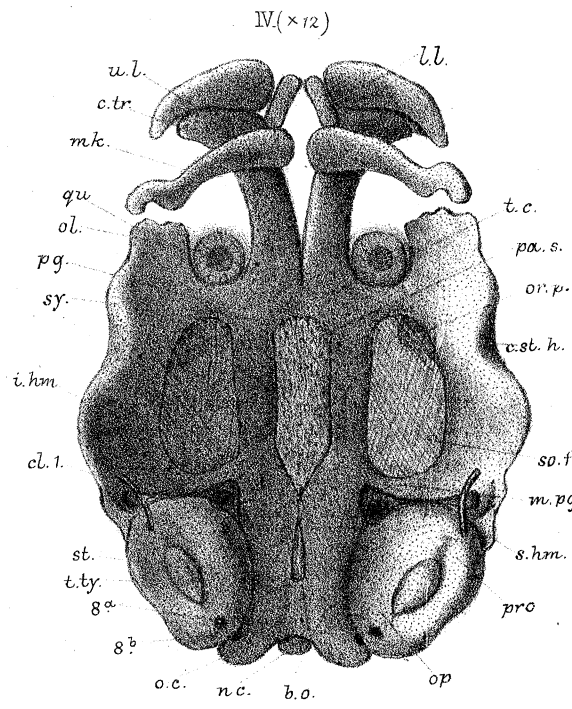
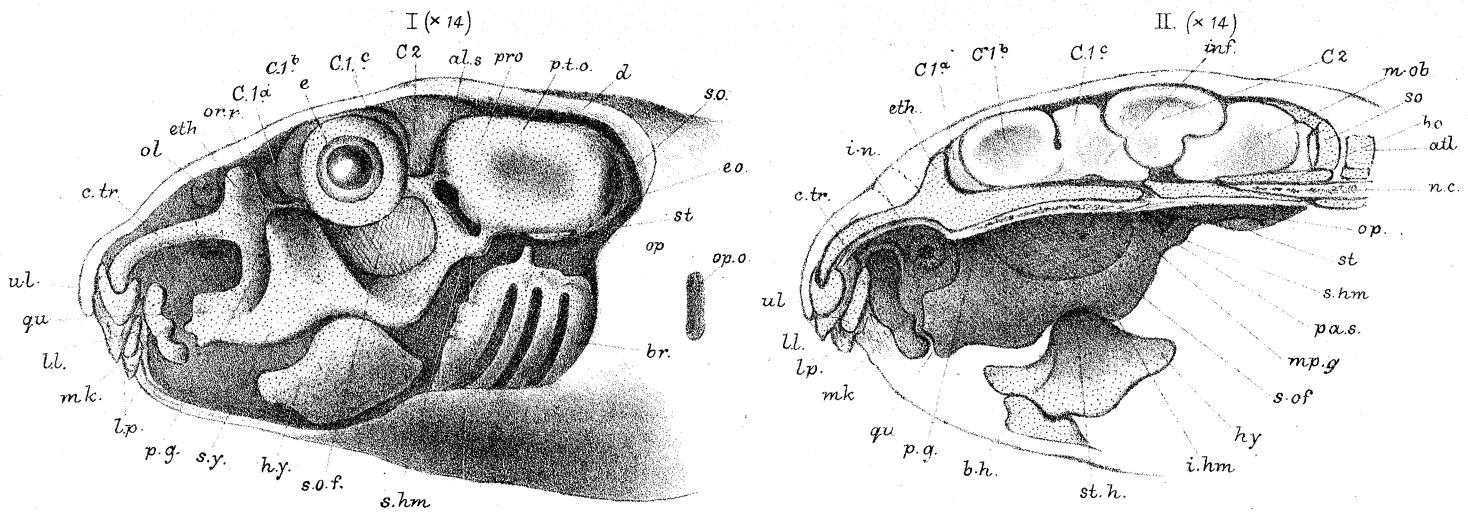
Frog's Skull.

Fig^s 1-9. 1st Stage. Fig^s 10-13. 2nd Stage.

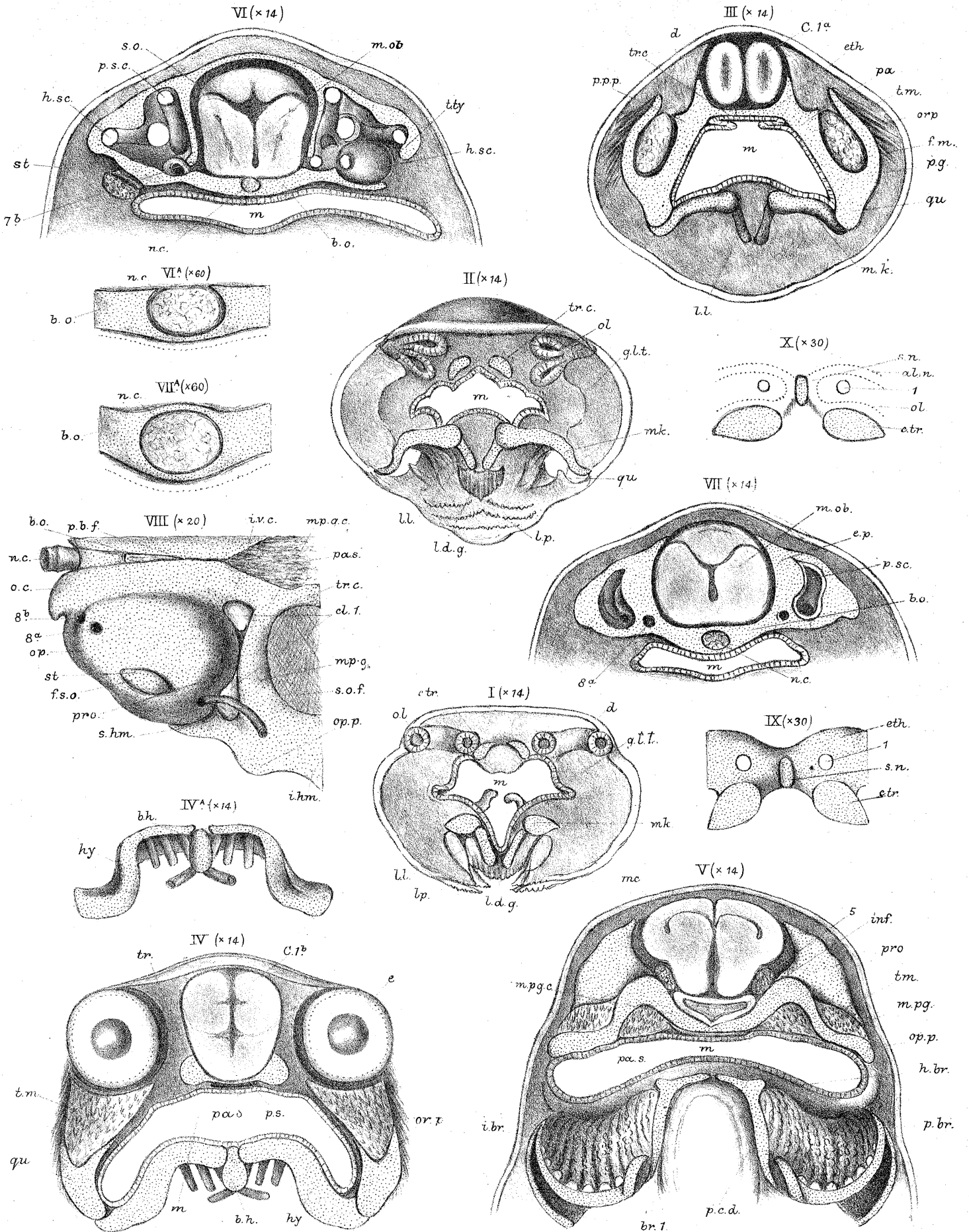


Frog's Skull.

Fig's 1-6. 2nd Stage (cont^d) Fig's 7-12. 3rd Stage.

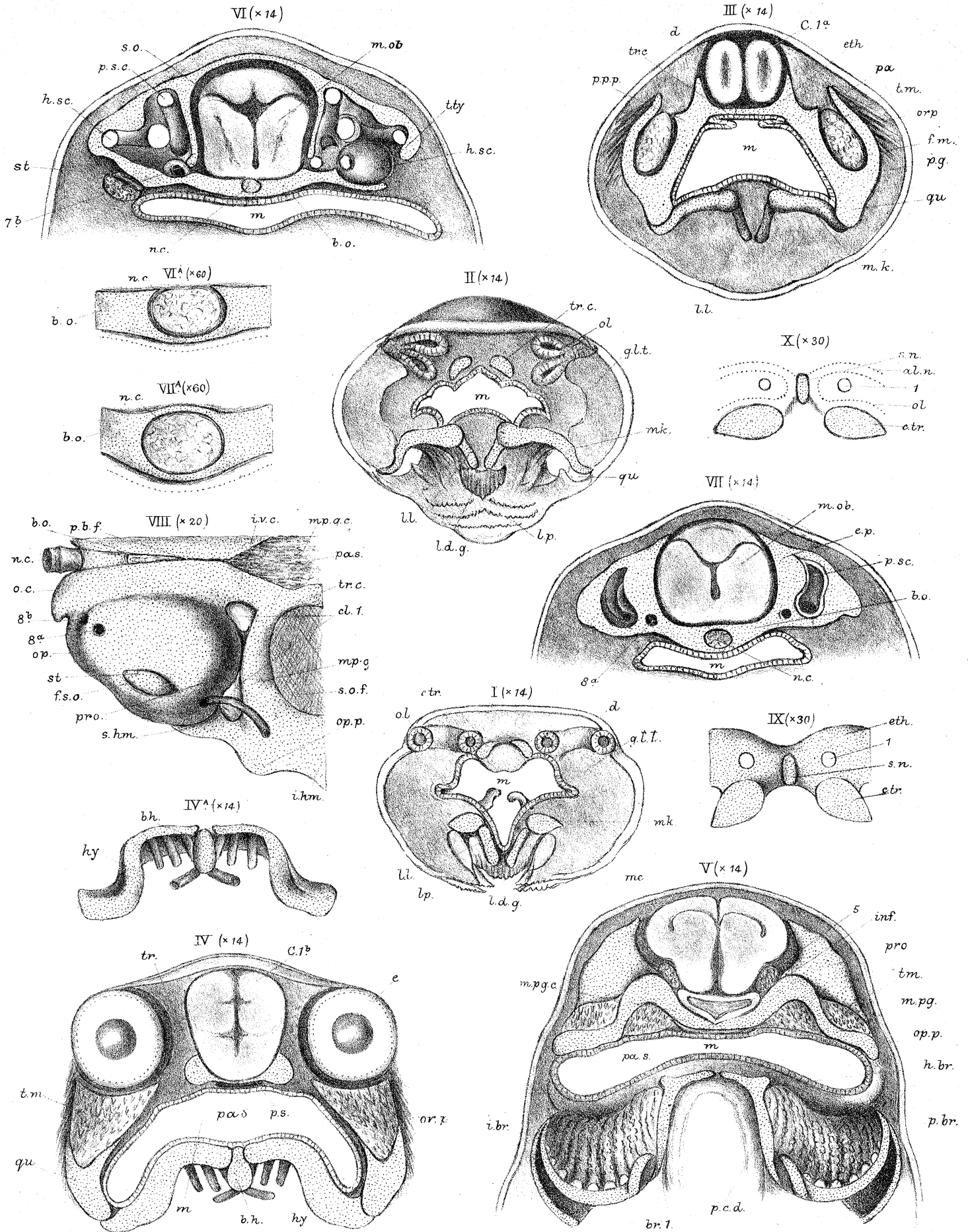


Frog's Skull Stage 4.



Frog's Skull.

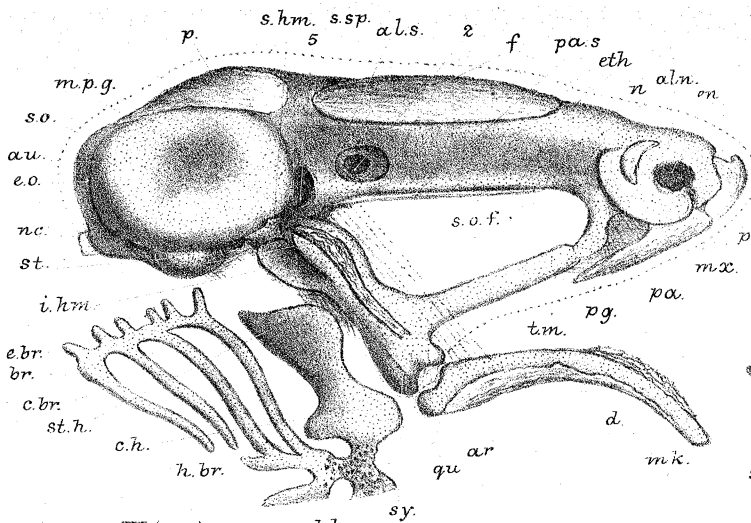
Fig. 1-8. Stage 4. cont^d. Fig. 9 & 10, Stage 5.



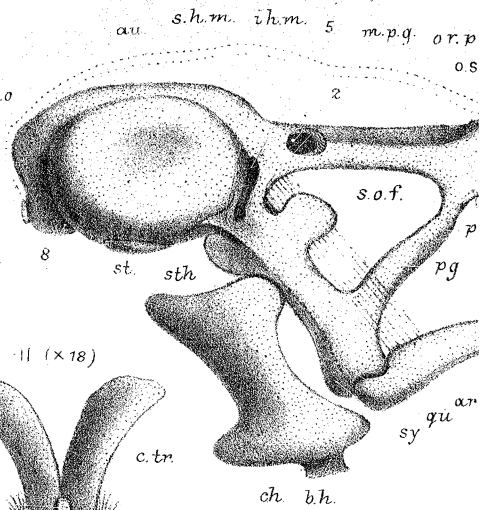
Frog's Skull.

Fig. 1-8. Stage 4. cont^d. Fig. 9 & 10, Stage 5.

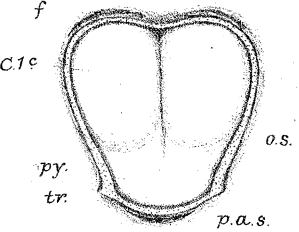
III. ($\times 15$)



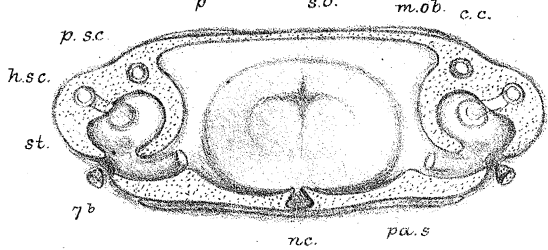
I. ($\times 15$)



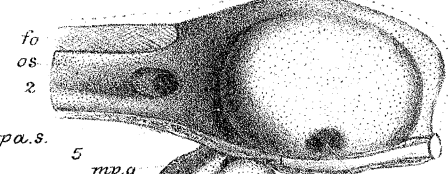
IX ($\times 18$)



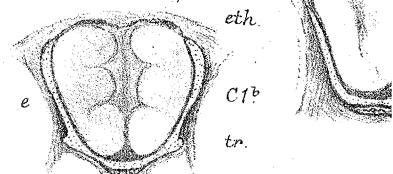
X ($\times 18$)



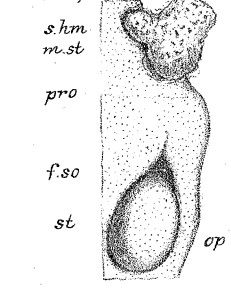
IV ($\times 15$)



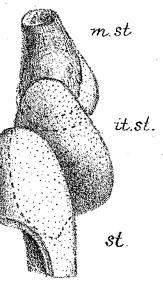
VII ($\times 18$) f



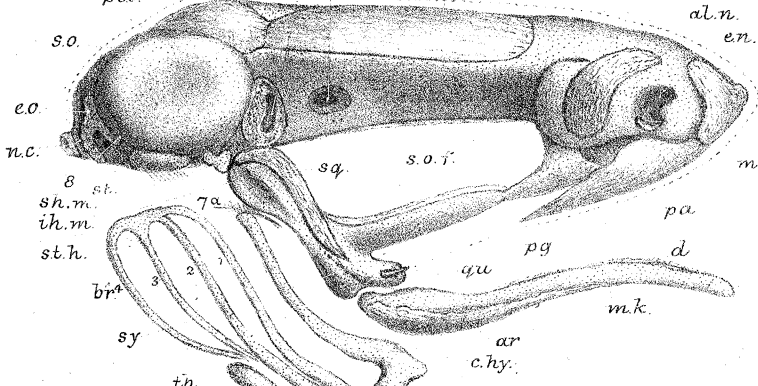
XII ($\times 30$)



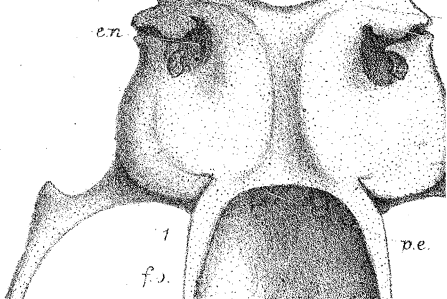
XIV ($\times 30$)

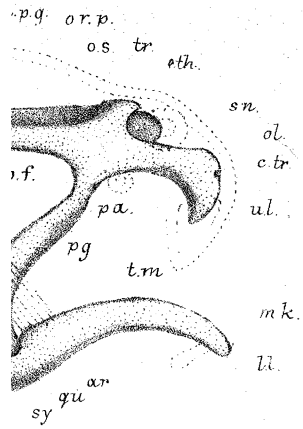


V ($\times 15$)

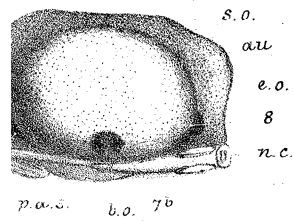


XI ($\times 20$)

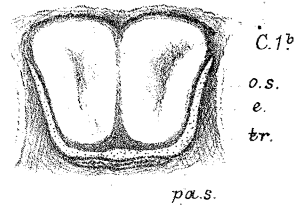




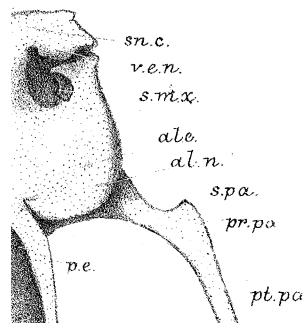
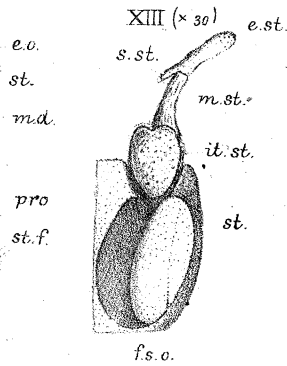
I^A (x15)

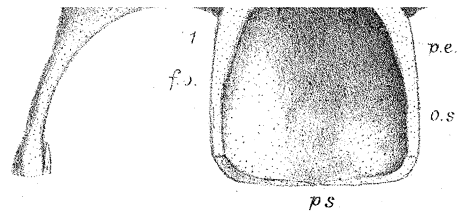
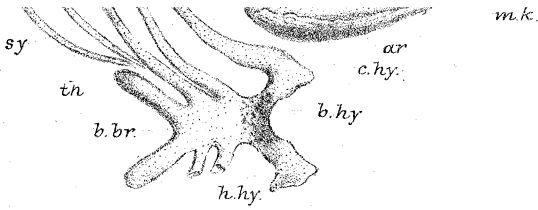


VIII (x18) f



XIII (x30)

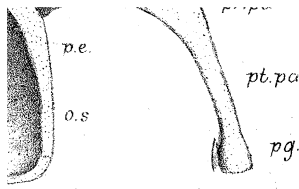




W.K.P. del. ad. nat. Geo. West lith.

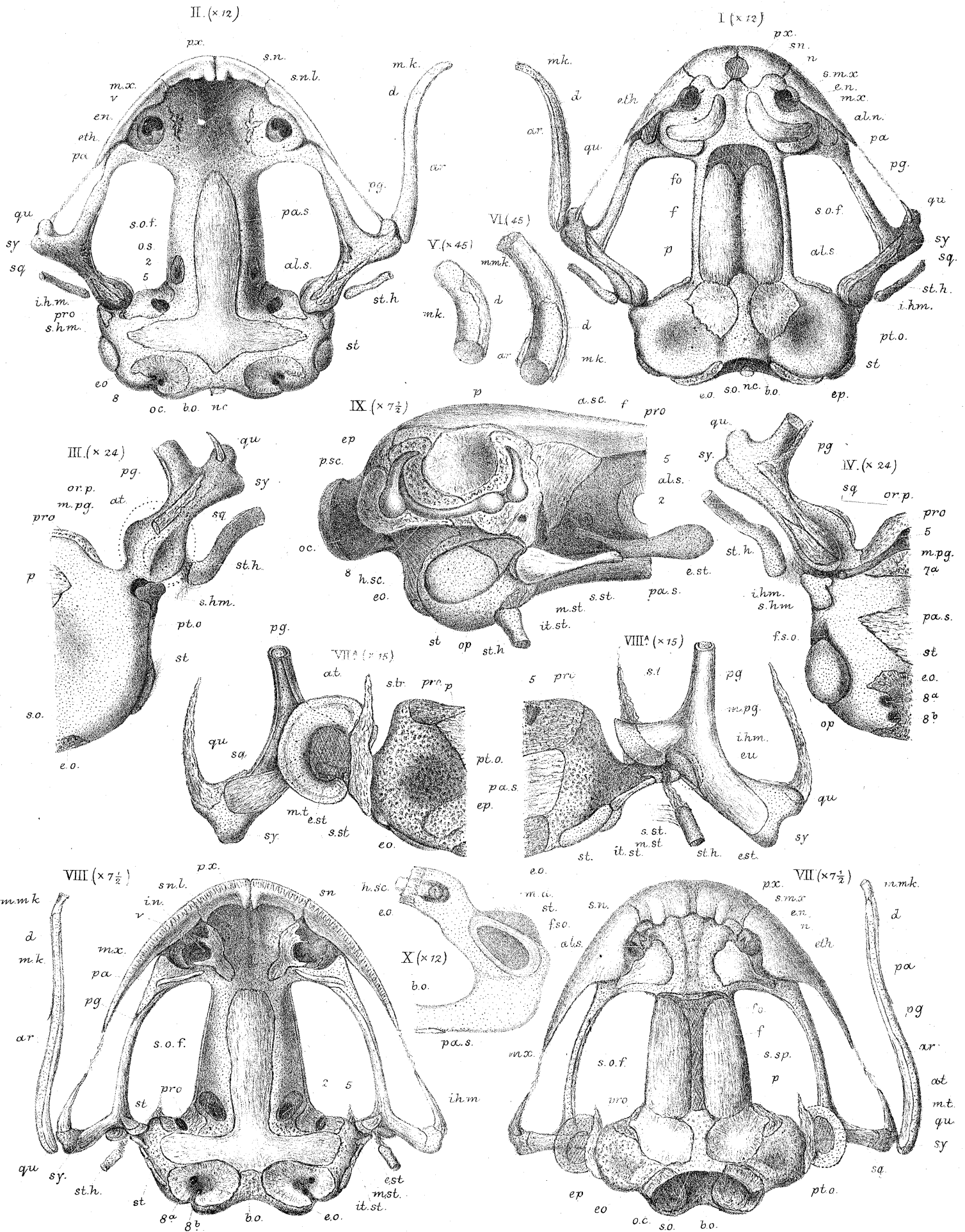
Frog's Skull.

Figs 1, 1^a & 2. 5th Stage. — Figs 3, 4 6th Stage. — Figs 5–12. 7th Stage. — Fig. 13. 8th Stage. — Fig. 14. 9th Stage. — Figs 15, 16. 10th Stage.



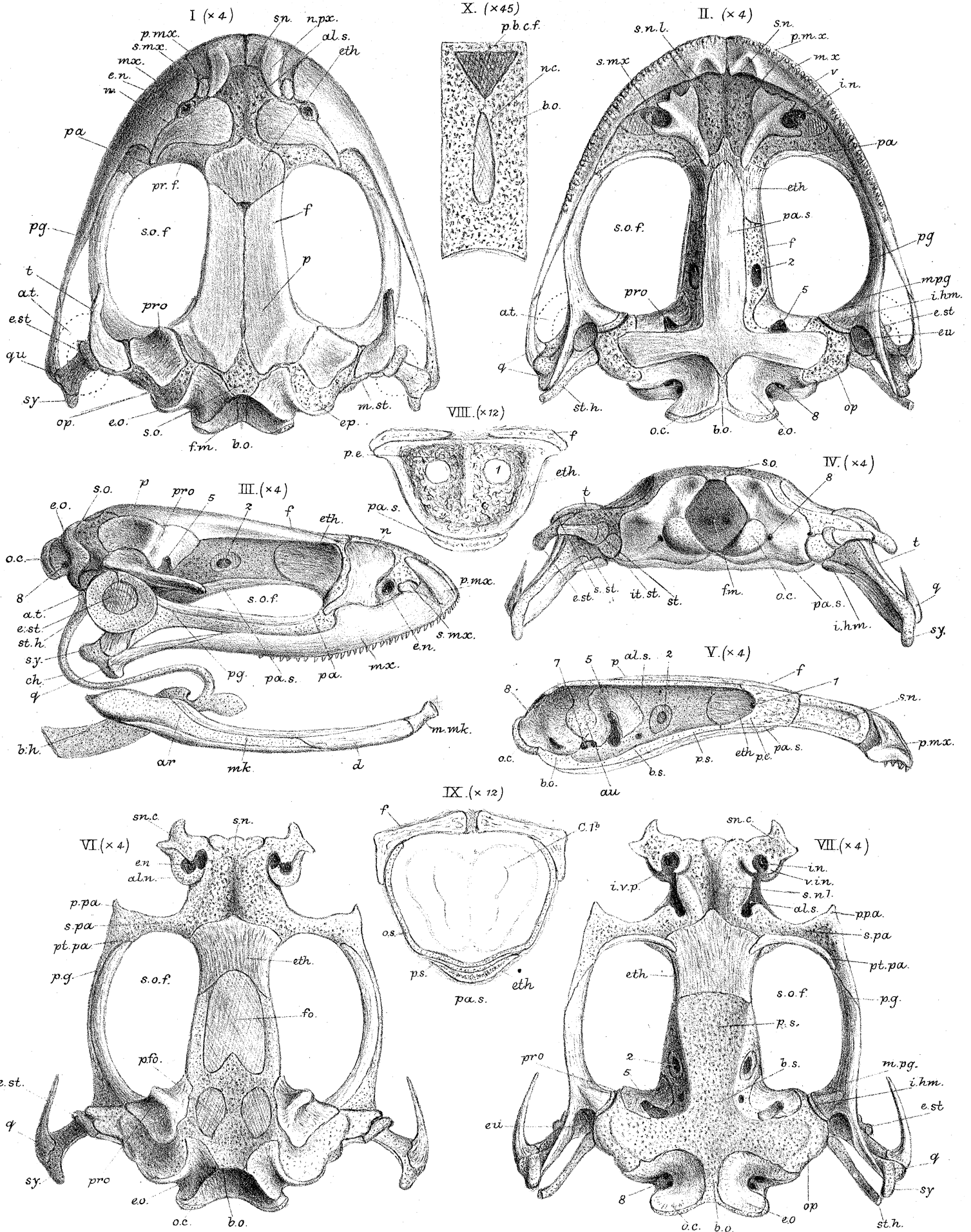
W. West & C^o imp.

Fig. 14. 9th Stage.



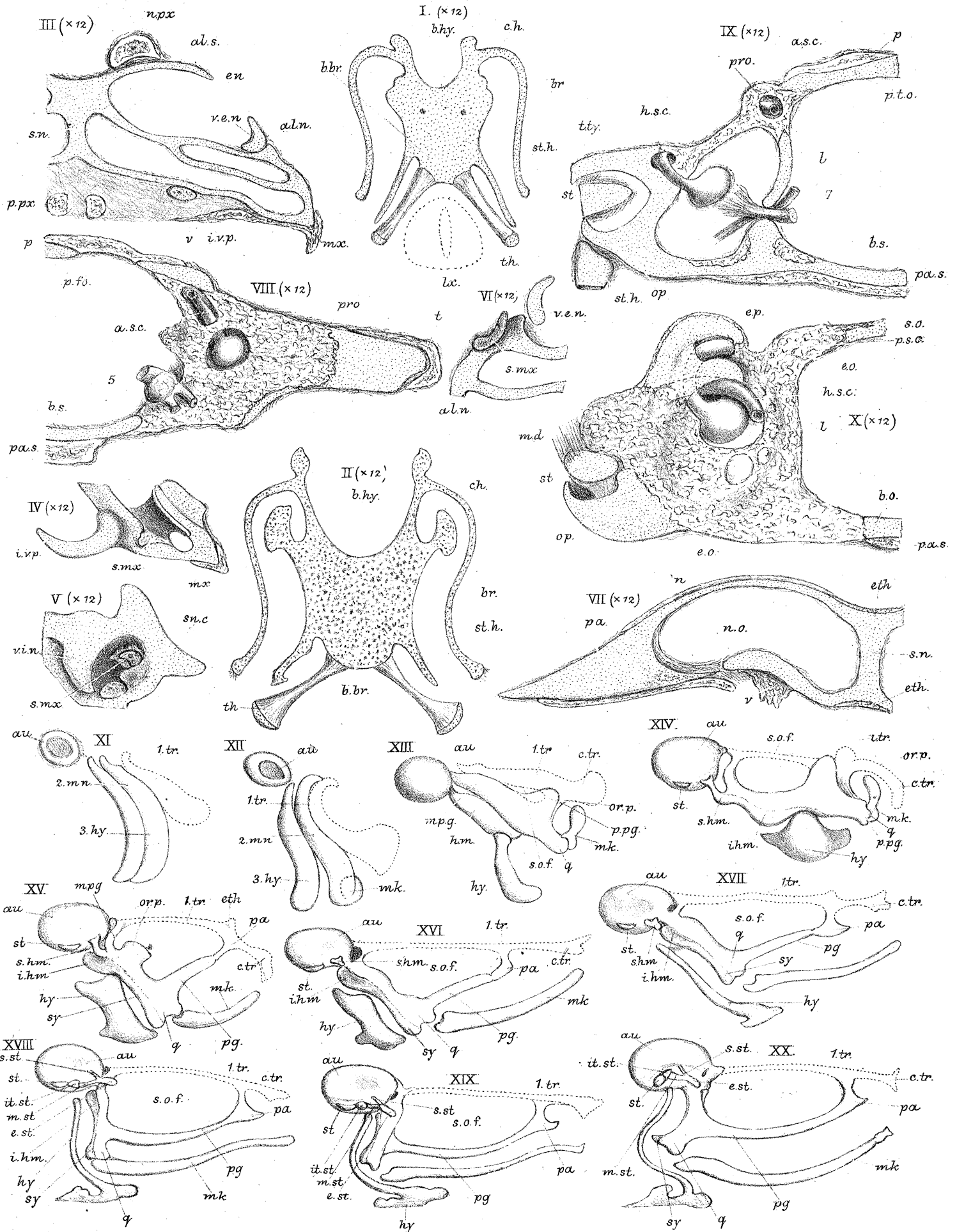
Frog's Skull.

Figs 1-5. 7th Stage. — Fig. 6. 8th Stage. — Figs 7-8a 9th Stage. — Figs. 9-10. 10th Stage.



Frog's Skull.

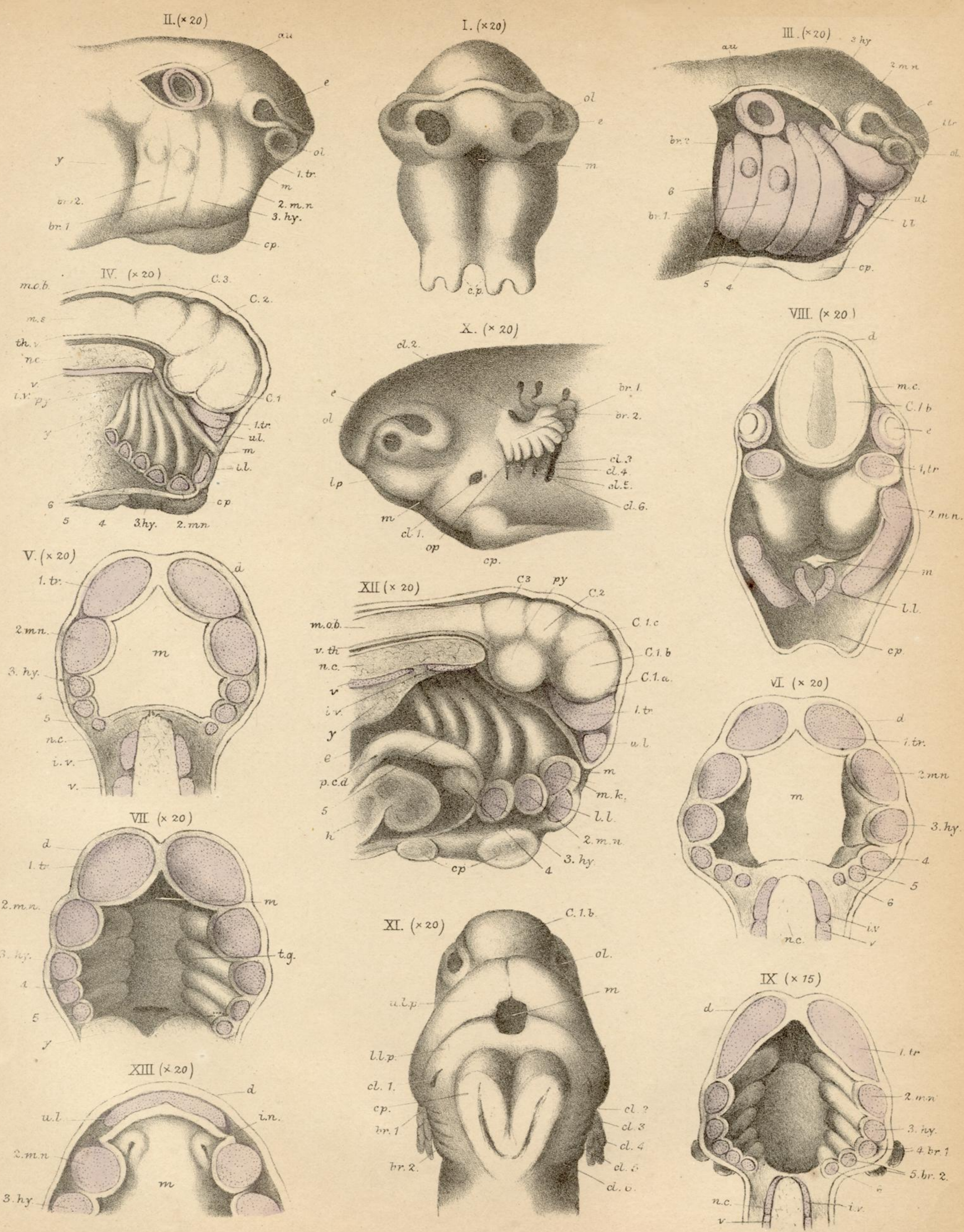
Fig^s 1-9. 10th Stage. Fig. 10. 7th Stage.



W.K.P. del. ad nat. Geo. West lith.

Frog's Skull.
Various Stages

W. West & C^o imp.



Frog's Skull.

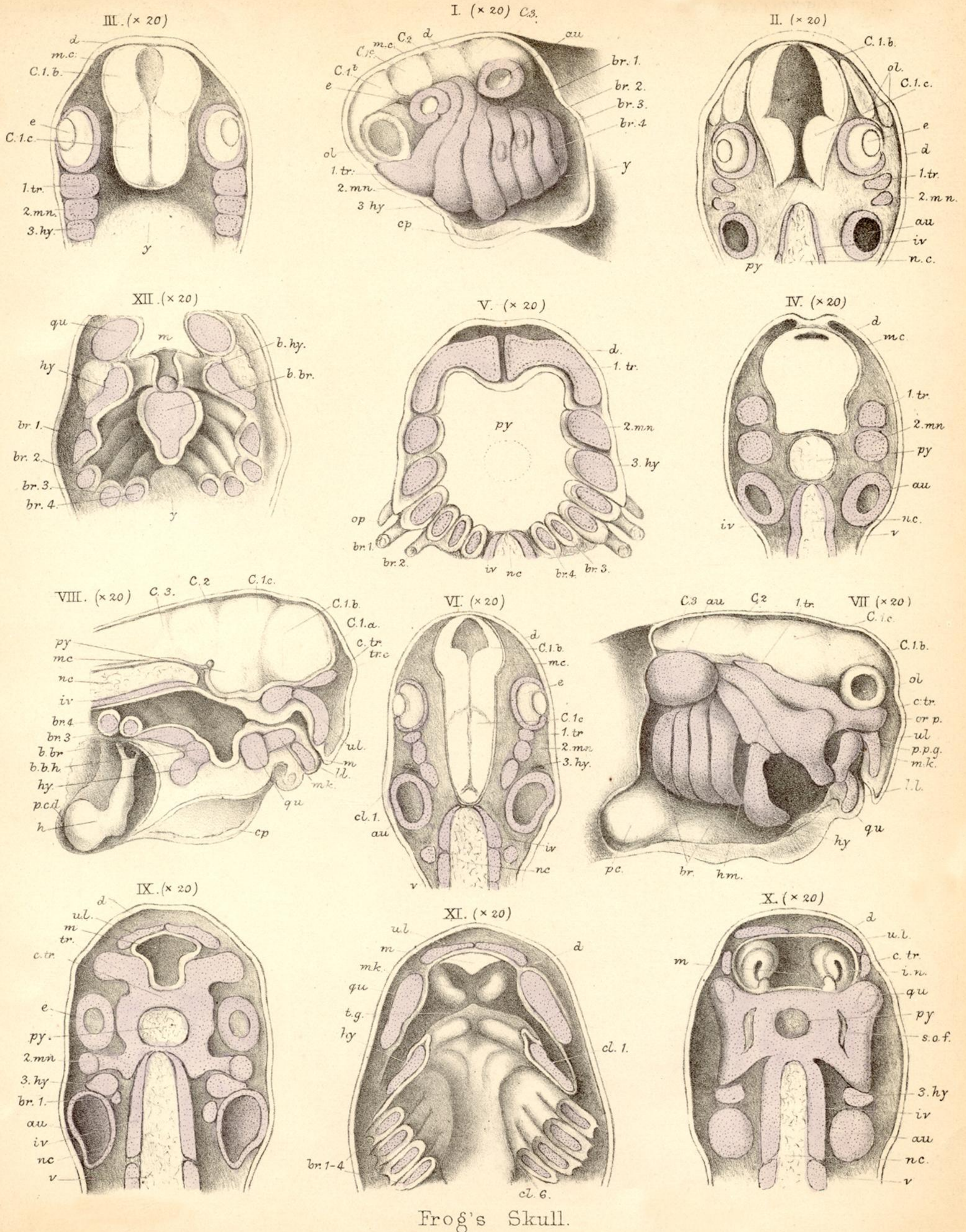
PLATE III.

First Stage.—Embryo of Frog 2-3 lines long; two days before and two days after hatching.

- Fig. 1. Front view of head before hatching. $\times 20$ diameters.
- Fig. 2. Side view of the same, with ear-sac exposed. $\times 20$ diameters.
- Fig. 3. Same as last, with facial arches, as well as ear-sacs, exposed. $\times 20$ diameters.
- Fig. 4. Vertical section of head of the same. $\times 20$ diameters.
- Fig. 5. Horizontal section of the same, immediately below the cranial cavity. $\times 20$ diameters.
- Fig. 6. A similar section taken a little lower down. $\times 20$ diameters.
- Fig. 7. Another similar section, still lower down, and showing the floor of the mouth. $\times 20$ diameters.
- Fig. 8. A transversely vertical section of fore part of face, seen from behind. $\times 20$ diameters.
- Fig. 9. A section, like fig. 5, of a more developed embryo (3 lines long). $\times 15$ diameters.

Second Stage.—Embryos 4 lines long, four or five days after hatching.

- Fig. 10. Side view of head. $\times 20$ diameters.
- Fig. 11. Under view of the same. $\times 20$ diameters.
- Fig. 12. Vertical section of the same. $\times 20$ diameters.
- Fig. 13. Fore part of horizontal section of the same, from below, and showing the palate and inner nares. $\times 20$ diameters.



Frog's Skull.

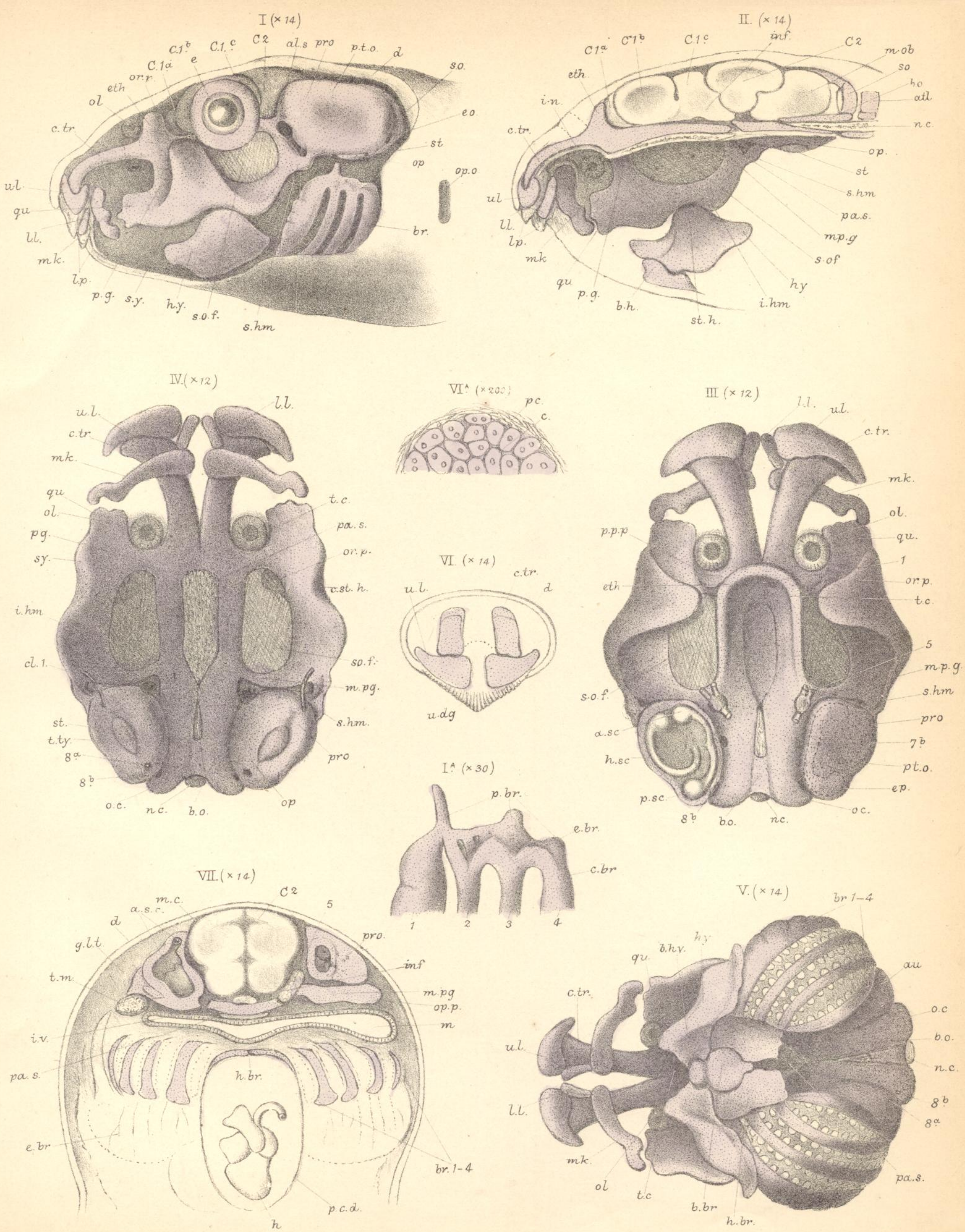
PLATE IV.

Second Stage (continued).

- Fig. 1. Side view of head with sensory organs and facial arches exposed. $\times 20$ diameters.
- Fig. 2. Horizontal section of head through eyeballs, ear-sacs, brain, and notochord. $\times 20$ diameters.
- Fig. 3. Another horizontal section, dipping a little backwards, so as to expose the yelk-sac, below the notochord. $\times 20$ diameters.
- Fig. 4. A similar section, in which the dip is forwards, so as to be below the eye and through the notochord and pituitary body and ear-sacs. $\times 20$ diameters.
- Fig. 5. A horizontal section below the brain and through all the facial arches and the end of the notochord: the pituitary body is indicated by dotted lines. $\times 20$ diameters.
- Fig. 6. Horizontal section of head, through eyes, ear-sacs, brain, and notochord. $\times 20$ diameters.

Third Stage.—Young Tadpoles 5 lines long.

- Fig. 7. Lateral view of head, with eyes removed, and nasal and auditory sacs and facial cartilages exposed. $\times 20$ diameters.
- Fig. 8. Vertical section of head, showing brain, notochord, oral cavity, and heart. $\times 20$ diameters.
- Fig. 9. A dissected horizontal section, showing basis cranii from above; with eyeballs, ear-sacs, upper labial cartilage, and part of oral cavity. $\times 20$ diameters.
- Fig. 10. A similar dissected section seen from below, and showing the openings of the nasal sacs into the fore part of the palate immediately in front of the pterygo-palatine connectives. $\times 20$ diameters.
- Fig. 11. Horizontal section through the facial arches and upper lip of a somewhat more advanced Tadpole, showing the floor of the mouth and its opening. $\times 20$ diameters.
- Fig. 12. A similar section lower down; here the mucous membrane has been removed, and with it the tongue and lips. $\times 20$ diameters.



Frog's Skull

PLATE V.

Fourth Stage.—Tadpoles 1 inch long.

Fig. 1. Side view of head and part of trunk of Tadpole with first appearance of hind limbs, as far as to the left (or azygous) opercular opening. The skin has been removed, and the parts so dissected as to display the cerebral masses and sense-capsules, skull, face, and branchial arches. The hyoid and branchial arches are somewhat drawn downwards for display. $\times 14$ diameters.

Fig. 1^a. Upper part of branchial arches. $\times 30$ diameters.

Fig. 2. A vertical section of the same as fig. 1, showing the right side from within. $\times 15$ diameters.

Fig. 3. Upper view of skull and face of Tadpole somewhat more advanced, so dissected as to display the fundus of the cranium and the cavity of the ear-capsule. $\times 12$ diameters.

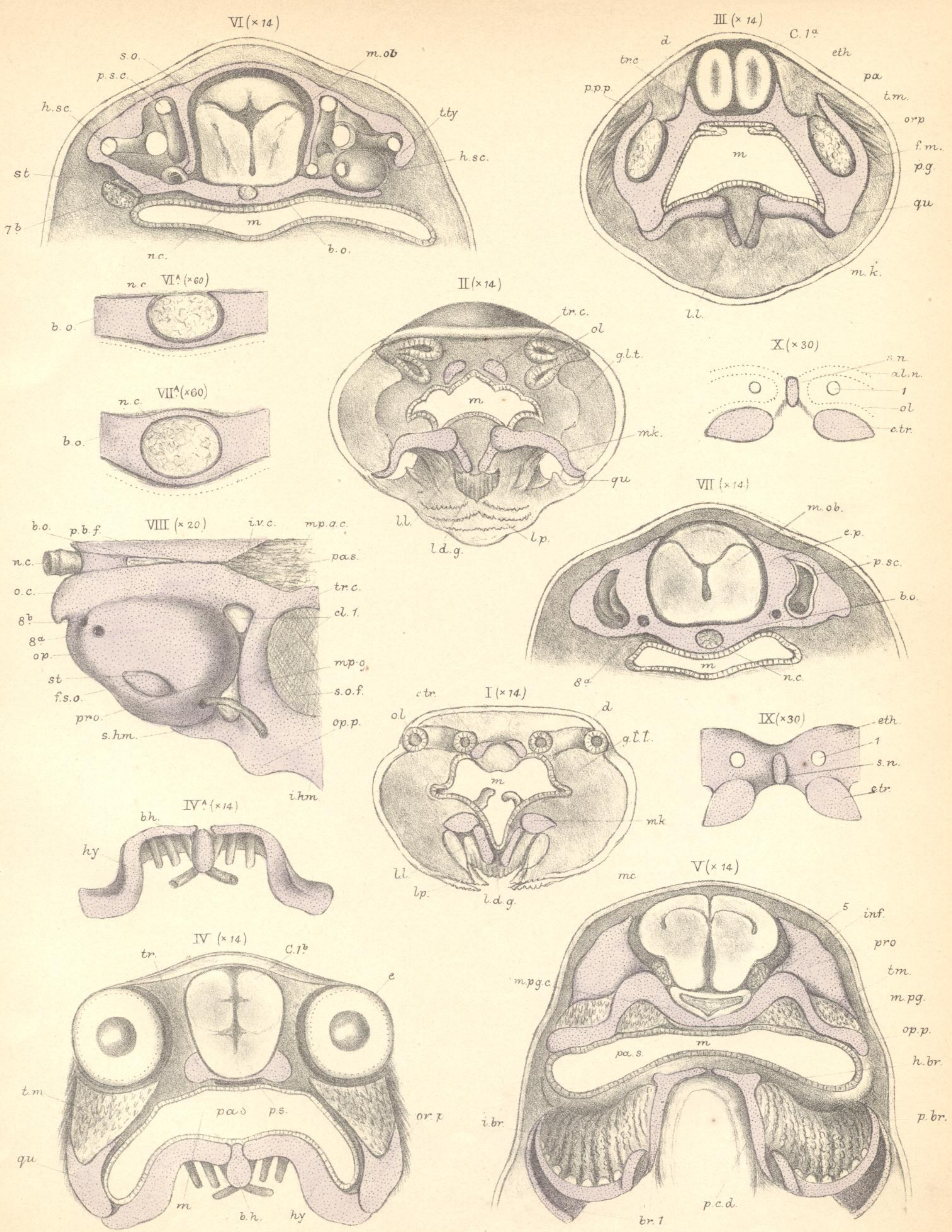
Fig. 4. The same as fig. 3, but shown from below. $\times 12$ diameters.

Fig. 5. Lower view of skull, face, and branchial arches of younger Tadpole (same as figs. 1 & 2): the outer "branchiæ" have been removed, and the dentate elevations from which the inner filaments grow are displayed. $\times 14$ diameters.

Fig. 6. No. 1 of a series of vertically transverse sections through the skull and face of the younger Tadpole: this has been taken in front of the mouth, and is seen from behind. $\times 15$ diameters.

Fig. 6^a. Part of the same, being the thin edge of the upper labial cartilage. $\times 200$ diameters.

Fig. 7. Section No. 7, made through the optic lobes (*o.l.*), foramina ovalia (5), and pericardium (*p.c.d.*). $\times 14$ diameters.

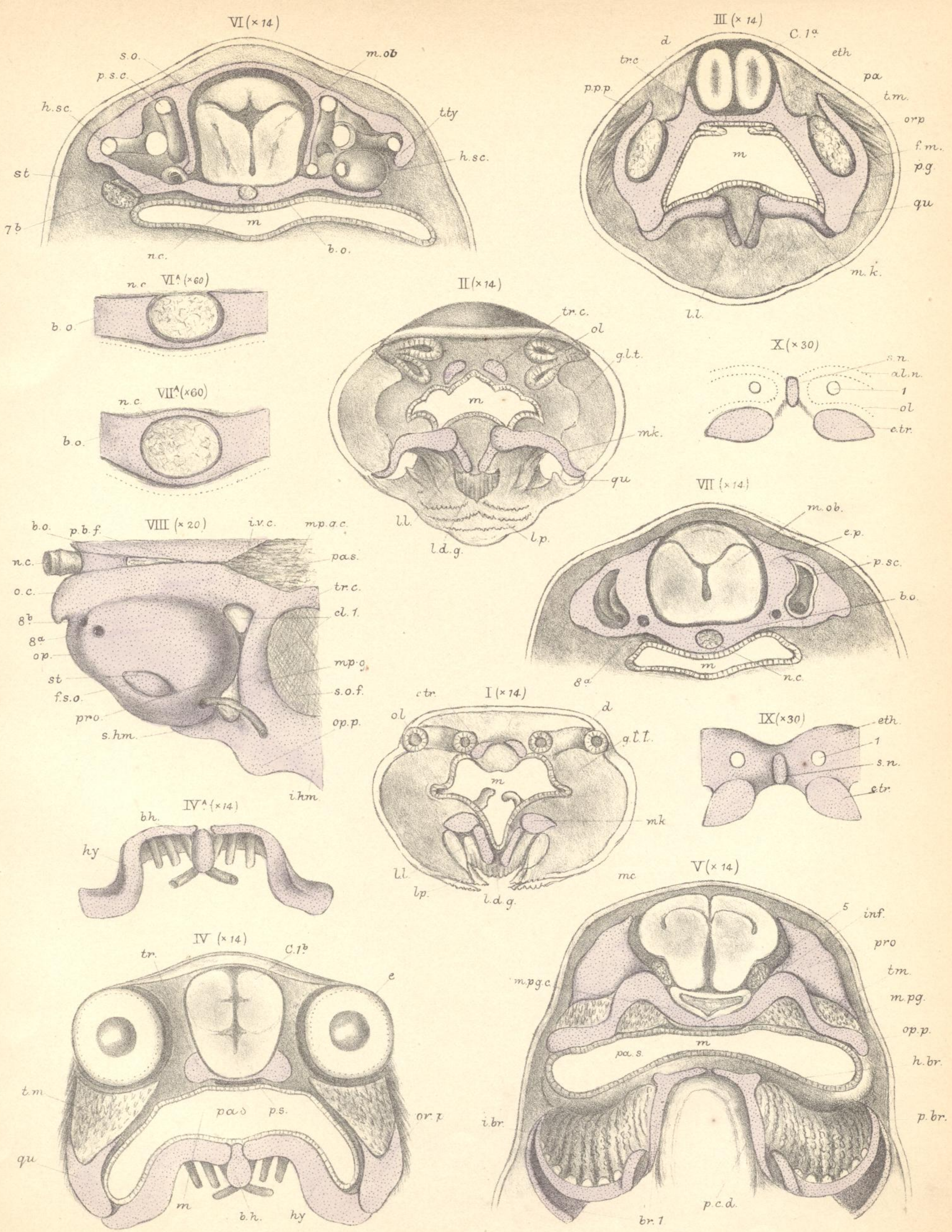


Frog's Skull.

PLATE VI.

Fourth Stage (continued), and part of Fifth Stage.

- Fig. 1. Section No. 2, made through the fore part of the nasal sac (*n*), the mouth, the ends of MECKEL'S cartilages (*m.k.*), and through the substance of the "inferior labials" (*ll.*). $\times 14$ diameters.
- Fig. 2. Section No. 3, made through the nasal sacs, close behind the lower labials (*ll.*), and in front of the quadrate condyle. $\times 14$ diameters.
- Fig. 3. Section No. 4, made through the olfactory lobes (*C1^a*), the quadrate condyle (*q.*), the orbitar process (*or.p.*), and *behind* the Meckelian and lower labial cartilages. $\times 14$ diameters.
- Fig. 4. Section No. 5, made through the prosencephalon (hemispheres) (*C1^b*), eyeballs (*e.*), the quadrate condyle (*q.*), and the hyoid arch (*hy*). $\times 14$ diameters.
- Fig. 4^a. Part of hyoid arch, seen from behind.
- Fig. 5. Section No. 6, made through optic lobes (*C 2*), infundibulum (*inf.*), metapterygoid (*m.pg.*), and close in front of pericardium (*p.c.d.*) and auditory capsules (*au.*). $\times 14$ diameters.
- Fig. 6. Section No. 8, made through the medulla oblongata (*m.ob.*), the middle of the auditory sac (*au.*), and behind the branchial arches. $\times 14$ diameters.
- Fig. 7. Section No. 9, made through the posterior part of auditory sac, in the occipital region, so as to cut through the epiotic eminences (*ep.*). $\times 14$ diameters.
- Fig. 8. Part of fig. 4, in Plate V., showing the metapterygoid (*m.pg.*), hyo-mandibular (*h.m.*), and auditory sac (*au.*) from below. $\times 20$ diameters.
- Fig. 9. A section of the skull in the 5th stage, showing the trabecular horns and the septum nasi, both in continuity with the front of the ethmoidal wall. $\times 30$ diameters.
- Fig. 10. Transversely vertical section of the skull in the 5th stage, a little in front of the ethmoidal wall, showing the trabecular horns distinct from the septum nasi. $\times 30$ diameters.

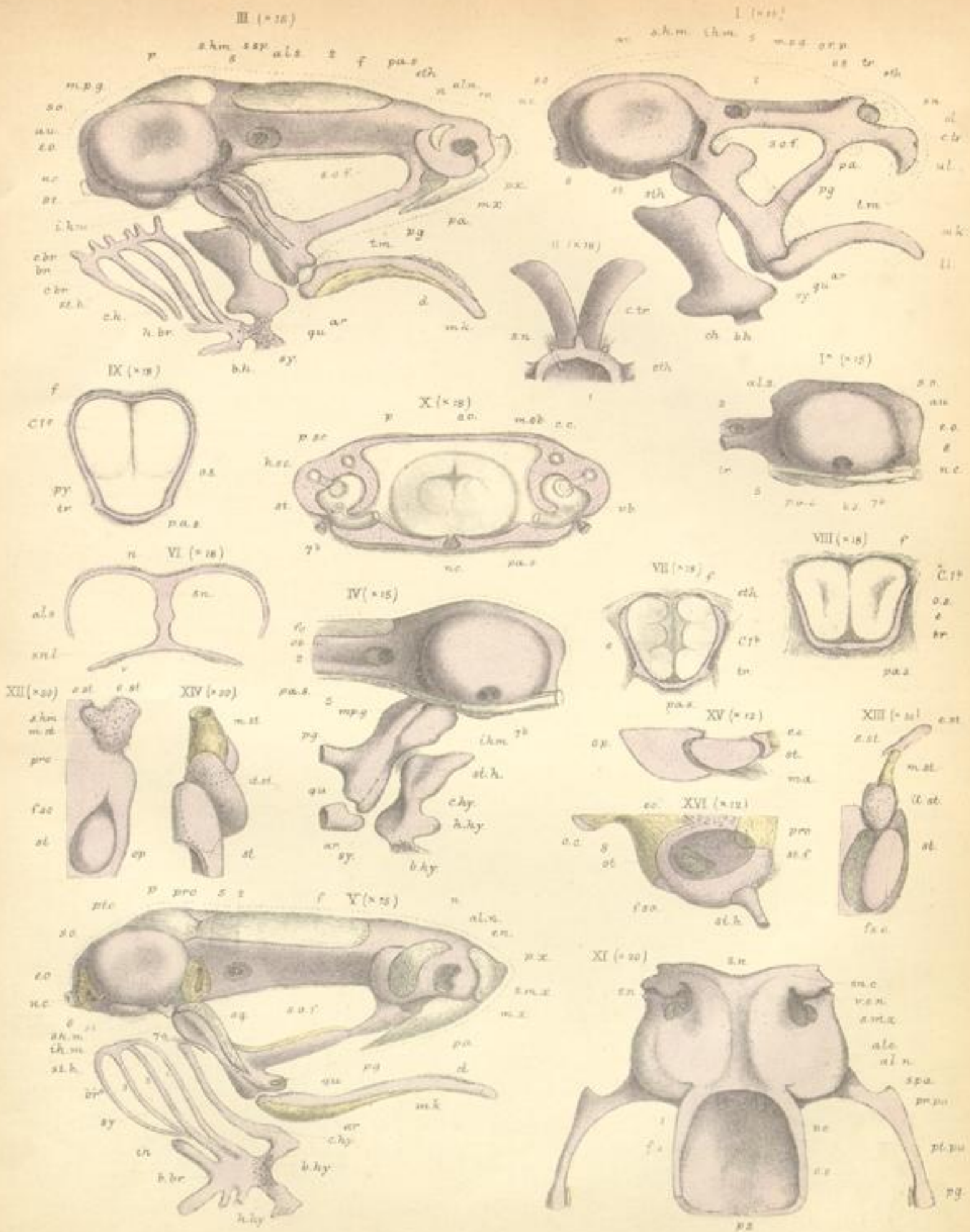


Frog's Skull.

PLATE VI.

Fourth Stage (continued), and part of Fifth Stage.

- Fig. 1. Section No. 2, made through the fore part of the nasal sac (*n*), the mouth, the ends of MECKEL'S cartilages (*m.k.*), and through the substance of the "inferior labials" (*ll.*). $\times 14$ diameters.
- Fig. 2. Section No. 3, made through the nasal sacs, close behind the lower labials (*ll.*), and in front of the quadrate condyle. $\times 14$ diameters.
- Fig. 3. Section No. 4, made through the olfactory lobes (*C1^a*), the quadrate condyle (*q.*), the orbital process (*or.p.*), and *behind* the Meckelian and lower labial cartilages. $\times 14$ diameters.
- Fig. 4. Section No. 5, made through the prosencephalon (hemispheres) (*C1^b*), eyeballs (*e.*), the quadrate condyle (*q.*), and the hyoid arch (*hy*). $\times 14$ diameters.
- Fig. 4^a. Part of hyoid arch, seen from behind.
- Fig. 5. Section No. 6, made through optic lobes (*C2*), infundibulum (*inf.*), metapterygoid (*m.pg.*), and close in front of pericardium (*p.c.d.*) and auditory capsules (*au.*). $\times 14$ diameters.
- Fig. 6. Section No. 8, made through the medulla oblongata (*m.ob*), the middle of the auditory sac (*au.*), and behind the branchial arches. $\times 14$ diameters.
- Fig. 7. Section No. 9, made through the posterior part of auditory sac, in the occipital region, so as to cut through the epiotic eminences (*ep.*). $\times 14$ diameters.
- Fig. 8. Part of fig. 4, in Plate V., showing the metapterygoid (*m.pg.*), hyo-mandibular (*h.m.*), and auditory sac (*au.*) from below. $\times 20$ diameters.
- Fig. 9. A section of the skull in the 5th stage, showing the trabecular horns and the septum nasi, both in continuity with the front of the ethmoidal wall. $\times 30$ diameters.
- Fig. 10. Transversely vertical section of the skull in the 5th stage, a little in front of the ethmoidal wall, showing the trabecular horns distinct from the septum nasi. $\times 30$ diameters.



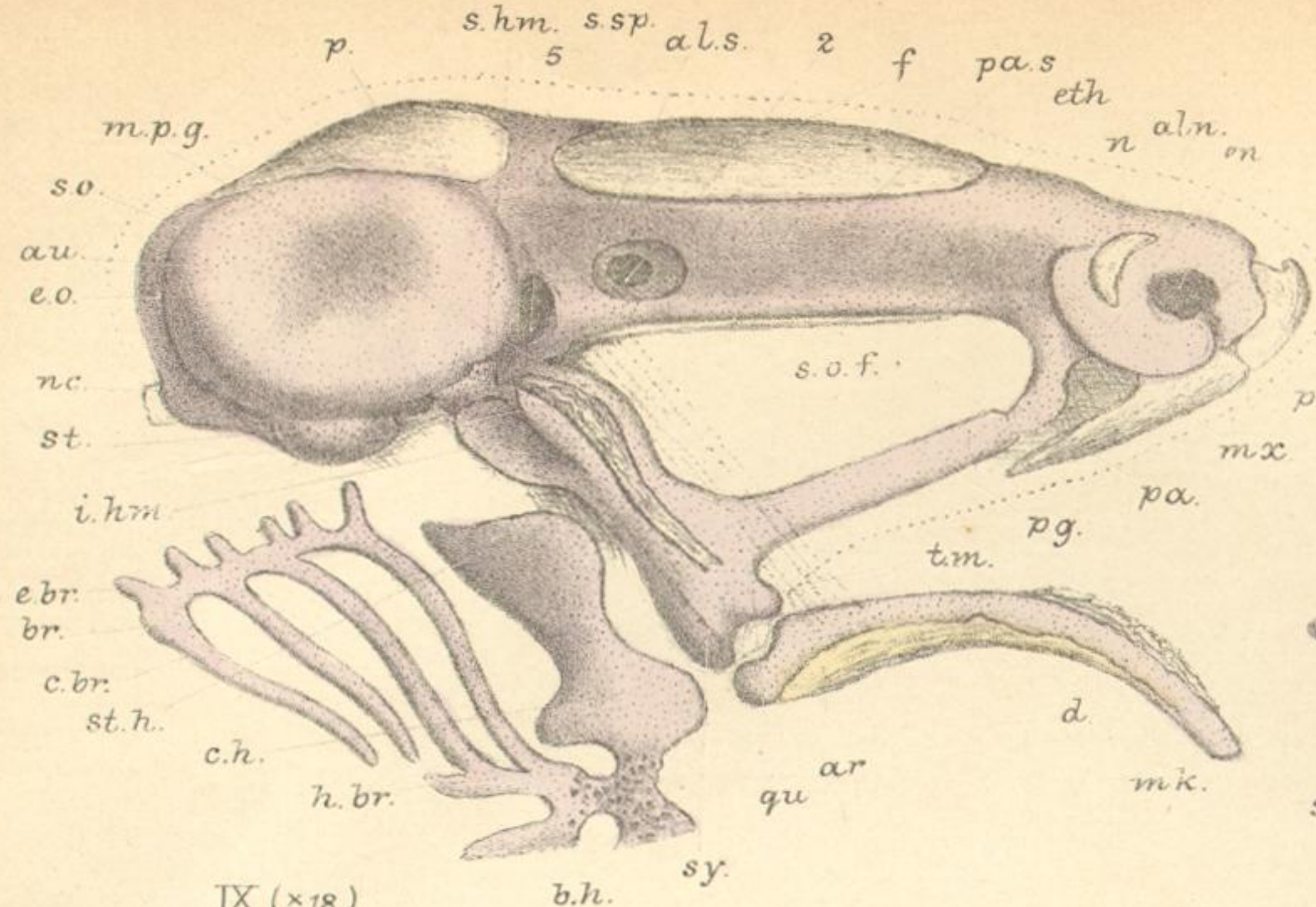
W.K.P. del. ad. nat. Geo. Wood. sculp.

Frog's Skull.

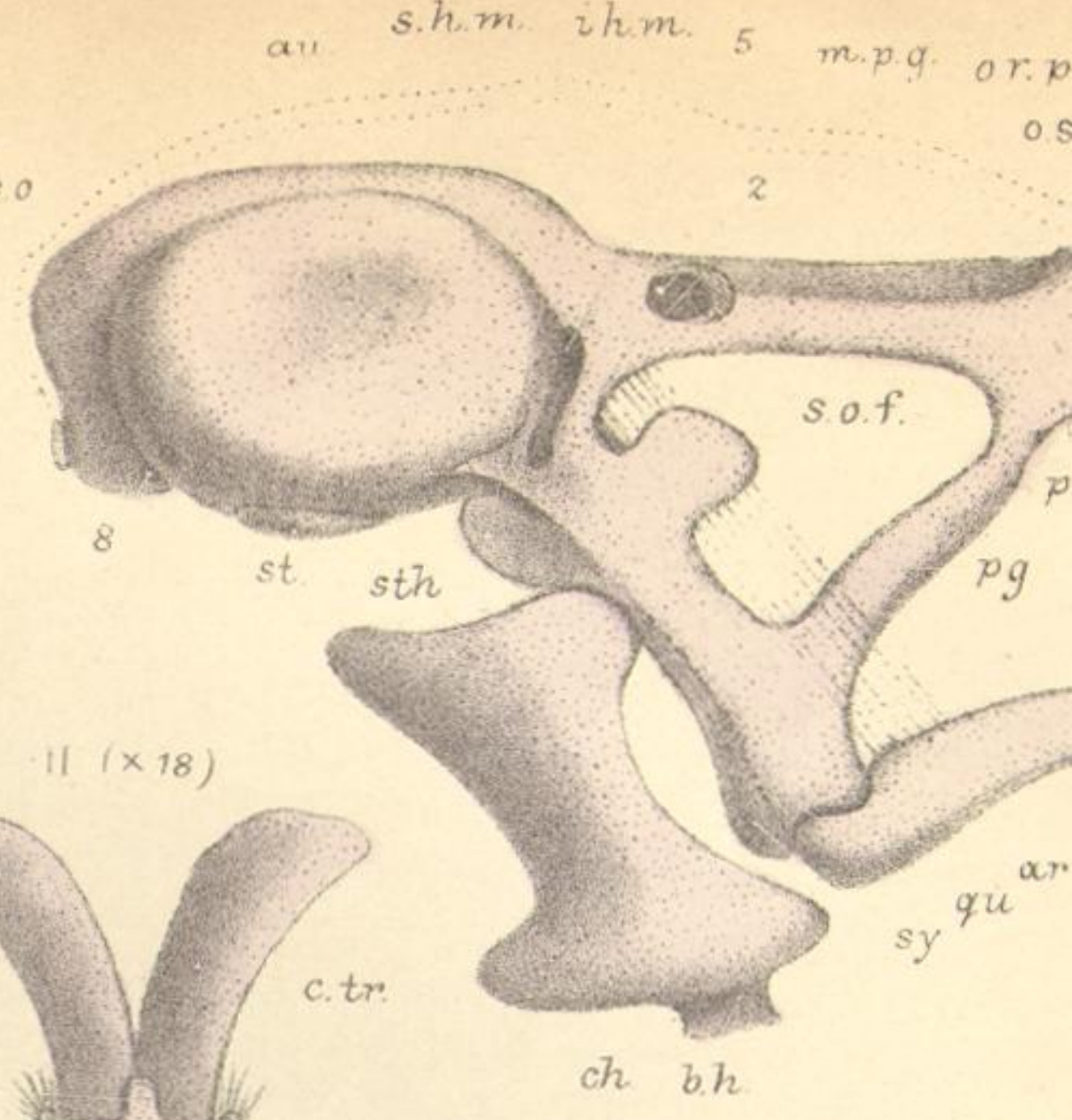
W. Wood sculp.

Fig. 1, 2, 3, 5th Stage — Fig. 3, 4, 6th Stage — Fig. 5-12, 7th Stage — Fig. 13, 8th Stage — Fig. 14, 9th Stage — Fig. 15, 16, 10th Stage.

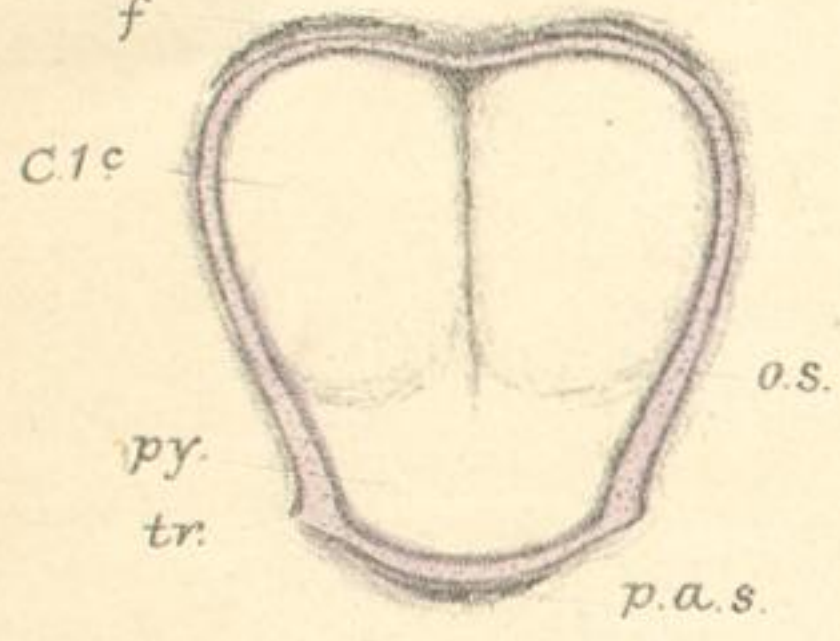
III. (x15)



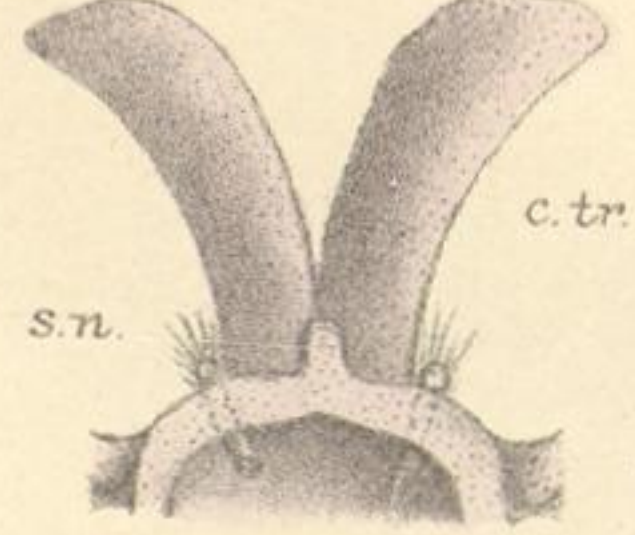
I. (x15)



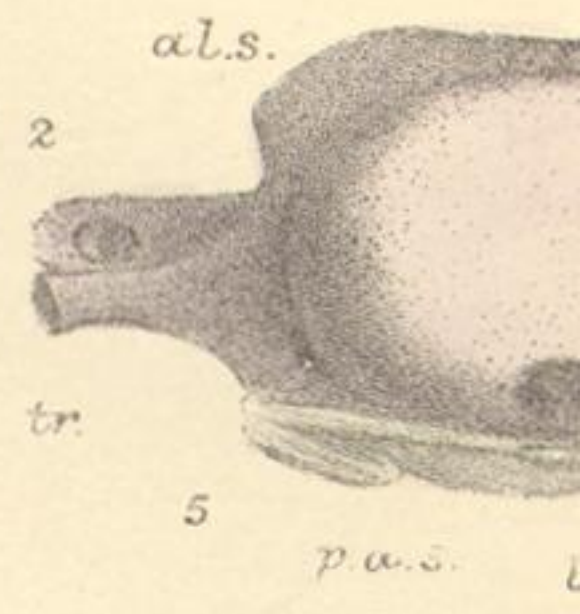
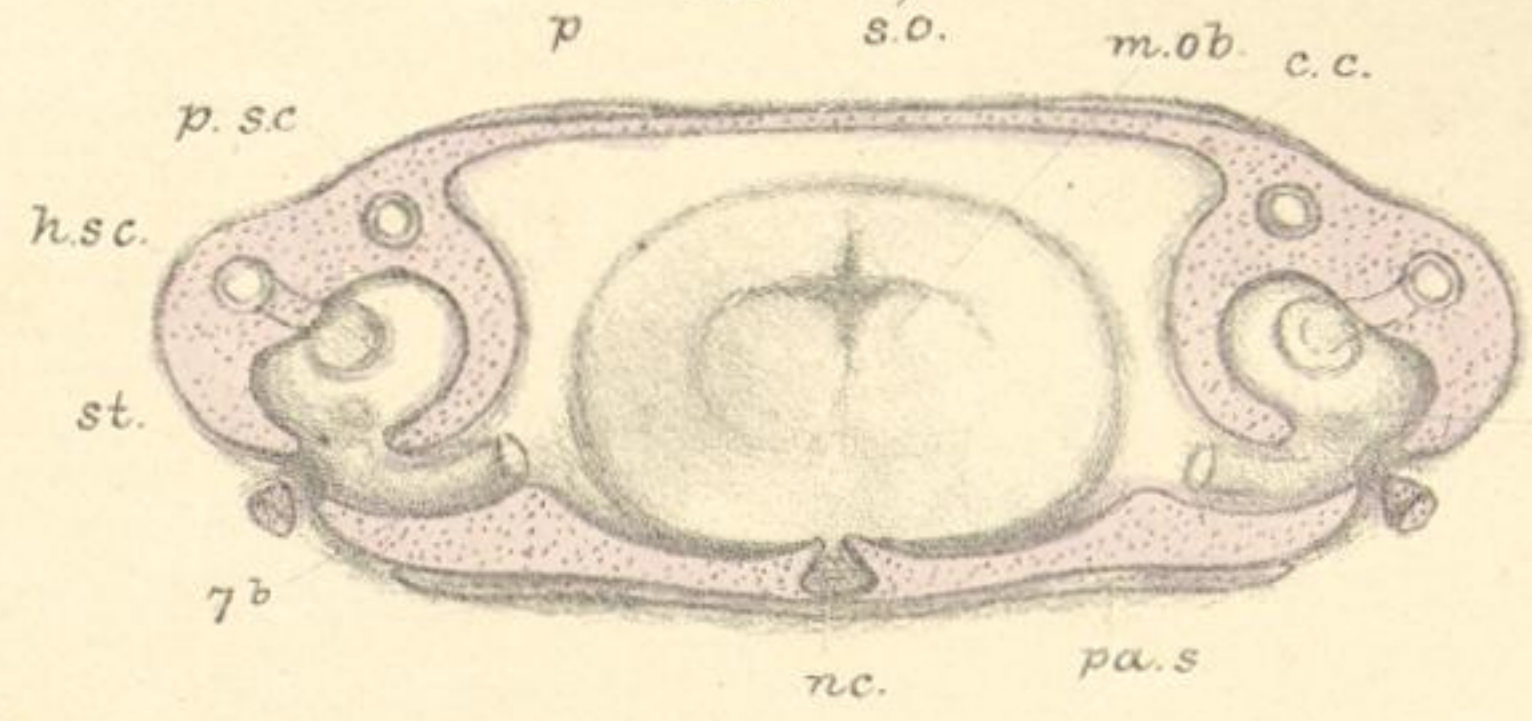
IX (x18)



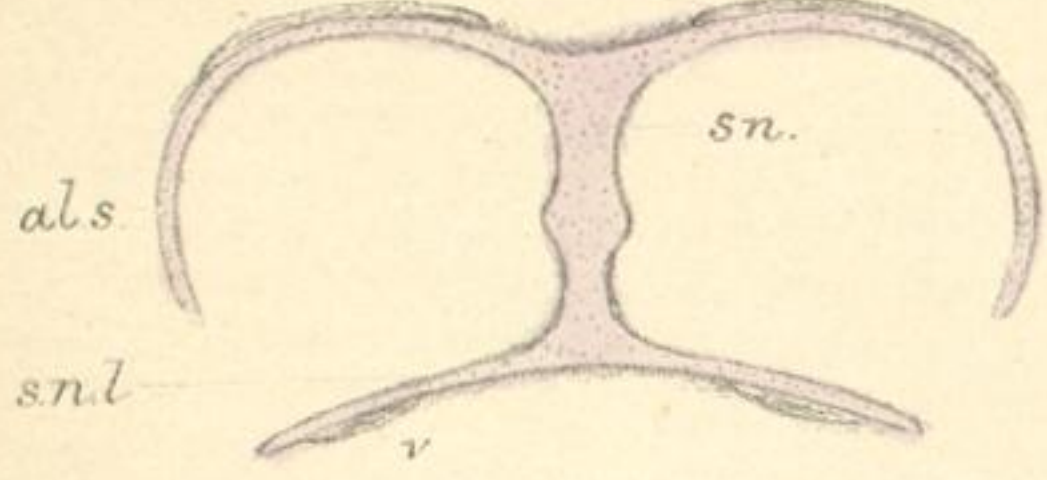
II (x18)



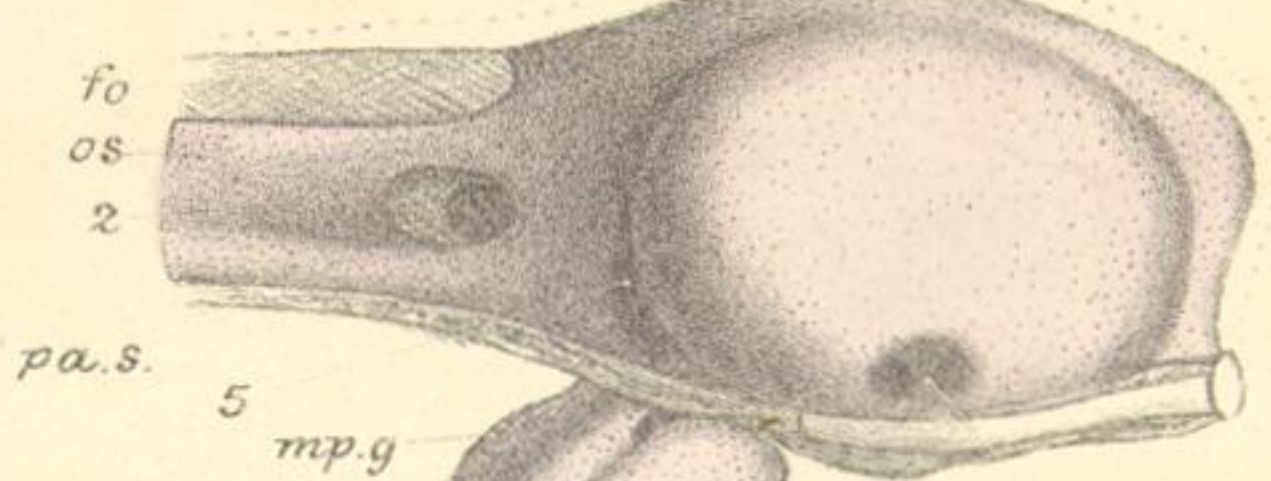X (x18)



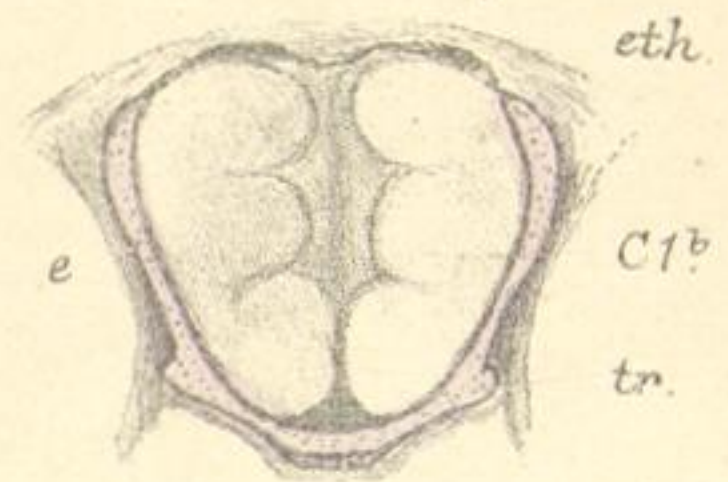
VI (x18)



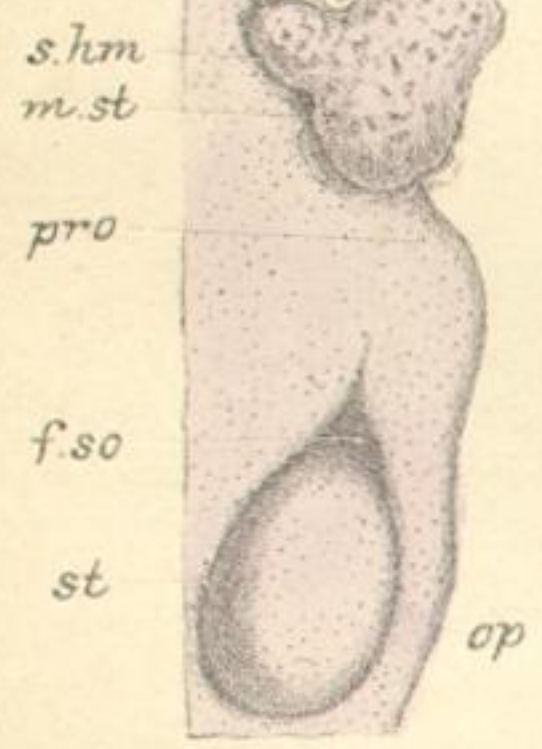
IV (x15)



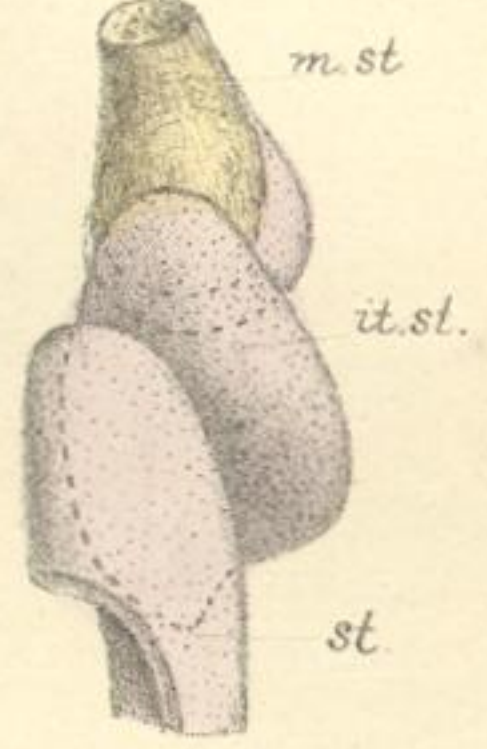
VII (x18)



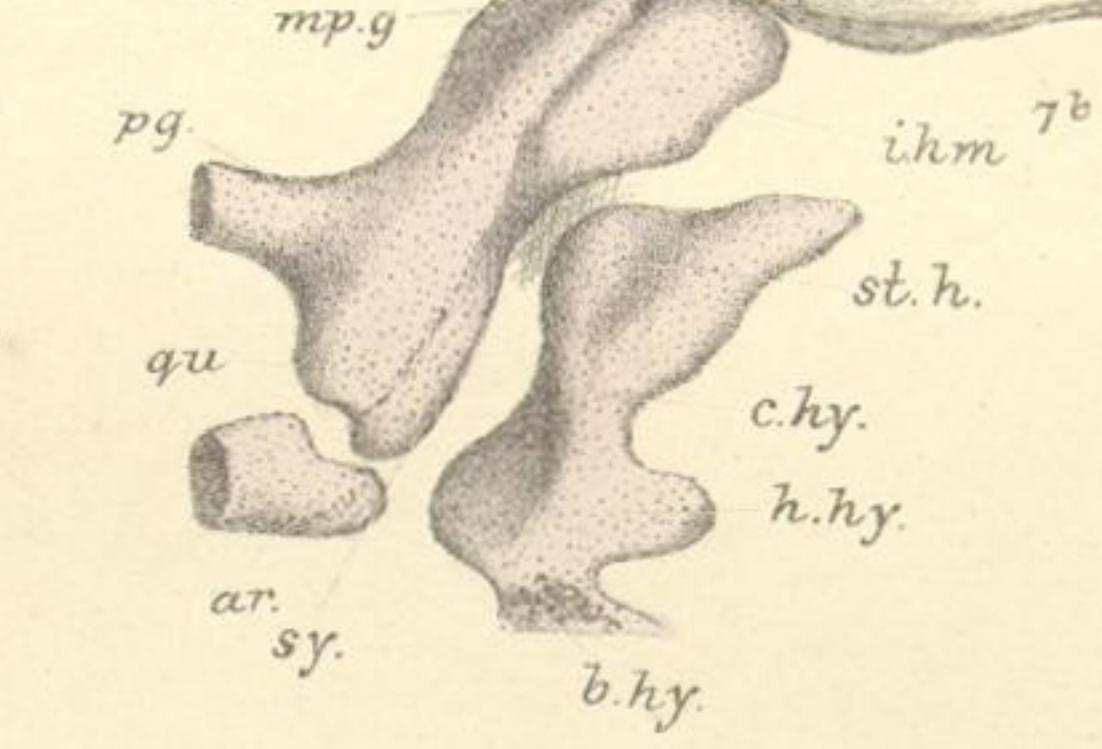
XII (x30)



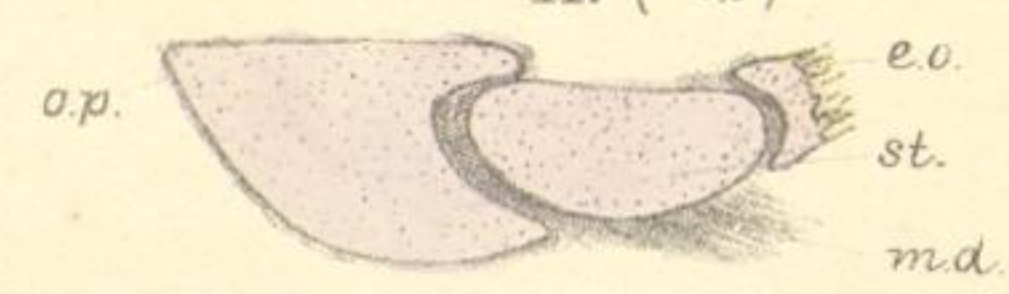
XIV (x30)



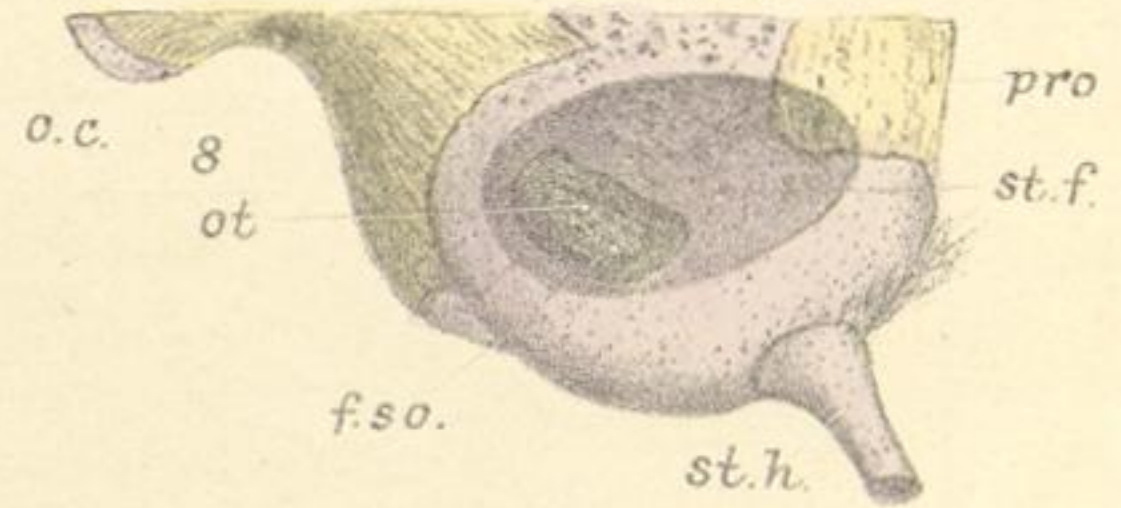XIII (x30)



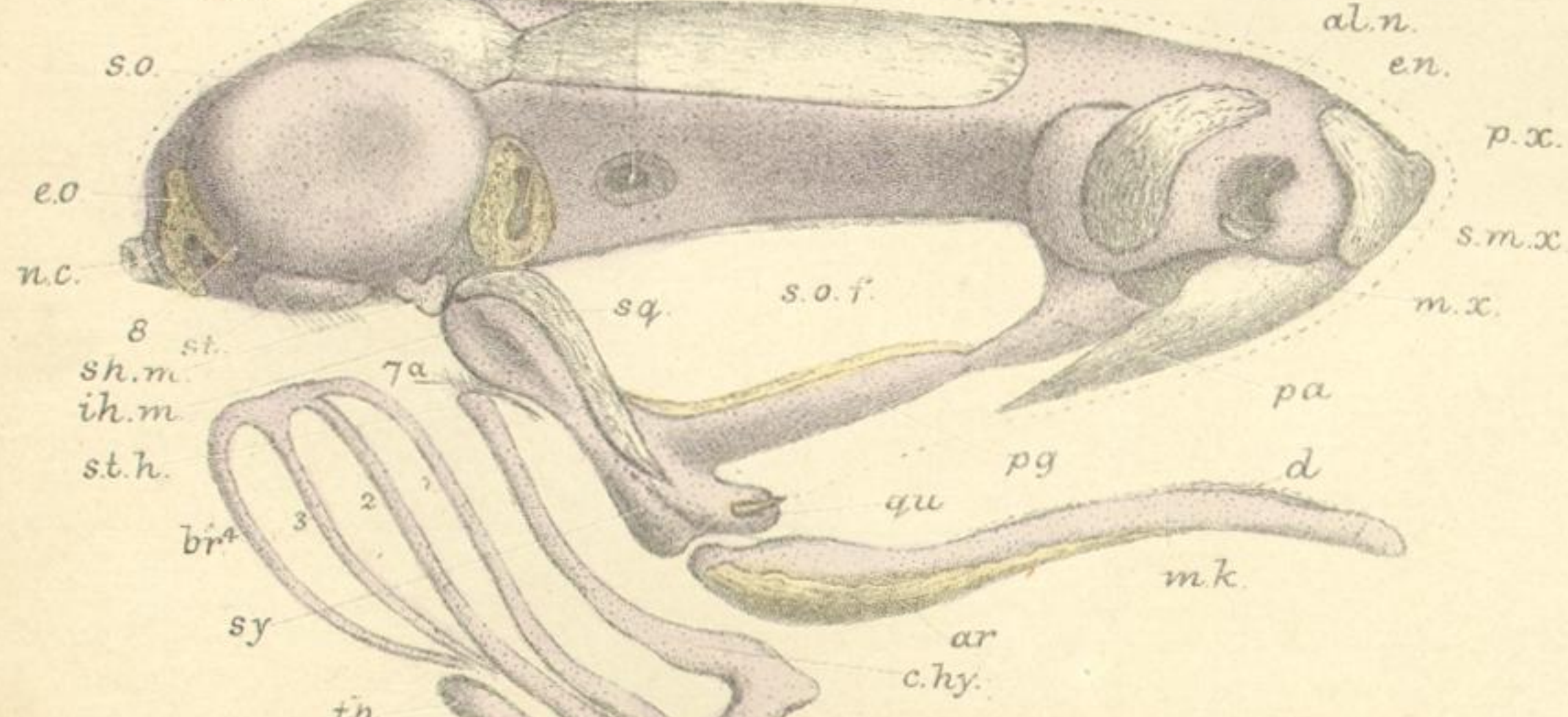
XV (x12)



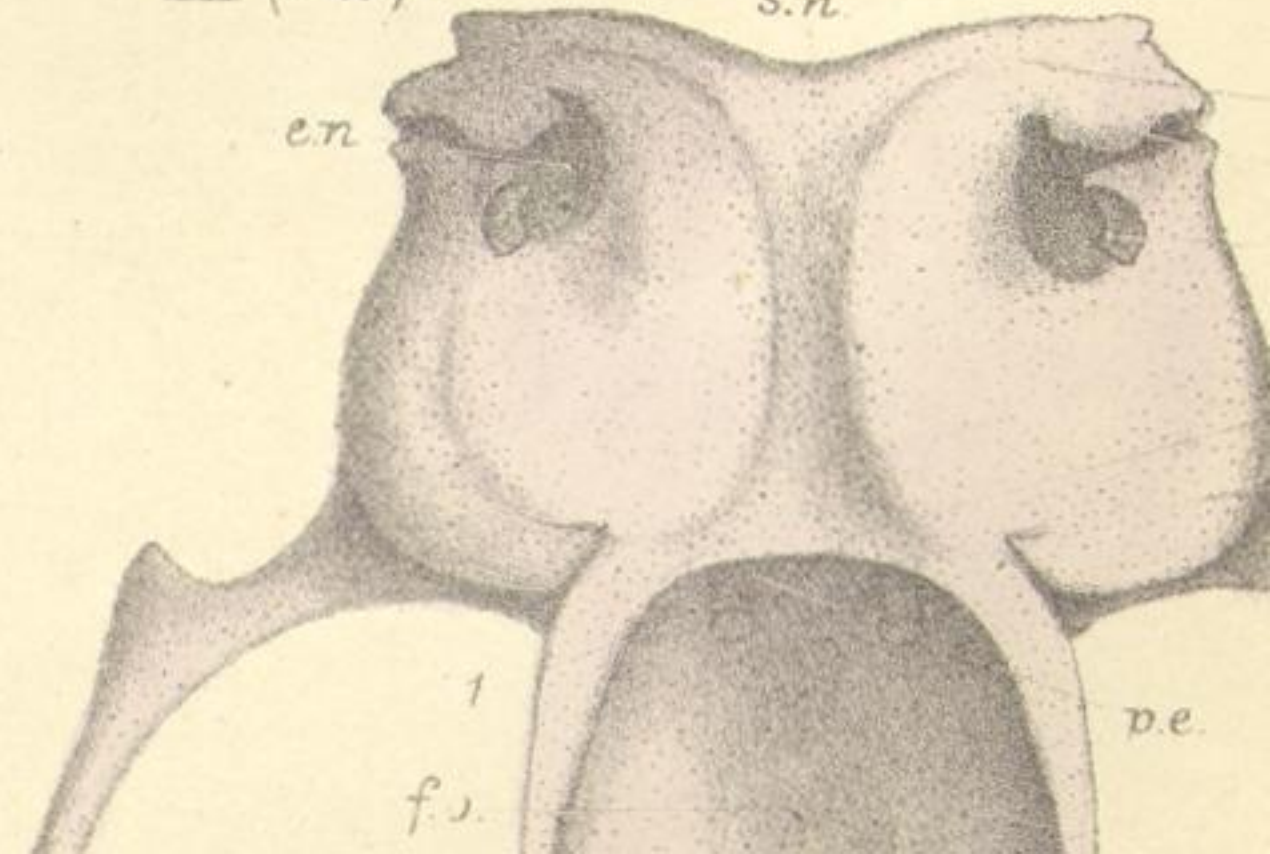
XVI (x12)

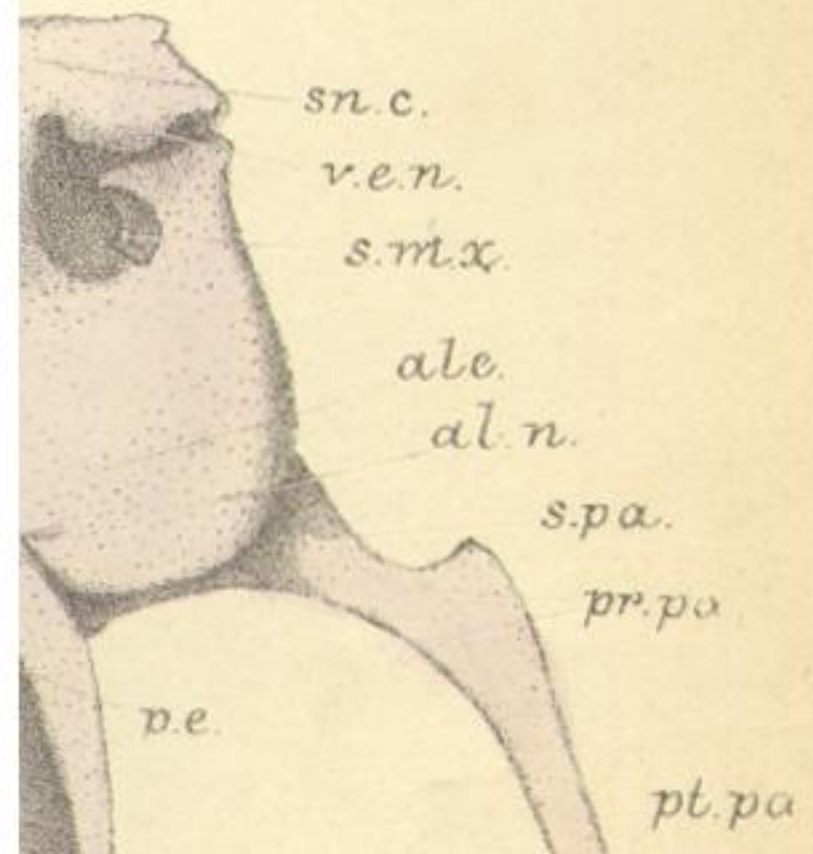
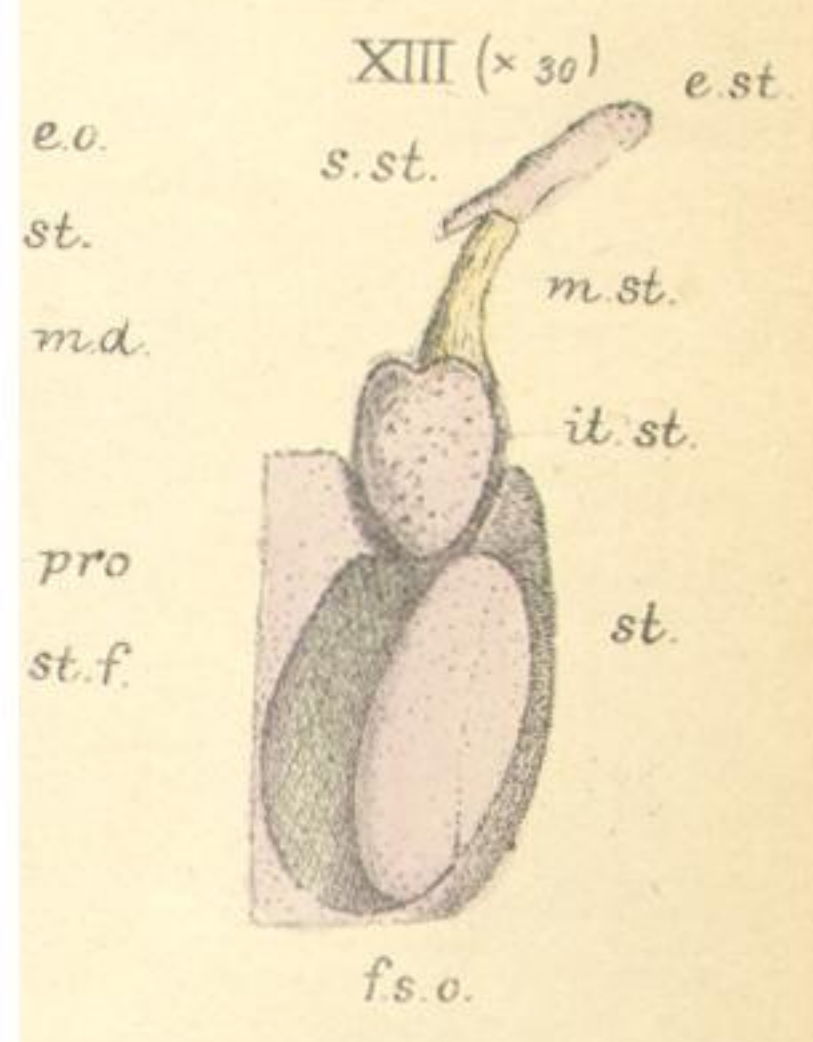
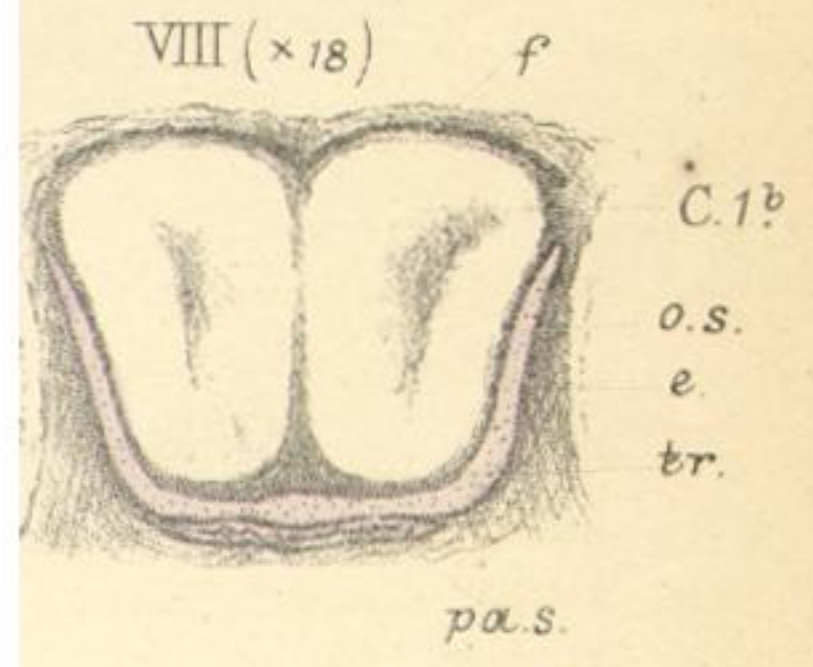
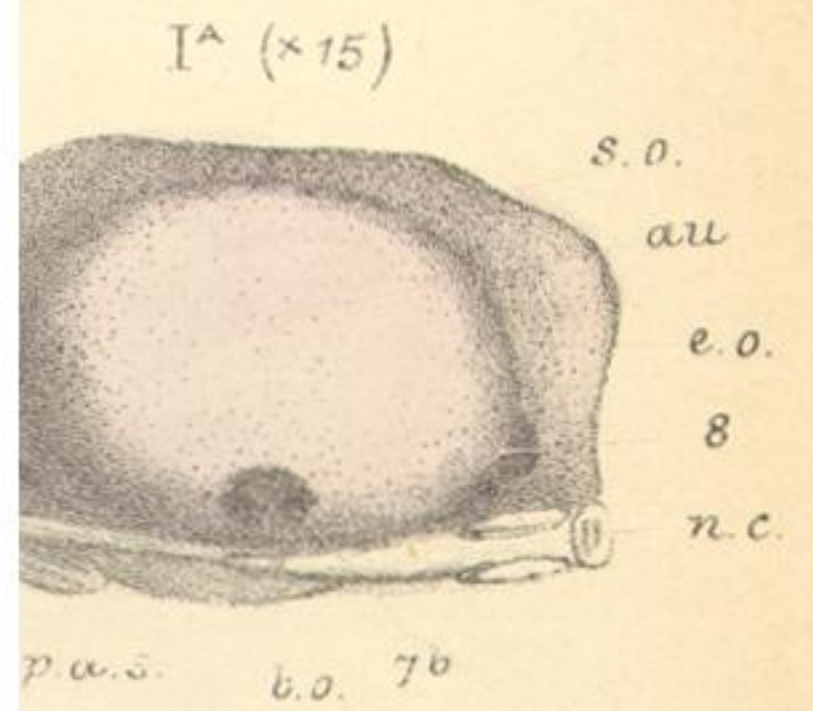
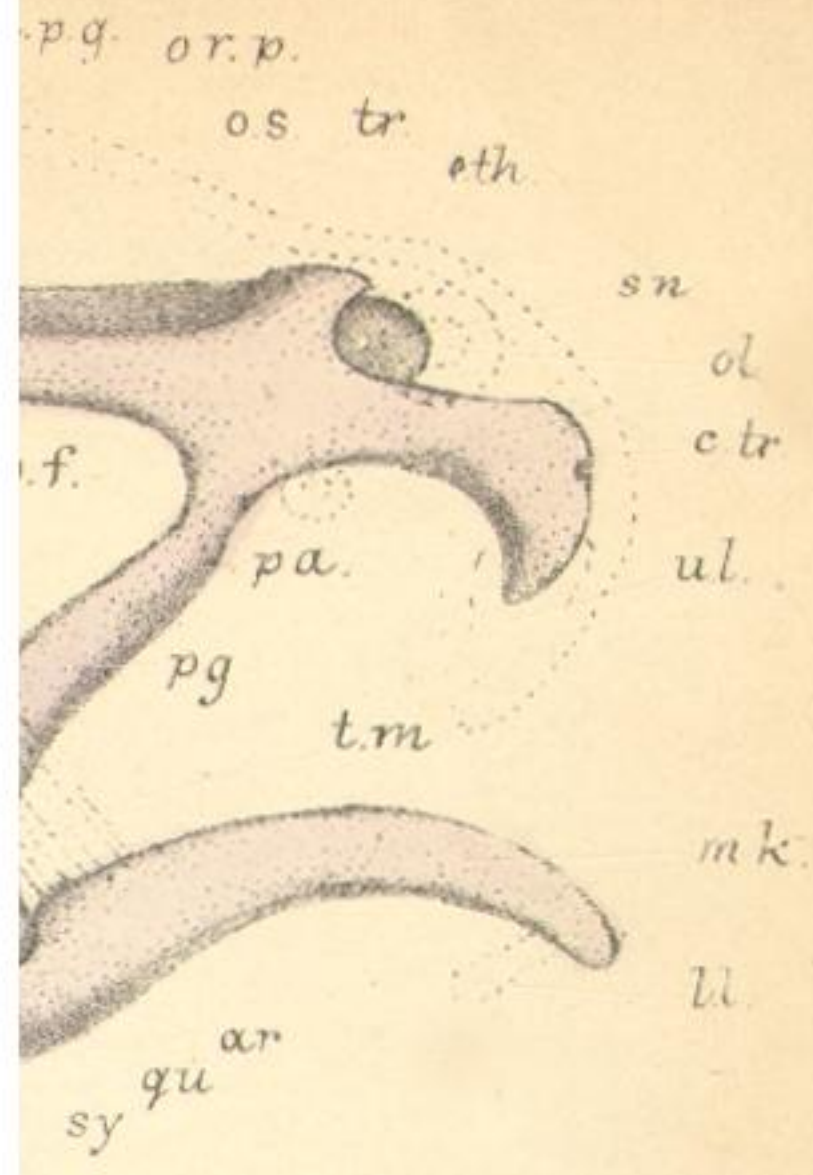


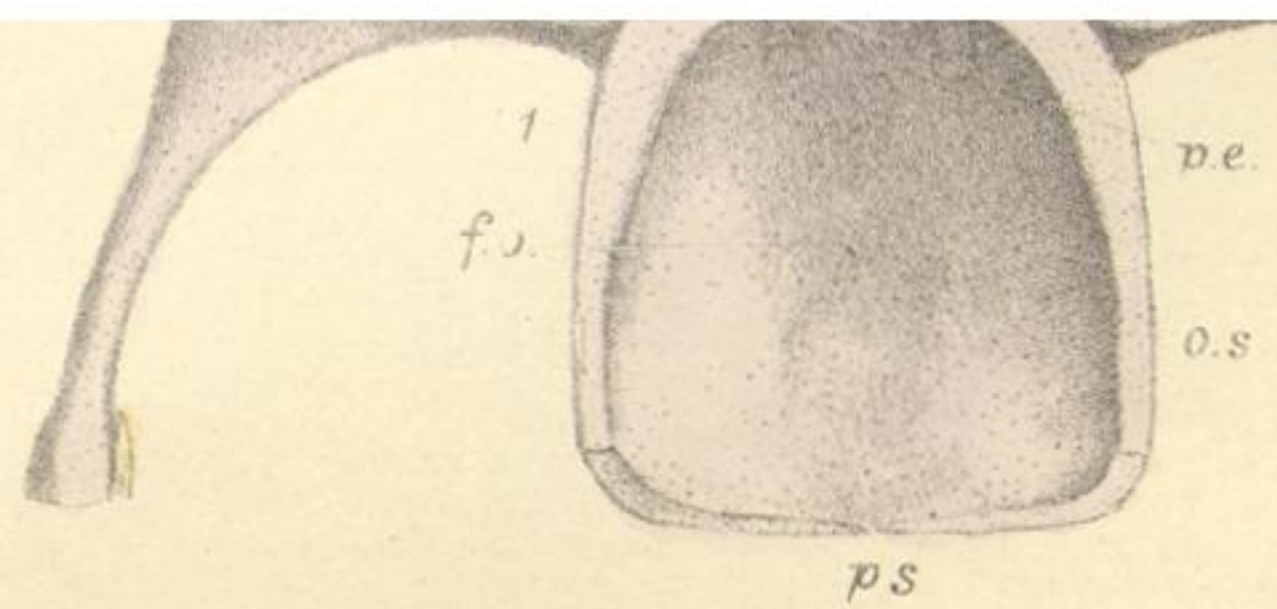
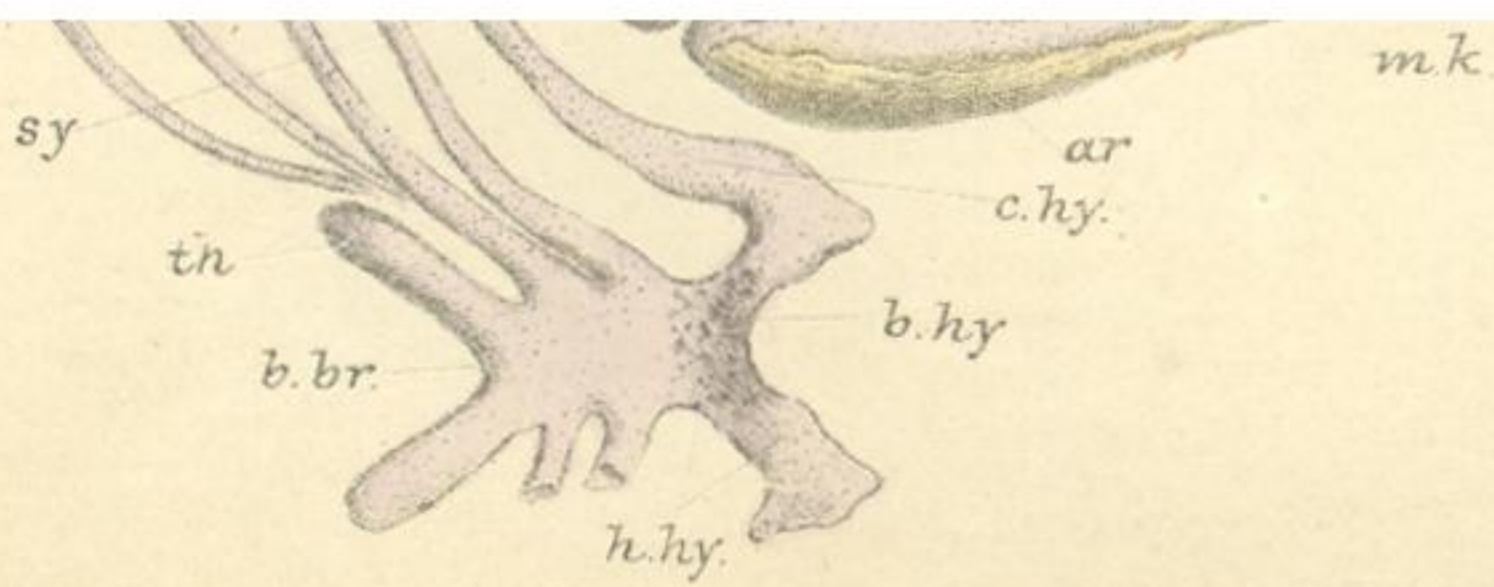
V (x15)



XI (x20)



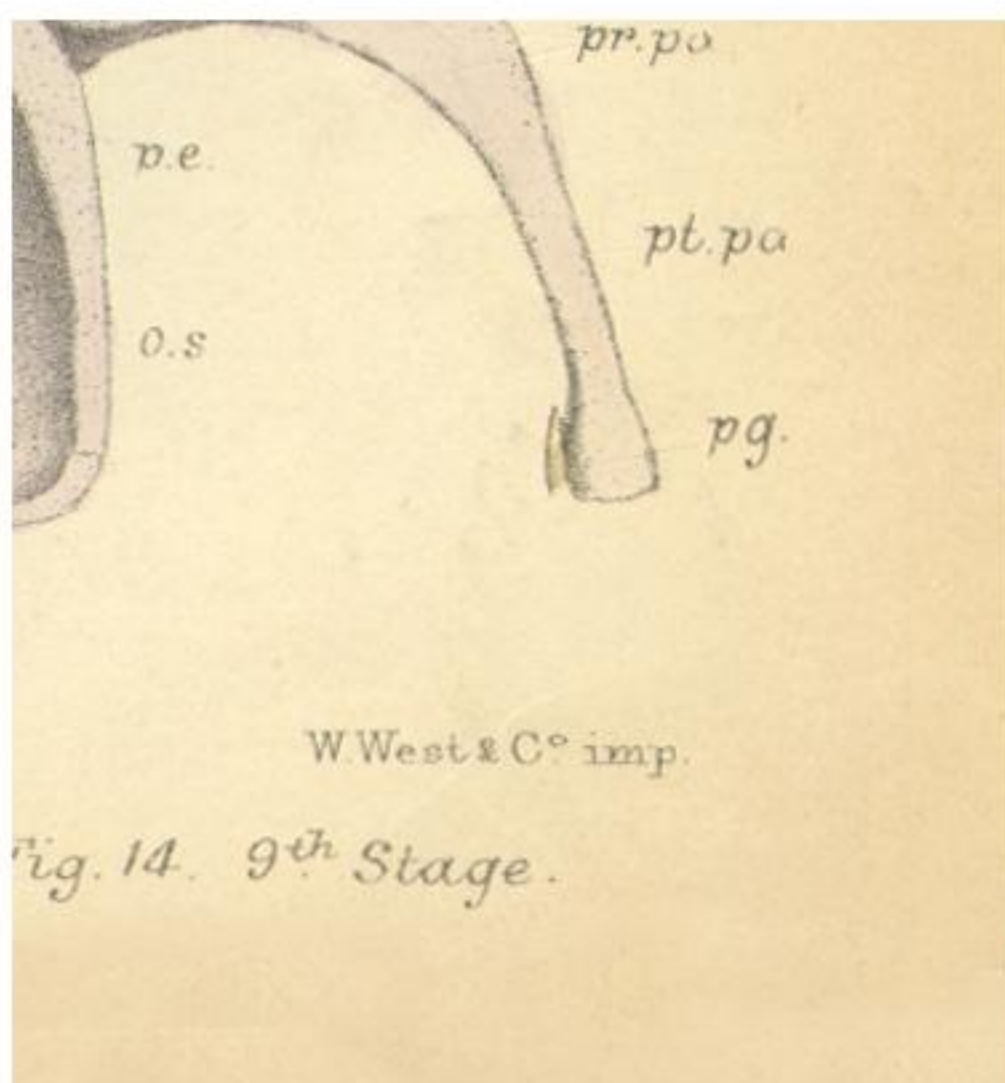




W.K.P. del. ad. nat. Geo. West lith.

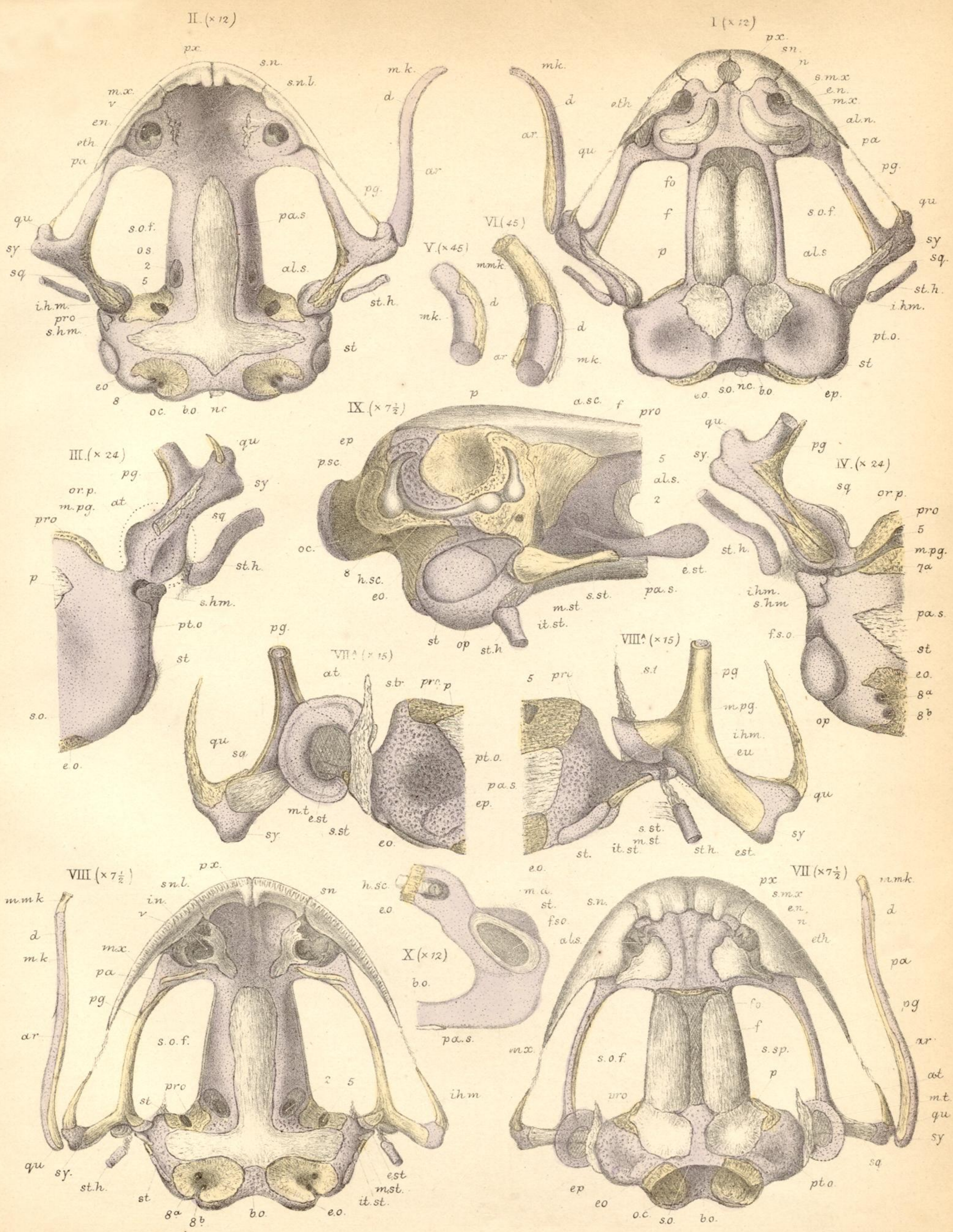
Frog's Skull.

Fig's 1, 1' & 2. 5th Stage. — Fig's 3, 4 6th Stage. — Fig's 5-12. 7th Stage. — Fig. 13. 8th Stage. — Fig. 14. 9th Stage. — Fig's 15, 16. 10th Stage.



W. West & Co. imp.

Fig. 14. 9th Stage.



Frog's Skull.

PLATE VIII.

Seventh Stage (continued).

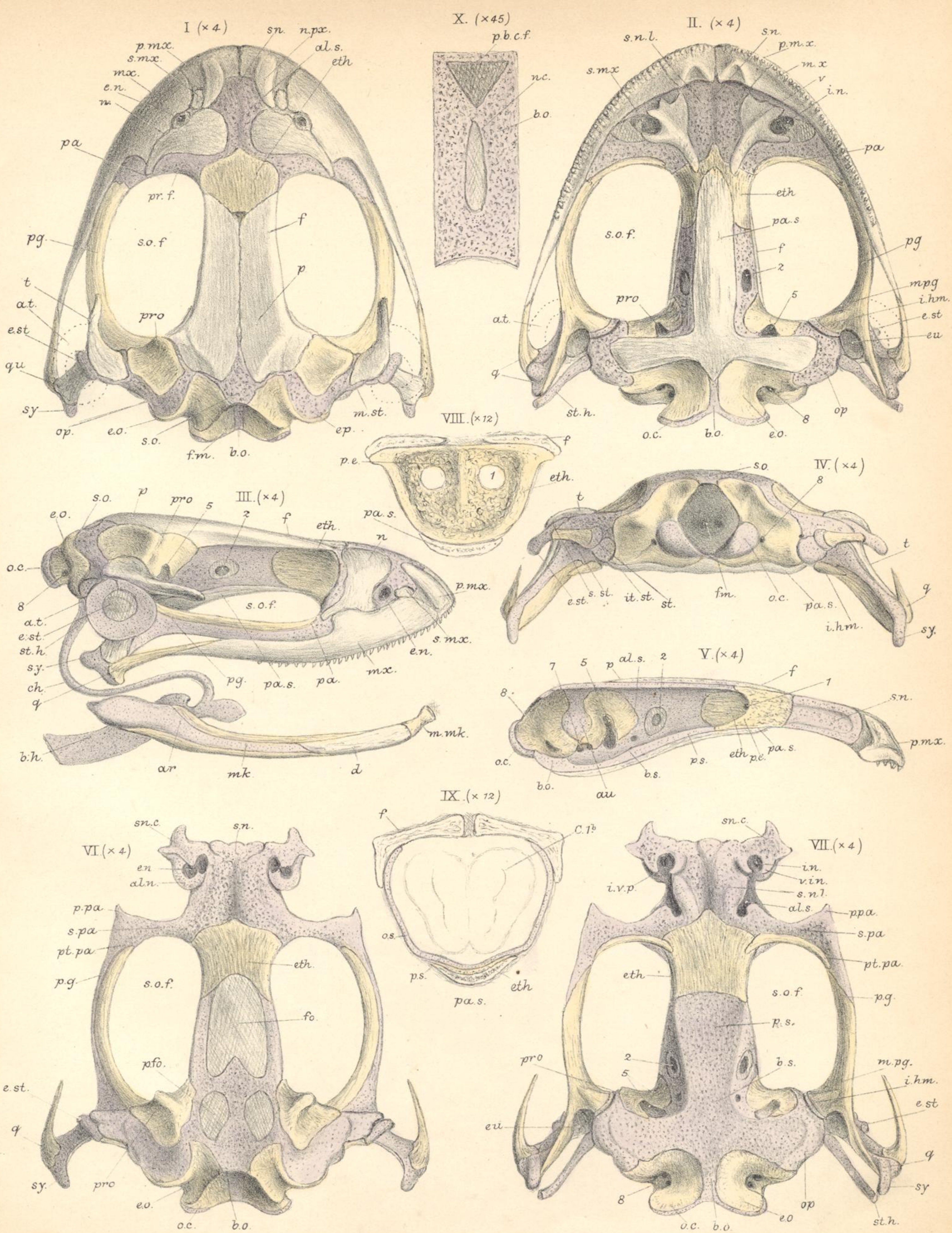
- Fig. 1. Upper view of skull of young Frog with right mandible attached, and hyoid cornua cut through. × 12 diameters.
- Fig. 2. The same, lower view. × 12 diameters.
- Fig. 3. Part of fig. 1, suspensorium and auditory capsule. × 24 diameters.
- Fig. 4. Part of fig. 2, ditto. × 24 diameters.
- Fig. 5. Distal part of MECKEL'S cartilage (*mk.*) with dentary plate (*d.*) still distinct. × 45 diameters.

Eighth Stage.—Frogs of 1st early Summer.

- Fig. 6. Fore part of MECKEL'S cartilage (ossified) with part of "dentary" and "articulare." × 45 diameters.

Ninth Stage.—Frogs of 1st autumn.

- Fig. 7. Upper view of skull of a young Frog examined towards the end of the 1st summer; right mandible removed. × 7 1/2 diameters.
- Fig. 7^a. Part of the same, showing right suspensorium and auditory region. × 15 diameters.
- Fig. 8. The same skull, seen from below. × 7 1/2 diameters.
- Fig. 8^a. Part of fig. 8, showing lower view of suspensorium and auditory region. × 15 diameters.
- Fig. 9. Tenth Stage.—Side view of auditory region of adult Frog with semicircular canals exposed and parts of middle ear displayed. × 7 1/2 diameters.
- Fig. 10. Tenth Stage.—Section showing "fenestra ovalis" and "stapedial plate" from within. × 12 diameters.

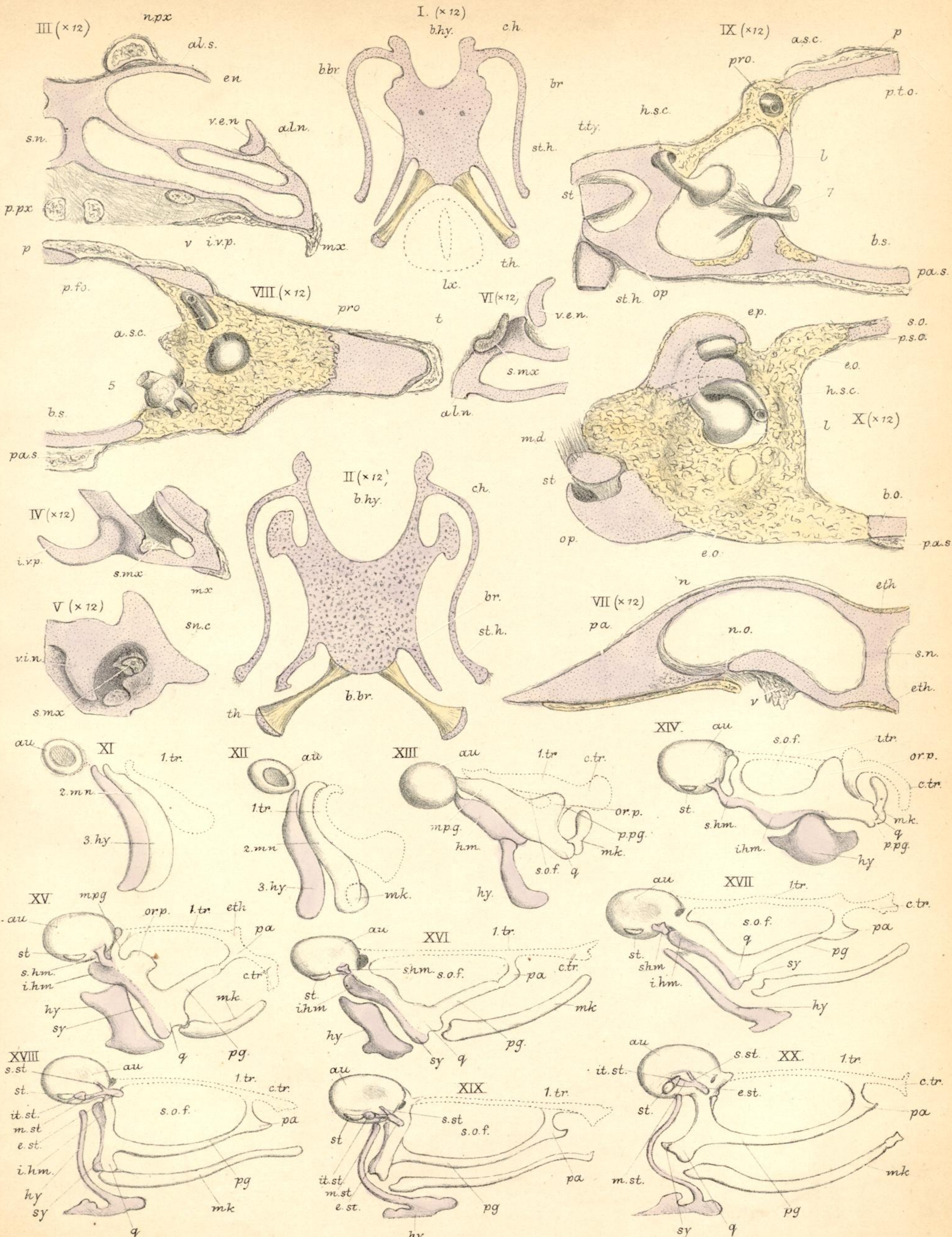


Frog's Skull.

PLATE IX.

Tenth Stage.—Old Frogs.

- Fig. 1. Upper view of skull of adult Frog with all the bones *in situ*. $\times 4$ diameters.
 Fig. 2. Lower view of the same. $\times 4$ diameters.
 Fig. 3. Side view of the same. $\times 4$ diameters.
 Fig. 4. End view of the same. $\times 4$ diameters.
 Fig. 5. Sectional view of the same. $\times 4$ diameters.
 Fig. 6. Upper view of skull of adult Frog from which the parosteal bones have been removed. $\times 4$ diameters.
 Fig. 7. Lower view of the same. $\times 4$ diameters.
 Fig. 8. Section through the "girdle-bone" (ethmoid), seen from behind, and showing the gentle projection answering to the "crista galli" (the end of the mesoethmoid), and the olfactory foramina piercing the ethmoid in the middle of the rhinencephalic fossæ. $\times 12$ diameters.
 Fig. 9. Section through the hemispheres at the anterior border of the orbito-sphenoidal walls. $\times 12$ diameters.
 Fig. 10. Posterior part of floor of the skull in the 7th Stage, seen from above, and showing "posterior basicranial fontanelle" and notochord (*n.c.*). $\times 45$ diameters.



Frog's Skull.

PLATE X.

Various Stages.

- Fig. 1. Hyoid apparatus of young Frog in the 8th Stage. Magnified 12 diameters.
- Fig. 2. Lower view of hyoid cornua and basihyobranchial plate, with ossified thyro-hyals (adult Frog). $\times 4$ diameters.
- Fig. 3. Section (more than half) through fore part of nasal capsule of adult Frog. 12 diameters.
- Fig. 4. Section through right nostril, showing how the nasal canal is lined by the "septo-maxillary," a lobe of which is seen to project downwards, appearing in the inner nares. 12 diameters.
- Fig. 5. Inner nostril of right side, seen from below (part of fig. 7 in Plate IX.); the descending spur of the septo-maxillary is seen enclosed in a fold of membrane. $\times 12$ diameters.
- Fig. 6. Part of fig. 3, further back—posterior face of the same section. $\times 12$ diameters.
- Fig. 7. Section (more than half) through hinder part of nasal capsules of the same. 12 diameters.
- Fig. 8. Section (front view of left side) through the "foramen ovale" and anterior part of auditory capsule. $\times 12$ diameters.
- Fig. 9. Section (front view of right side) through the middle of the auditory capsule, and passing through fenestral fossa and stylo-hyal on the outside, and through the "meatus internus" on the inner. $\times 12$ diameters.
- Fig. 10. Section (front view of right side) through the supraoccipital and epiotic regions, the stapedia plate being severed at its hinder extremity. $\times 12$ diameters.
- Figs. 11-20. Diagrams showing the metamorphoses undergone by the first three facial arches, and their relation to the ear-capsule.